

# Resection of inverted papilloma in nasal cavity with transseptal access and crossing multiple incisions minimizes bleeding and reveals the tumor pedicle

Kazuhiro Omura<sup>a,b,\*</sup>, Kazuhiro Nomura<sup>c</sup>, Satoshi Aoki<sup>b</sup>, Yu Hosokawa<sup>a,b</sup>,  
Yasuhiro Tanaka<sup>b</sup>, Nobuyoshi Otori<sup>a</sup>, Hiromi Kojima<sup>a</sup>

<sup>a</sup>Department of Otorhinolaryngology, The Jikei University School of Medicine, 3-25-8 Nishi-shimbashi, Minato-ku, Tokyo 105-8461, Japan

<sup>b</sup>Department of Otolaryngology, Dokkyo Medical University Saitama Medical Center, Saitama, Japan

<sup>c</sup>Department of Otorhinolaryngology, Tohoku Rosai Hospital, Sendai, Japan



## ARTICLE INFO

### Article history:

Received 20 June 2019

Accepted 17 October 2019

Available online 12 November 2019

### Keywords:

Endoscopic sinus surgery

Endoscopy

Nasal septum

Inverted papilloma

## ABSTRACT

**Objective:** Sinonasal inverted papilloma can be resected endoscopically, but has a risk of recurrence. This risk can be minimized by identifying the pedicle of the tumor and ensuring complete resection. Intraoperative bleeding, particularly from the tumor, decreases endoscopic visualization and contributes to failure to identify the tumor pedicle, and piecemeal resection with dissection of the non-tumoral mucosa makes it impossible to distinguish the tumor pedicle. Previously reported transseptal access with crossing multiple incisions (TACMI) increases mobility of an inverted papilloma within the otherwise restricted nasal cavity. This technique often allows en bloc resection complete with the pedicle and control of bleeding.

**Methods:** We retrospectively reviewed our patients who underwent endoscopic resection of inverted papilloma with or without TACMI and compared the operating times, estimated blood loss, and en bloc resection and recurrence rates between the two groups.

**Results:** Thirty-five patients underwent endoscopic resection of inverted papilloma (Krouse stage 2–4) with ( $n = 23$ ) or without ( $n = 12$ ) TACMI. The operating time was longer in the TACMI group ( $218 \pm 68$  min) than in the non-TACMI group ( $129 \pm 33$  min). Estimated blood loss was less in the TACMI group ( $72 \pm 103$  mL vs.  $120 \pm 136.5$  mL) but this finding was not significant. En bloc resection was achieved in 19 patients (83%) in the TACMI group but not in any patient in the non-TACMI group. There were no recurrences in the TACMI group. Multivariate analysis showed significant relationships between estimated amount of blood loss and operating time according to Krouse stage and whether or not TACMI was performed.

**Conclusions:** Endoscopic resection of inverted papilloma with TACMI may achieve better treatment results with less blood loss.

© 2019 Oto-Rhino-Laryngological Society of Japan Inc. Published by Elsevier B.V. All rights reserved.

\* Corresponding author at: Department of Otorhinolaryngology, The Jikei University School of Medicine, 3-25-8 Nishi-shimbashi, Minato-ku, Tokyo 105-8461, Japan.

E-mail address: [kazuhiro.omura@jikei.ac.jp](mailto:kazuhiro.omura@jikei.ac.jp) (K. Omura).

## 1. Introduction

Inverted papilloma (IP) is a common benign epithelial tumor of the sinonasal tract and accounts for 0.5–4% of all nasal tumors [1–3]. IP is a benign but locally aggressive

neoplasm arising from the sinonasal mucosa [2,3]. The recurrence rate is reported to be 12–20%, and malignant transformation occurs in 3–7% of cases [2].

Complete removal of IP is the best way of preventing recurrence. However, en bloc endoscopic resection is not always possible because of the tumor bulk, which obscures the surgical field in the narrow nasal cavity [4]. To minimize the possibility of tumor dissemination and to obtain a well-preserved sample, a “modular” technique is preferred to a simple “piecemeal” method. With modular resection, the tumor is dissected with oriented blocks, such as the endonasal portion, the tumor pedicle area, and the underlying bone.

Intraoperative bleeding is another problem with IP resection because bleeding from the tumor itself is unavoidable with piecemeal or modular dissection. The estimated blood loss during endoscopic and open surgery has been reported to be similar [5]. Excessive bleeding obscures the operative field, which increases the risk of intraoperative complications and makes it difficult to distinguish between tumor tissue and normal mucosa. Overlooking tumor tissue under poor vision leads to recurrence. Therefore, incision of an IP during surgery should be kept to a minimum to allow a good operative view.

We recently published a description of our transseptal access with crossing multiple incisions (TACMI) technique, which allows transposition of the tumor without sacrificing the nasal structure [6]. Using this method, the pedicle of the tumor becomes accessible and it is possible to perform an en bloc resection without incising the tumor. Theoretically, en bloc resection of IP reduces bleeding from the tumor and contributes to a good operative field while minimizing blood loss. To assess the value of TACMI, we retrospectively analyzed our data on estimated blood loss, operating time, successful en bloc resection, and recurrence rate for endoscopic resection with and without TACMI.

## 2. Materials and methods

In this study, we evaluated patients with IP who underwent endoscopic endonasal resection at Dokkyo University Saitama Medical Center, Japan, between April 2012 and March 2018 and at The Jikei University Hospital, Japan, between August 2013 and March 2018. The patients with IP who underwent surgery between April 2012 and March 2017 at Dokkyo University Saitama Medical Center were selected as the non-TACMI group and the other patients as the TACMI group. The IPs were resected in the TACMI group by one operator (the surgeon who invented the procedure) and in the non-TACMI group by another operator who had adequate experience in endoscopic sinus surgery.

The surgery was performed under general anesthesia in all cases. En bloc resection was performed whenever possible. After recognizing that en bloc resection was not feasible for most IP resections, we changed our strategy to include TACMI at the start of the surgery. TACMI has been extensively described in a previous report [6]. In brief, after submucosal injections of 1% lidocaine and 1:200,000 adrenaline, an incision is made in the mucoperichondrium on the contralat-

eral side (Video 1). A septoplasty is performed to remove the excess bone and cartilage [7], and anterior, superior, and inferior incision lines are made (Fig. 1). These incisions provide a wide portal for displacement of the tumor; however, the risk of subsequent perforation is minimal because the incisions on the two sides do not cross each other (Fig. 1(C)). The tumor can then be effectively transposed into the central compartment of the nose and across the midline to safely expose the pedicle of the tumor. After successful resection of the tumor, the septum is then reconstructed with a single suture placed along the anterior vertical incisions and two sutures along the inferior and superior horizontal incisions bilaterally.

We retrospectively reviewed our patients who underwent endoscopic resection of IP with and without TACMI and compared the demographic data, operating time, estimated blood loss, recurrence rate, and whether en bloc resection was possible or not between the two groups. The study was approved by the Institutional Review Board of Dokkyo Medical University Saitama Medical Center (registration number 1736).

### 2.1. Statistical analysis

Data are given as average  $\pm$  SD. The Mann–Whitney *U* test was used to test for differences in continuous variables (operating time and estimated blood loss) between the two groups. The Fisher’s exact probability test was used to compare the en bloc resection and recurrence rates between the two groups. A multivariate linear regression model was used to analyze the influence of the Krouse stage and whether or not TACMI was performed on the operating time and estimated the amount of blood loss. The following predictor variables were transformed into numerical values: non-TACMI = 0, TACMI = 1; Krouse stage 1 = 1, stage 2 = 2, stage 3 = 3, stage 4 = 4.

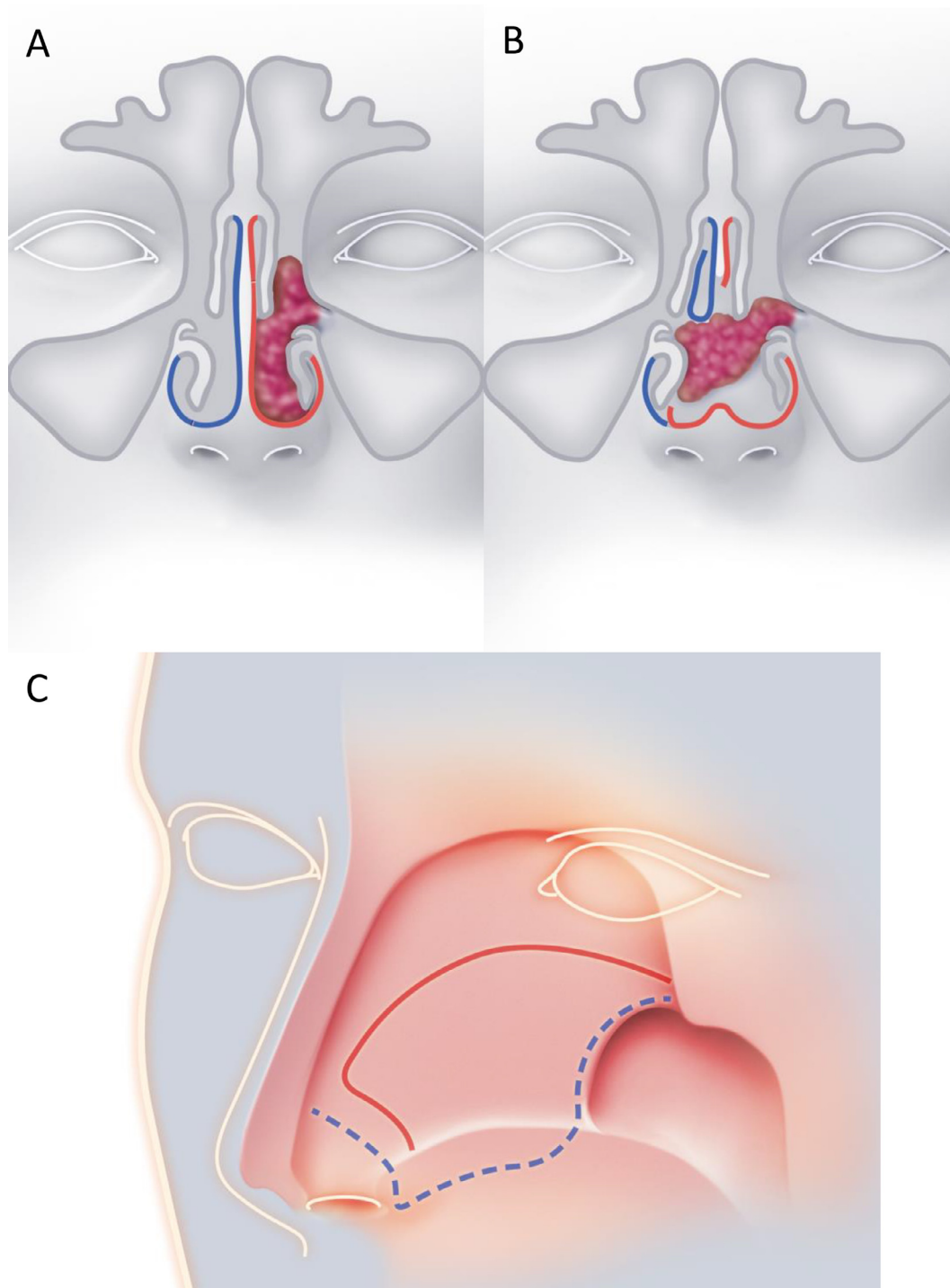
Bonferroni’s correction was made for all comparisons. A *p*-value <0.05 was considered statistically significant. All statistical analyses were performed using Stata/MP version 14.0 software (StataCorp LP, College Station, TX, USA).

## 3. Results

The study included 35 patients, all of whom underwent endoscopic surgery. The patient demographics and Krouse classification data are summarized in Table 1 [8]. The Krouse stage was significantly worse in the TACMI group than in the non-TAMCI group. There were no procedure-related complications. All patients were followed up by endoscopic examination of the nasal cavity for at least 16 months postoperatively.

Performing en bloc resection with TACMI took on average 80 min longer than standard piecemeal or modular resection (Table 2). The increased operating time was accounted for not only by the time required to perform TACMI but also by that needed to dissect the tumor pedicle with a clear endoscopic view to avoid damaging the tumor and prevent excessive bleeding.

The estimated blood loss was less in the TACMI group than in the non-TACMI group but the difference was not



**Fig. 1.** Schematic representation of TACMI. (A) The pedicle of the tumor arises from the left maxillary sinus. The mucosa of the nasal septum, nasal floor, and inferior meatus are highlighted with color (right side, blue; left side, red). (B) The incised mucosa is displaced to the right side so that the tumor can be moved to the contralateral side. (C) Incisions on both septal mucoperiosteum are shown (right side, blue line; left side, red line). TACMI, transeptal access and crossing multiple incisions.

statistically significant (Table 2). Recurrence was documented in three patients (25%) in the non-TACMI group but not in any patients in the TACMI group (Table 2). The change in operative strategy from traditional piecemeal or modular resection to en bloc resection with TACMI might have influenced the likelihood of recurrence.

The results of the multivariable regression models showed that patients with TACMI procedures had significantly longer operative time and significantly less estimated blood loss. Severe krouse stage showed that the operation time was significantly longer and the amount of estimated blood loss increased (Tables 3 and 4).

**Table 1**

Comparison of patient demographics and Krouse classification between the two study groups.

	Non-TACMI group	TACMI group	<i>p</i> value
Sex			
Male	6	17	
Female	6	6	
Mean age, years (range)	58.1 (80–44)	61.8 (86–43)	
Krouse classification			0.003
1	0	0	
2	8	4	
3	4	16	
4	0	3	

TACMI, transeptal access and crossing multiple incisions.

**Table 2**

Comparison of operating time and outcomes between the two study groups.

	Non-TACMI group	TACMI group	<i>p</i> value
Operation time (min) (mean (min–max))	129 (65–185)	218 (75–402)	
Estimated blood loss (mL) (mean (min–max))	120 (5–450)	72(10–440)	
En bloc resection ( <i>n</i> , (%))	0	19 (83%)	< 0.001*
Recurrence ( <i>n</i> , (%))	3 (25%)	0	0.170

TACMI, transeptal access and crossing multiple incisions.

**Table 3**

Multivariate analysis for operation time (minutes).

	Coef.	<i>p</i> value	95% confidence interval	
TACMI	60.3	0.010	15.3	105.4
Krouse classification	47.0	0.011	11.5	82.5
_cons	19.1	0.665	–69.7	107.8

TACMI, transeptal access and crossing multiple incisions.

**Table 4**

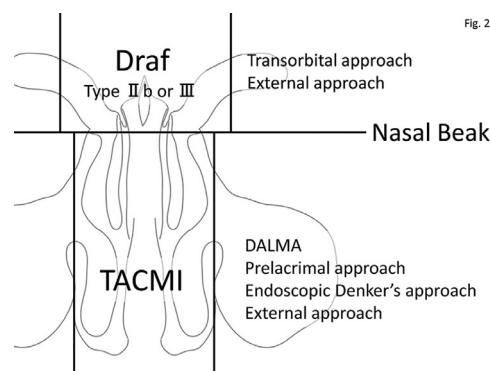
Multivariate analysis for estimated blood loss (mL).

	Coef.	<i>p</i> value	95% confidence interval	
TACMI	–103.3	0.024	–192.3	–14.4
Krouse classification	88.4	0.015	18.3	158.5
_cons	–85.8	0.326	–261.1	89.4

TACMI, transeptal access and crossing multiple incisions.

#### 4. Discussion

A tumor that is touching the septum and a tumor pedicle located within nasal cavity are the surgical indications for TACMI. The approach should be chosen according to the location of the tumor pedicle. For example, if the pedicle is within the maxillary sinus, a prelacrima approach, a direct endoscopic approach to the anterior and lateral part of the maxillary sinus, or an endoscopic Denker's approach should be used [9–11]. A Draf type IIb or III procedure should be used if the tumor pedicle is located within the medial half of the frontal sinus and an external or transorbital approach if it is within the lateral half of the frontal sinus (Fig. 2). A com-



**Fig. 2.** Schematic representation of the indication of TACMI depends on the pedicle of the tumor.

bination of TACMI with another approach depending on the location of the tumor increases the likelihood of successful en bloc resection of IP and reduces the total amount of intraoperative blood loss. By performing TACMI, the pedicle of the tumor can be easily identified because the visual field is not obscured by bleeding from the tumor and the transition between the tumor and the normal mucosa is not disturbed before resection of the tumor. The disadvantage of this technique is that it takes additional time to prepare the access for TACMI, to dissect the surrounding structures while preserving the intact tumor, and to suture the incisions required for TACMI.

The standard procedure for IP resection nowadays is endoscopic piecemeal or modular resection using a microdebrider [2,4,12]. In the mid-1990s, which was the era of transition from an open approach to an endoscopic approach, IP resection with an open approach was found to have a lower recurrence rate and was preferred because of the predilection of this tumor for local recurrence and multicentricity, as well as the possibility of malignancy [13]. With improved endoscopic resolution, newer surgical instruments such as the curved diamond bur, and modification of surgical technique, surgeons consider that the outcome of endoscopic piecemeal or modular resection is better than that of en bloc resection with an open approach [2,4,12]. En bloc resection is preferable when possible. In a series of primary and revision cases, en bloc resections were performed when the size and extent of the tumor permitted [2]. Although endoscopic piecemeal resection of a malignant sinonasal tumor has not been found to have worse outcomes in terms of the local recurrence rate or patient survival when compared with en bloc resection with open approach [14], dissemination of tumor tissue may occur with piecemeal resection. To decrease the risk of recurrence, en bloc resection is preferable if possible. Unfortunately, en bloc resection of IP is rarely possible because of the limited space in the sinonasal cavity. TACMI was devised to make a corridor for removal of the tumor and a means of access for the surgical instruments [6].

TACMI prevents bleeding from the tumor itself and decreases intraoperative blood loss. IP is a relatively hypervascular tumor, and bleeding during surgery not only contributes to poor visualization but also increases the likelihood of complications associated with blood loss [15]. In



our study, the estimated blood loss was significantly less in the TACMI group than in the non-TACMI group and Krouse staging significantly related to the estimated blood loss.

En bloc resection was performed in 19 of the 23 patients who underwent TACMI in our study. In the remaining four patients in whom piecemeal resection was performed, the tumor pedicle was at the floor of the maxillary sinus in three cases and the tumor showed broad attachment between the maxillary sinus and the anterior and posterior ethmoids in one case. An approach through the canine fossa is needed to perform en bloc resection of an IP that is attached to the maxillary sinus. En bloc resection of a tumor with a broad pedicle is not likely to be possible using the technique available today. Piecemeal or modular resection would be the best treatment option for such tumors.

One of the limitations of TACMI is that it takes nearly an hour to prepare a corridor and to suture the mucosal incisions (Table 2). However, we predict that this extra time will be shortened as the surgical skills required to perform the procedure become more refined. The longer operating time in the TACMI group was the result of preparing and closing the TACMI site and handling of the tumor en bloc, which requires more time than simple piecemeal resection. The balance between operating time and blood loss should be considered on a case-by-case basis. The other concern is the risk of a septal perforation. A pinhole-sized septal perforation occurred in one patient in our study but fortunately did not cause any symptoms. The risk of septal perforation seems low, but the patient should be informed of this possibility before surgery.

The tumor recurred in three of 12 patients in the non-TACMI group and in none in the TACMI group. However, given that our sample size was small and the decision to perform TACMI in all cases was made relatively late in the study period, this finding cannot be interpreted as meaning that TACMI reduces the IP recurrence rate. Studies in large numbers of patients with longer follow-up durations are needed to determine the effect of en bloc resection with TACMI on the risk of recurrence of IP.

## 5. Conclusion

Resection of IP with TACMI has merits in terms of good visualization, preservation of the sample, less blood loss, and possibly a lower recurrence rate. An IP arising from the maxillary floor cannot be resected en bloc using TACMI alone and a tumor with a broad pedicle is not a candidate for en bloc resection. The TACMI procedure itself and the need to handle the tumor during en bloc resection adds to the operating time. The TACMI technique is a convenient and effective way of resecting an IP with good visualization of the operative field. In our experience, the outcomes have been favorable without any complications. However, further studies in a larger numbers of patients and with a longer follow-up duration are needed to confirm the effectiveness of the TACMI procedure and en bloc resection of IP.

## Financial disclosure

None.

## Declaration of Competing Interest

None.

## Acknowledgments

None.

## Supplementary materials

Supplementary material associated with this article can be found, in the online version, at doi:10.1016/j.anl.2019.10.006.

## References

- [1] Govindaraj S, Wang H. Does human papilloma virus play a role in sinonasal inverted papilloma? *Curr Opin Otolaryngol Head Neck Surg* 2014;22:47–51.
- [2] Adriaensen GF, Lim KH, Geogalas C, et al. Challenges in the management of inverted papilloma: a review of 72 revision cases. *Laryngoscope* 2016;126:322–8.
- [3] Zhao RW, Guo ZQ, Zhang RX. Human papillomavirus infection and the malignant transformation of sinonasal inverted papilloma: a meta-analysis. *J Clin Virol* 2016;79:36–43.
- [4] Lombardi D, Tomenzoli D, Buttà L, et al. Limitations and complications of endoscopic surgery for treatment for sinonasal inverted papilloma: a reassessment after 212 cases. *Head Neck* 2011;33:1154–61.
- [5] Sautter NB, Cannady SB, Citardi MJ, et al. Comparison of open versus endoscopic resection of inverted papilloma. *Am J Rhinol* 2007;21:320–3.
- [6] Omura K, Asaka D, Nayak JV, Tanaka Y. Transseptal access with crossing multiple incisions for improved pedicle control and septum preservation: “How I do it”. *Am J Rhinol Allergy* 2017;31:139–41.
- [7] Asaka D, Yoshikawa M, Okushi T, et al. Nasal splinting using silicone plates without gauze packing following septoplasty combined with inferior turbinate surgery. *Auris Nasus Larynx* 2012;39:53–8.
- [8] Krouse JH. Endoscopic treatment of inverted papilloma: safety and efficacy. *Am J Otolaryngol* 2001;22:87–99.
- [9] Zhou B, Han DM, Cui SJ, Huang Q, Wang CS. Intranasal endoscopic prelacrima recess approach to maxillary sinus. *Chin Med J* 2013;126(7):1276–80.
- [10] Omura K, Nomura K, Aoki S, Otori N, Tanaka Y. Direct approach to the anterior and lateral part of the maxillary sinus with an endoscope. *Auris Nasus Larynx* 2019;46:871–5.
- [11] Lee JT, Suh JD, Carrau RL, Chu MW, Chiu AG. Endoscopic Denker’s approach for resection of lesions involving the anteroinferior maxillary sinus and infratemporal fossa. *Laryngoscope* 2017;127(3):556–60.
- [12] Healy DY Jr, Chhabra N, Metson R, et al. Surgical risk factors for recurrence of inverted papilloma. *Laryngoscope* 2016;126:796–801.
- [13] Lawson W, Ho BT, Shaari CM, Biller HF. Inverted papilloma: a report of 112 cases. *Laryngoscope* 1995;105:282–8.
- [14] Villaret AB, Yakirevitch A, Bizzoni A, et al. Endoscopic transnasal craniectomy in the management of selected sinonasal malignancies. *Am J Rhinol Allergy* 2010;24:60–5.
- [15] Kostrzewa JP, Sunde J, Riley KO, Woodworth BA. Radiofrequency coblation decreases blood loss during endoscopic sinonasal and skull base tumor removal. *ORL J Otorhinolaryngol Relat Spec* 2010;72:38–43.