

Title

Usefulness of stereotactic radiotherapy using the CyberKnife for patients with inoperable locoregional recurrences of differentiated thyroid cancer

Takayuki Ishigaki, MD, Takashi Uruno, MD, Tomoaki Tanaka, MD, Yuna Ogimi, MD, Chie Masaki, MD, Junko Akaishi, MD, Kiyomi Y. Hames, MD, Tomonori Yabuta, MD, Akifumi Suzuki, MD, Chisato Tomoda, MD, Kenichi Matsuzu, MD, Keiko Ohkuwa, MD, Wataru Kitagawa, MD, Mitsuji Nagahama, MD, Kiminori Sugino, MD, Koichi Ito, MD

Department of Surgery, Ito Hospital, 4-3-6 Jingumae, Shibuya-ku, Tokyo, Japan 150-8308

Abbreviated Title

Stereotactic radiotherapy for differentiated thyroid cancer

KEY WORDS:

Stereotactic radiotherapy, CyberKnife, Differentiated thyroid cancer, Locoregional recurrence

Word count: 2014 words

Address correspondence to:

Takayuki Ishigaki, MD

Department of Surgery, Ito Hospital, 4-3-6 Jingumae, Shibuya-ku, Tokyo 150-8308,

Japan

Tel: +81-3-3402-7411; Fax: +81-3-3402-7439

Email: tippdwr@jikei.ac.jp

Abstract

Background Surgical resection is the preferred treatment for locoregional recurrence of differentiated thyroid cancer (DTC). However, some recurrences are unresectable because of their aggressive invasion or severe adhesions. On the other hand, stereotactic radiotherapy (SRT) enables high-dose irradiation to target lesions, and its usefulness for various cancers has been reported. The objective of the present study was to investigate the feasibility and efficacy of SRT as salvage treatment for locoregional recurrence of DTC.

Methods Between August 2011 and December 2017, 52 locoregional recurrent lesions in 31 patients with recurrent DTC were treated by SRT using the CyberKnife system. Information on the adverse events associated with SRT was retrospectively collected from the patients' medical records. Of the 52 lesions, 33 could be evaluated for therapeutic effectiveness by follow-up CT, and response was assessed using the RECIST criteria.

Results Twenty-five patients had papillary carcinoma, five had follicular carcinoma, and one had poorly differentiated cancer. SRT was delivered in one to 20 fractions, and the median dose was 30 Gy (range 15-60 Gy). Adverse events were not frequent, but one patient developed bilateral vocal cord palsy that required emergent tracheostomy.

The median follow-up period of 33 lesions was 14 months (range 1-54 months).

Complete response, partial response, stable disease, and progressive disease were seen in 10, 11, 9, and 3 lesions, respectively. The three-year local control rate was 84.6%.

Conclusion SRT using the CyberKnife system was found to be a feasible and effective treatment to suppress the growth of locoregional recurrence of DTC.

Introduction

Surgical resection is the preferred treatment for locoregional recurrence of differentiated thyroid cancer (DTC), such as lymph node (LN) metastasis and local recurrence [1]. Most patients who undergo complete resection of locoregional recurrences of DTC still have a relatively good prognosis. However, some recurrences are unresectable because of their aggressive invasion to adjacent organs or severe adhesions after repeated surgeries. The therapeutic value of radioactive iodine therapy (RAI) and conventional external beam radiotherapy (EBRT) for locoregional recurrences is also known to be limited. Though RAI treatment and EBRT are thought to be treatment options for inoperable locoregional recurrences of DTC, there is little evidence for RAI, and the use of RAI alone is not recommended in the guidelines [1, 2]. There are also some studies of EBRT for inoperable locoregional lesions of DTC, but it has been found to often cause mild or severe radiation-related toxicity [3, 4]. On the other hand, the advantage of stereotactic radiotherapy (SRT) using the CyberKnife (Accuray; Sunnyvale, CA, USA) compared to conventional EBRT is that it minimizes damage to proximal organs and enables high-dose irradiation to lesions. The usefulness of SRT in the treatment of various kinds of cancers has been reported [5]. The objective of the present study was to investigate the feasibility and efficacy of SRT as salvage

treatment for locoregional recurrence of DTC.

Methods

Subjects

In this study, 52 locoregional recurrent lesions in 31 patients who received SRT using the CyberKnife for LN or local recurrence of DTC between August 2011 and December 2017 were studied. The medical records of these patients were retrospectively reviewed.

Radiotherapy

SRT using the CyberKnife was performed in some institutes in Tokyo. The irradiation planning including the fraction and dosage was prepared by experienced radiologists taking into account lesion size and location.

Follow-up and Evaluation

Information on the adverse events and resultant symptoms associated with SRT was collected for 52 locoregional recurrent lesions in 31 patients. Adverse events were assessed using Common Terminology Criteria for Adverse Events Version 4.0 [6]. Thirty-three of the 52 locoregional recurrent lesions were measurable and assessable, and they could be evaluated for therapeutic effectiveness by follow-up CT. Response was assessed using the RECIST criteria [7], and all measurements were performed on

CT scans. LNs with a short axis ≥ 15 mm and local recurrences with a long axis ≥ 10 mm were considered measurable and assessable as target lesions. Complete response (CR) was defined as reduction in the short axis to < 10 mm in LNs and disappearance of the target lesions in local recurrences; partial response (PR) was defined as at least a 30% decrease in diameter; and progressive disease (PD) was defined as at least a 20% increase in diameter of the target lesion and an absolute increase of at least 5 mm. Stable disease (SD) was defined as neither sufficient shrinkage to qualify for PR nor sufficient increase to qualify for PD.

Statistical analysis

The Kaplan-Meier method was used to estimate the local control rate (LCR) and cause-specific survival (CSS). The data were analyzed with a statistical software program (JMP 11.0, SAS Institute, Inc. Cary, NC).

Results

Patient Characteristics and Previous Treatments

Between August 2011 and December 2017, 31 (6 male, 25 female) patients received SRT for LN or local recurrence of DTC. The patients' median age was 71 years (range 43-89 years). Twenty-five patients had papillary thyroid carcinoma, five had follicular

thyroid carcinoma (FTC), and one had poorly differentiated cancer. Sixteen patients had synchronous distant metastases at the time of SRT. All patients underwent neck surgeries more than once, with a median number of three times. Seventeen patients received RAI treatment and two had previously received EBRT to the neck. In one patient with distant disease, a tyrosine kinase inhibitor (TKI) was used prior to SRT. The patients' characteristics and previous treatments are summarized in Table 1.

Profiles of Target Lesions and the Details of SRT

Fifty-two locoregional recurrent lesions in 31 patients with recurrent DTC were treated by SRT using the CyberKnife system. Forty-two lesions were LN metastases, and 10 lesions were local recurrences. Forty-five lesions were located in the cervix, four in the mediastinum, and three in the axilla. The median diameters of LN lesions and local recurrent lesions were 20 mm and 30 mm, respectively. Six of 52 locoregional recurrent lesions caused symptoms: pain in 2 patients, dysphagia in 2 patients, left vocal cord palsy in one patient, and right ptosis due to Horner's syndrome in one patient. SRT was delivered in one to 20 fractions, and the median dose was 30 Gy (Table 2).

Adverse Events

Adverse events associated with SRT are shown in Table 3. Only one case was a severe and life-threatening event: grade 4 vocal cord palsy requiring emergent tracheostomy.

The patient was a 76-year-old man who underwent three surgeries, including left recurrent laryngeal nerve resection for FTC. He had complete palsy of the left vocal cord and incomplete palsy of the right vocal cord before SRT. Because tracheal dorsal local recurrence occurred, SRT with 40 Gy/10 fractions was performed for the recurrent lesion. Two months after the treatment, wheezing and respiratory distress appeared. Fixation of the right vocal cord and narrowing of the glottis were confirmed on laryngoscopy. Therefore, emergent tracheotomy was performed. In addition, a 44-year-old woman developed transient unilateral recurrent nerve palsy due to irradiating tumors involving the recurrent nerve in the mediastinum, and a 60-year-old woman developed panic disorder after treatment as the trigger. All other adverse events were mild and limited to within a couple of months.

Treatment Outcomes

The 33 lesions could be evaluated for therapeutic effectiveness by follow-up CT, and the median follow-up period was 14 months (range 1-54 months). CR, PR, SD, and PD were seen in 10, 11, 9, and 3 lesions, respectively. The response rate (CR and PR) was 63.6% (Table 4). After SRT, the symptoms were improved in 2 lesions causing pain and one lesion causing difficulty to swallow of the 6 lesions presenting with symptoms; the symptoms in the other 3 lesions could not be followed. Figure 1 shows the local control

rate (LCR) of 33 lesions. The 1-year LCR was more than 90%, and 2- and 3-year LCRs were more than 80%. Figure 2 shows the cause-specific survival (CSS) of 31 patients after SRT. Eighteen-month CSS was 87.4%. Three patients died of systemic DTC metastases. Causes of death were progression of multiple lung metastases, malignant pleural effusion, and gastrointestinal bleeding due to decline of the patient's general condition with systemic metastases. No patients died due to progression of target lesions after SRT.

Discussion

The CyberKnife is an image-guided SRT device composed of a robot arm, LINIAC, and target tracking system. It is possible to irradiate a target with less damage to proximal organs by moving the robot arm that has a wide range of motion. SRT enables the precise delivery of high-dose radiation to the target using a small number of fractions. Although the role of SRT has been investigated in various sites, such as the lung, liver, spine, and prostate, few studies have yet addressed the efficacy of SRT for recurrent thyroid cancer [5, 8-11].

RAI treatment and EBRT are recommended for inoperable locoregional recurrences of DTC if ^{131}I imaging is positive; EBRT alone is another option in the absence of ^{131}I

uptake [1]. Though there is a small amount of evidence on RAI for locoregional recurrence of DTC, one study retrospectively reported that RAI therapy for LN recurrence of DTC was effective in 88.1% of cases [12]. In addition, there have been some studies of EBRT for thyroid cancer. One retrospective study reported results for adjuvant and salvage EBRT in 26 patients with residual DTC disease, and the 2- and 4-year LCRs were 77% and 62%, respectively [3]. On the other hand, there was a pilot study of SRT using the CyberKnife for DTC. The study reviewed the outcomes of nine patients treated by SRT for cervical lymph node recurrence of DTC, and no local progression was observed for a period of 23 months [5]. In the present study, the response rate was 63.6%, and 3-year LCR was 84.6% with SRT for 33 locoregional recurrent lesions of DTC.

The majority of studies have reported radiation-related toxicity of EBRT in thyroid cancer. One study reported 24 and 14 cases of grade 3 dysphagia and mucositis, respectively, in 76 patients who underwent EBRT [3]. Another study of 131 patients who received EBRT reported that 10 patients had severe late radiation-induced morbidities; seven required dilation for esophageal stricture, and two had tracheal stenosis [4]. In contrast, one study reported no adverse events in nine patients who underwent SRT for recurrent LN metastases of thyroid cancer [5]. In the present study,

adverse events associated with SRT for 52 locoregional recurrent lesions were not frequent and mostly mild. However, depending on the target site, SRT has a risk of airway obstruction, such as recurrent laryngeal nerve paralysis and vocal cord fixation. It is necessary to be particularly careful with SRT in patients with recurrent laryngeal nerve paralysis due to surgery or remaining tumor. One study reported that SRT using the CyberKnife as re-irradiation for recurrent head and neck cancers caused grade 3 or worse toxicity in 25 (21%) of 117 patients [13]. In the present study, one of two patients who underwent SRT after EBRT presented with grade 2 dermatitis. Therefore, it is necessary to pay more attention when SRT is used as re-irradiation.

For unresectable locoregional recurrences, local therapies, such as ethanol ablation or radiofrequency ablation (RFA), are also options [1]. One study reported that RFA for locoregional recurrent DTC in the neck achieved a volume reduction ratio of $95.1\pm 12.3\%$ and 82% of the lesions disappeared completely after RFA [14]. Similarly, several other studies reported high therapeutic effects of ethanol ablation and microwave ablation for locoregional recurrent DTC [15, 16]. Because these interventions are performed percutaneously, the lesion sites for which such treatment can be performed are limited. In addition, these therapies are somewhat more invasive than radiation therapy due to the need for needle puncture. However, they have

different advantages from radiotherapy, for example in terms of treatment costs and availability.

TKIs are new treatment options for DTC with RAI-refractory and/or unresectable progressive disease, including locoregional recurrent lesions [17]. Phase 3 trials of sorafenib, lenvatinib, vandetanib, and cabozantinib for locally advanced or metastatic DTC showed their effectiveness in treatment, and these TKIs were already in clinical use for patients [18-21]. However, TKIs have several clinical problems, such as complicated and cumbersome adverse events, rapid regrowth after temporary interruption of TKI treatment, and high treatment costs [17]. Thus, it is thought that TKIs should be used for progressive, symptomatic, and/or imminently threatening DTC that is not amenable to satisfactory control using directed approaches (e.g., surgery, radiation therapy including SRT, other local therapies) [2].

Because DTC is generally not aggressive, patients with locoregional recurrent disease are normally managed conservatively. However, intervention is necessary for symptomatic lesions or lesions that tend to increase and/or that are highly likely to present symptoms in the future, such as lesions infiltrating or in close proximity to the organs or musculoskeletal regions. It is considered appropriate to use SRT for locoregional recurrent lesions of DTC in such cases. We believe that SRT can be a

useful option as a preliminary step of TKI therapy.

There are some limitations to the present study. First, the regional control rate including non-irradiated lesions was not calculated, and the crude regional control rate may be inferior to that of EBRT including elective nodal irradiation. Therefore, caution is needed when considering SRT for multiple lesions, and EBRT should be selected in some cases. Second, the follow-up period for assessing therapeutic effectiveness was short, and the sample size was small. Third, the retrospective design may have led to unstable results due to the non-integrality of the data and inclusion and exclusion biases.

Conclusion

In select patients, SRT using the CyberKnife system was found to be a feasible and effective treatment to suppress the growth of locoregional recurrence of DTC.

Disclosure Statement

No competing financial interests exist.

References

1. Robert IH, William ML, Douglas WB et al (2015) NCCN Guidelines Thyroid carcinoma version 2.2015
2. Haugen B, Alexander E, Bible K et al (2016) 2015 American thyroid association management guidelines for adult patients with thyroid nodules and differentiated thyroid cancer. *Thyroid* 26
3. Stephanie AT, Kyungmouk SL, Ronald AG et al (2009) Role of external beam radiotherapy in patients with advanced or recurrent nonanaplastic thyroid cancer: memorial sloan-kettering cancer center experience. *International Journal of Radiation Oncology Biology Physics* 73:795-801
4. David LS, Mark JL, Kian A et al (2009) Post-operative external beam radiotherapy for differentiated thyroid cancer-outcomes and morbidity with conformal treatment. *International Journal of Radiat Oncology Biology Physics* 74:1083-1091
5. Jin HK, Mi-Sook K, Seong YY et al (2010) Stereotactic body radiotherapy for refractory cervical lymph node recurrence of nonanaplastic thyroid cancer. *Otolaryngology-Head and Neck surgery* 142:338-343
6. U.S.Department of Health and Human Services, National institutes of health, National Institutes of Health (2009) Common Terminology Criteria for Adverse Events

(CTCAE) Version 4.0 (v4.03: June 14, 2010)

7. Eisenhauer EA, Therasse P, Bogaerts LH et al (2009) New response evaluation criteria in solid tumours: Revised RECIST guideline (version 1.1). *European journal of cancer* 45:228-247

8. Kawabe J, Higashiyama S, Sougawa M et al (2017) Usefulness of stereotactic radiotherapy using CyberKnife for recurrent lymph node metastasis of differentiated thyroid cancer. *Case reports in endocrinology* 2017:7956726

9. Baumann P, Nyman J, Hoyer M, et al (2009) Outcome in a prospective phase II trial of medically inoperable stage I non-small-cell lung cancer patients treated with stereotactic body radiotherapy. *Journal of Clinical Oncology* 27:3290-3296

10. King CR, Brooks JD, Gill H, et al (2009) Stereotactic body radiotherapy for localized prostate cancer: interim results of a prospective phase II clinical trial. *Int J Radiat Oncol Biol Phys* 73:1043-1048

11. Rusthoven KE, Kavanagh BD, Burri SH, et al (2009) Multi-institutional phase I/II trial of stereotactic body radiation therapy for lung metastases. *J Clin Oncol* 27:1579-1584

12. Ying H, Ming-zhi P, Jian-mi H et al (2016) Iodine-131: An effective method for treating lymph node metastases of differentiated thyroid cancer. *Medical Science*

Monitor 22:4924-4928

13. Yamazaki H, Demizu Y, Okimoto T et al (2017) Reirradiation for recurrent head and neck cancers using charged particle or photon radiotherapy. *Strahlenther Onkol* 193:525-533

14. Lim H, Baek J, Lee J et al (2015) Efficacy and safety of radiofrequency ablation for treating locoregional recurrence from papillary thyroid cancer. *Eur Radiol* 25:163-170

15. Vannucchi G, Covelli D, Perrino M et al (2014) Ultrasound-guided percutaneous ethanol injection in papillary thyroid cancer metastatic lymph-nodes. *Endocrine* 47:648-651

16. Yue W, Chen L, Wang S et al (2015) Locoregional control of recurrent papillary thyroid carcinoma by ultrasound-guided percutaneous microwave ablation: a prospective study. *Int J Hyperth* 31:403-408

17. Masaki C, Sugino K, Saito N et al (2017) Lenvatinib induces early tumor shrinkage in patients with advanced thyroid carcinoma. *Endocrine Journal* 64:819-826

18. Brose M, Nutting C, Jarzab B et al (2014) Sorafenib in locally advanced or metastatic, radioactive iodine-refractory, differentiated thyroid cancer: a randomized, double-blind, phase 3 trial. *Lancet* 384:319-328

19. Robinson B, Schlumberger M, Wirth L et al (2016) Characterization of tumor size

changes over time from the phase 3 study of lenvatinib in thyroid cancer 101:4103-4109

20. Wells S, Robinson B, Gagel R et al(2012) Vandetanib in patients with locally advanced or metastatic medullary thyroid cancer: a randomized, double-blind phase III trial 30:134-141

21. Elisei R, Schlumberger M, Muller S et al (2013) Cabozantinib in progressive medullary thyroid cancer 31:3639-3646

Figure Legends

Table 1. Characteristics and previous treatments of 31 patients

Table 2. Profiles of 52 recurrent lesions of 31 patients and details of SRT

Table 3. Adverse events associated with SRT for 52 lesions

Table 4. Treatment outcomes of SRT in 33 lesions evaluated by follow-up CT and assessed using the RECIST criteria

Figure 1. Local control rate of 33 lesions after SRT

Figure 2. Cause-specific survival of 31 patients after SRT

Table 1
Characteristics and previous treatment of 31 patients

Patient characteristics	
Age (y)	
Median (range)	71 (43-89)
Sex	
Male	6
Female	25
Histology	
Papillary carcinoma	25
Follicular carcinoma	5
Poorly differentiated carcinoma	1
Stage at the time of initial surgery*	
I	2
III	8
IVA	17
IVB	1
Unknown	3
Distant disease at the time of SRT	
Lung	12
Bone	2
Lung and bone	1
Lung, bone and brain	1
Duration from initial surgery to SRT (months)	
Median (range)	148 (11-375)
Previous treatment	
No. of neck surgeries	
Median (range)	3 (1-7)
RAI treatments	
Yes	17
(range of cumulative dose)	(1110-47952 MBq)
No	14
Previous neck EBRT	
Yes	2
No	29
TKI treatment	
Yes	1
No	30

*TNM Classification of Malignant Tumours 7th ed, SRT: stereotactic radiotherapy, RAI: radiozctive iodine thrapy, EBRT: external beam radiotherapy, TKI: tyrosine kinase inhibitor

Table 2
Profiles of 52 recurrent lesions of 31 patients and
details of SRT

Profiles of recurrent lesions	
Type of recurrent tumor	
LN metastasis	42
Local recurrence	10
Localization	
Neck	45
Mediastinum	4
Axilla	3
Tumor diameter (mm)*	
LN metastasis	
Median (range)	20 (7.2-43)
Local recurrence	
Median (range)	30 (8-41)
Symptoms caused by recurrent tumor	
Yes	
Pain	(2)
Dysphagia	(2)
Vocal cord palsy	(1)
Horners' syndrome	(1)
No	
46	
Details of SRT	
No. of fractions (fr)	
Median (range)	5 (1-20)
SRT dose	
Median (range)	30 Gy (15-66)

*LN metastasis: short diameter, Local recurrence:
long diameter

Table 3**Adverse events associated with SRT for 52 lesions**

	Grade	n
Vocal cord palsy	4	1
Recurrent laryngeal nerve palsy	2	1
Pain, skin	≤ 2	3
Nausea	≤ 2	2
Pharyngitis	≤ 2	2
Oral mucositis	2	1
Panic disorder	2	1
Dysgeusia	1	2

Table 4

Treatment outcomes of SRT in 33 lesions evaluated by follow-up CT and assessed using the RECIST criteria

Follow-up period

Median (range) 14 months (1-54)

Response (n)	LN	Local	Total (%)
CR	9	1	10 (30.3)
PR	9	2	11 (33.3)
SD	7	2	9 (27.3)
PD	2	1	3 (9.1)
CR+PR+SD=30/33			90.9%
CR+PR=20/33			63.6%

CR: complete response, PR: partial response, SD: stable disease, PD: progressive disease

Figure 1. Local control rate of 33 lesions after SRT

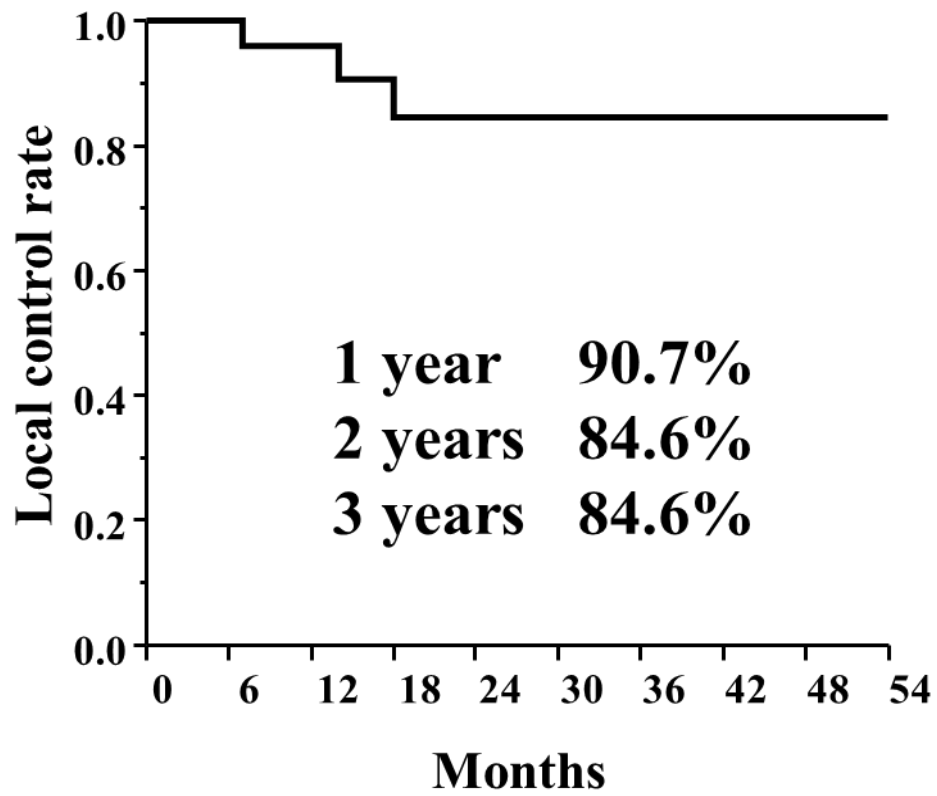


Figure 2. Cause-specific survival of 31 patients after SRT

