Brain & Development 40 (2018) 841–849

BRAIN & DEVELOPMENT
Official Journal of the Japanese Society of Child Neurology

www.elsevier.com/locate/braindev

Original article

Quantitative evaluation of regional cerebral blood flow changes during childhood using ^{123}I-N-isopropyl-iodoamphetamine single-photon emission computed tomography

Yuko Hirata [a,b,*], Shin-ichiro Hamano [a], Satoru Ikemoto [a,b], Atsuko Oba [b], Ryuki Matsuura [a,b]

[a] *Division of Neurology, Saitama Children's Medical Center, 1-2 Shintoshin, Chuo-ku, Saitama-city, Saitama 330-8777, Japan*
[b] *Department of Pediatrics, The Jikei University School of Medicine, 3-19-18 Nishi-shinbashi, Minato-ku, Tokyo 105-8461, Japan*

Received 8 October 2017; received in revised form 2 February 2018; accepted 9 June 2018

Abstract

Objective: To quantitatively evaluate regional cerebral blood flow (rCBF) and regional developmental changes during childhood using ^{123}I-N-isopropyl-iodoamphetamine single-photon emission computed tomography (SPECT) and autoradiography.

Methods: We retrospectively analyzed quantitative values of rCBF in 75 children (29 girls) aged between 16 days and 178 months (median: 12 months), whose brain images, including magnetic resonance imaging and SPECT data, were normal under visual inspection at Saitama Children's Medical Center between 2005 and 2015. The subjects had normal psychomotor development, no focal neurological abnormalities, and neither respiratory nor cardiac disease at the time of examination. Regions of interest were placed automatically using a three-dimensional stereotactic template.

Results: rCBF was lowest in neonates, who had greater rCBF in the lenticular nucleus, thalamus, and cerebellum than the cerebral cortices. rCBF increased rapidly during the first year of life, reaching approximately twice the adult levels at 8 years, and then fell to approximately adult levels in the late teenage years. Cerebral cortex rCBF sequentially increased in the posterior, central, parietal, temporal, and callosomarginal regions during infancy and childhood.

Conclusions: rCBF changed dramatically throughout childhood and ranged from lower than adult values to approximately two times higher than adult values. It had different trajectories in each region during brain development. Understanding this dynamic developmental change is necessary for SPECT image evaluation in children.

Keywords: Cerebral blood flow; Quantitative evaluation; Developmental change; Regional difference; Single-photon emission computed topography

1. Introduction

Human brain development involves various changes including sequential anatomical and histological alteration. Various developmental changes occur dynamically during childhood and especially in infancy. Brain development is related to the emergence of corresponding functions. Cerebral blood flow (CBF) and cerebral metabolism changes correspond to cerebral activity. Brain functional images of CBF and cerebral metabolism are used to evaluate cerebral activity in many brain diseases including infarction, dementia,

* Corresponding author at: Division of Neurology, Saitama Children's Medical Center, 1-2 Shintoshin, Chuo-ku, Saitama-City, Saitama 330-8777, Japan.
E-mail address: hirata.yuko@scmc.pref.saitama.jp (Y. Hirata).

https://doi.org/10.1016/j.braindev.2018.06.008
0387-7604/

epilepsy, tumor, and encephalitis. However it is difficult to interpret these findings in children because their brains undergo various changes and have normal deviations associated with brain development.

Assessment of CBF and its age-related changes during childhood has been addressed by several nuclear medicine approaches: single-photon emission computed tomography (SPECT) using ^{133}Xe, ^{99m}Tc-ethylcysteinate dimer, ^{123}I-N-isopropyl-iodoamphetamine (^{123}I-IMP), and $C^{15}O_2$ positron emission tomography (PET) [1–5]. These previous studies have reported that regional CBF (rCBF) increases in early childhood, peaks between 4 and 7 years of age, and then declines to reach the adult levels. Several studies have also found that infants have higher rCBF in the basal ganglia and visual and sensorimotor cortices than in other regions. These studies have also reported that rCBF in the frontal region increases slowly. Similar age-related patterns have been reported for brain metabolism, as measured using fluorodeoxyglucose (FDG) PET [6–8]. However, regional differences in CBF changes during development are unclear because there have only been a few quantitative analytical studies of nuclear medicines. These studies have been performed in small numbers of subjects, and several studies have included subjects with abnormal brain images and cerebrovascular diseases. Arterial spin-labeling perfusion magnetic resonance imaging (MRI) has adapted for evaluation of rCBF developmental changes in recent studies [9–11]. These studies have shown that rCBF is decreased beginning before 10 years of age, similar to the results using nuclear medicines. However, there have been few studies in infants and toddlers using arterial spin-labeling perfusion MRI, and rCBF changes in early childhood have not been revealed. Therefor, we have not enough knowledge of developmental changes in rCBF, especially regarding regional differences.

Quantitative evaluation of childhood rCBF is necessary to understand brain development, plasticity, and the clinical and pathological conditions of central nervous system diseases. Quantitative analysis of rCBF during developmental period using SPECT requires an appropriate tracer, objective and reproducible region of interest (ROI) settings, and large number of subjects. ^{123}I-IMP SPECT can be used to measure rCBF. ^{123}I-IMP has a relatively high first-pass extraction among rCBF SPECT tracers and can be quantitatively evaluated. Three-dimensional stereotactic ROI template (3DSRT) is a program that anatomically standardizes brain SPECT images and quantitatively analyzes them using a three-dimensional stereotactic ROI template. Using 3DSRT enable the creation of objective and universal ROI settings. There has been no report regarding developmental changes in rCBF measured using ^{123}I-IMP SPECT data analyzed with 3DSRT. We aimed to quantitatively analyze rCBF developmental changes and to investigate characteristic regional patterns throughout childhood using ^{123}I-IMP SPECT and 3DSRT.

2. Subjects and methods

This retrospective reviews was approved by the Saitama Children's Medical Center Institutional Review Board. Informed consent for ^{123}I-IMP SPECT was obtained from the children's parent and assent was obtained from the children. Medical histories were established for each child and the child's family prior to the scan.

2.1. Participants

We searched a database of children who received ^{123}I-IMP SPECT and underwent autoradiography (ARG) between January 2005 and December 2015 at Saitama Children's Medical Center. The children had transient neurological events and suspected intracranial disease. We selected children according to the following 6 criteria at the time of examination to analyze approximate normal rCBF values: 1) normal brain images on computed tomography or MRI; 2) no respiratory or cardiac disease; 3) normal psychomotor development at the time of examination or normal psychomotor development one year after SPECT for infants younger than 18 months; 4) no focal abnormalities in neurological examinations; 5) normal SPECT findings detected in visual inspections by more than 2 physicians, including a radiologist specializing in SPECT; and 6) SPECT performed with appropriate timing of arterial blood sampling and under a resting or sleeping state.

2.2. SPECT image acquisition

Quantitative rCBF measurements were conducted using the ARG method developed by Iida et al [12]. A triple-head gamma camera (Siemens Multispect3; Siemens Medical Systems Inc.; Hoffman Estates, IL) equipped with a fan beam collimator was used. Data were acquired using a 128 × 128 matrix for 120 degrees and 24 min with 5-degree steps of 60 s per frame. Siemens Icon-P (Siemens Medical Systems Inc.) was used to reconstruct SPECT image and a Butterworth filter and attenuation correction (Chang, $\mu = 0.1\ cm^{-1}$) were used to produce scanning images with an orbitomeatal line and 256 × 256 matrix (1.2 mm/pixel). We intravenously injected ^{123}I-IMP up to a dose of 83 MBq in children younger than 1 year of age, up to 111 MBq in children between 1 and 7 years old, and up to 167 MBq in children older than 8 years. Ten minutes after the ^{123}I-IMP injection, arterial blood was collected from

the side contralateral to the injection, and whole-blood radioactivity was measured using a well-type scintillation counter. The obtained cross-calibration factors used as inputs when determining quantitative rCBF. SPECT was performed during sleep or rest with the eye closed. When conscious sedation was required, oral choral hydrate or pentobarbital calcium was administered. Thyroid radioactivity blocking was performed by oral administration of Lugo's solution for 4 days, beginning 2 days before SPECT. Twenty-four-minute scans were performed 40 and 180 min after ^{123}I-IMP injection (early image center time and late image center time, respectively).

We used 3DSRT software, which is a fully automated ROI analysis program developed by Takeuchi et al [13–15]. This software is freely available for Windows and is used by many clinicians to quantitatively investigate rCBF in adults and children [16–19]. The SPECT images were anatomically standardized using Statistical Parametric Mapping 99 followed by unilateral quantification of 318 ROIs grouped into the following 12 segments: callosomarginal (53 ROIs), precentral (43 ROIs), central (28 ROIs), parietal (28 ROIs), angular (8 ROIs), temporal (35 ROIs), posterior cerebral (40 ROIs), pericallosal (31 ROIs), lenticular nucleus (14 ROIs), thalamus (10 ROIs), hippocampus (15 ROIs), and cerebellum (13 ROIs). The ROI template is based on anatomically standardized T1 weighted MRI according to Brodmann's cytoarchitectural map.

We investigated age-related changes in each region's CBF values and compared regional developmental trajectories. We used cubic approximated curves for subjects younger than 2 years of age and sextic approximated curves for all children. We used JMP ver.11.0.0 (SAS Institute Inc.; Cary, NC, USA) to produce the approximated curves.

3. Results

Seven hundred and seventy-two children underwent ^{123}I-IMP SPECT with ARG between January 2005 and December 2015. Seventy-five children (46 boys and 29 girls) met all the 6 inclusion criteria. Their ages ranged from 16 days to 178 months (median: 12 months) at the time of SPECT. Final diagnoses included cryptogenic localization-related epilepsy, cryptogenic generalized epilepsy, benign infantile seizures, conversion disorder, recovery phase of acute encephalopathy and acute cerebellar ataxia, vestibular neuritis, and ocular movement abnormality. Although 22 of the 75 children were taking daily antiepileptic medications at the time of SPECT, none displayed sedation or other side effects.

None of the children had differences between left and right rCBF in each ROI greater than 10%. Therefore, we used average rCBF values from both sides. We obtained normal adult rCBF values from the study by Hatazawa et al [20]. Here we show rCBF values for all regions and approximated curves for 7 representative regions out of the 12 regions presented in the figures. The approximated curve for the angular region described a similar trajectory to that obtained for the posterior cerebral region. Those for the precentral and parietal regions increased between those for the central and temporal regions during infancy. Therefor, we selected the callosomarginal, central, temporal, posterior cerebral, lenticular nucleus, thalamus, and cerebellum regions as 7 representative regions to show rCBF developmental changes. Approximated curves for the parietal, angular, precentral, and hippocampus regions are shown as Supporting Information (Figs. S1 and S2).

Figs. 1 and 2 show rCBF values and approximated curves in 44 infants younger than 2 years. All regions had lower CBF in neonates than in adults [20] (right-side vertical bars in each graph). rCBF was higher in the lenticular nucleus, thalamus, and cerebellum (in descendsing order) than in the cerebral cortices. rCBF rapidly increased in all regions during the first year of life and rose to higher than approximately half of the adult values. In this period, rCBF in cortex increased more rapidly in the posterior cerebral region than in any other cortical region and reached the levels found in lenticular nucleus. The central region had the next most rapid increases. rCBF in the callosomarginal region increased most slowly in cortex. Among the cortical regions, rCBF increased in the posterior cerebral, angular, central, parietal, precentral, temporal, and callosomarginal regions in descending order (Figs. 2 and S1). rCBF increased more slowly in hippocampus than in all other regions (Fig. S1).

Figs. 3 and 4 show rCBF values and approximated curves in all 75 children. rCBF continued to increase in all regions from about 2 to 8 years of age, although this increase was slower than that observed during infancy. rCBF reached approximately twice the normal adult values before age 10. After this age, rCBF declined and approached adult levels in the late teenage years. In the approximated curves, rCBF in callosomarginal region in teenage years became the highest in the cortical regions. rCBF in thalamus and lenticular nucleus regions in teenage years remained higher than those in the cortical regions and in the cerebellum. We actually show the median rCBF value in each region in 9 teenaged subjects (Table S1). The median rCBF value in the callosomarginal region was as high as that in the posterior cerebral region (44.8 ml/100 g/min vs. 43.2 m l/100 g/min, respectively). In addition, the median rCBF value in the thalamus was as high as that in the lenticular nucleus (48.2 ml/100 g/min vs. 47.4 ml/100 g/min, respectively).

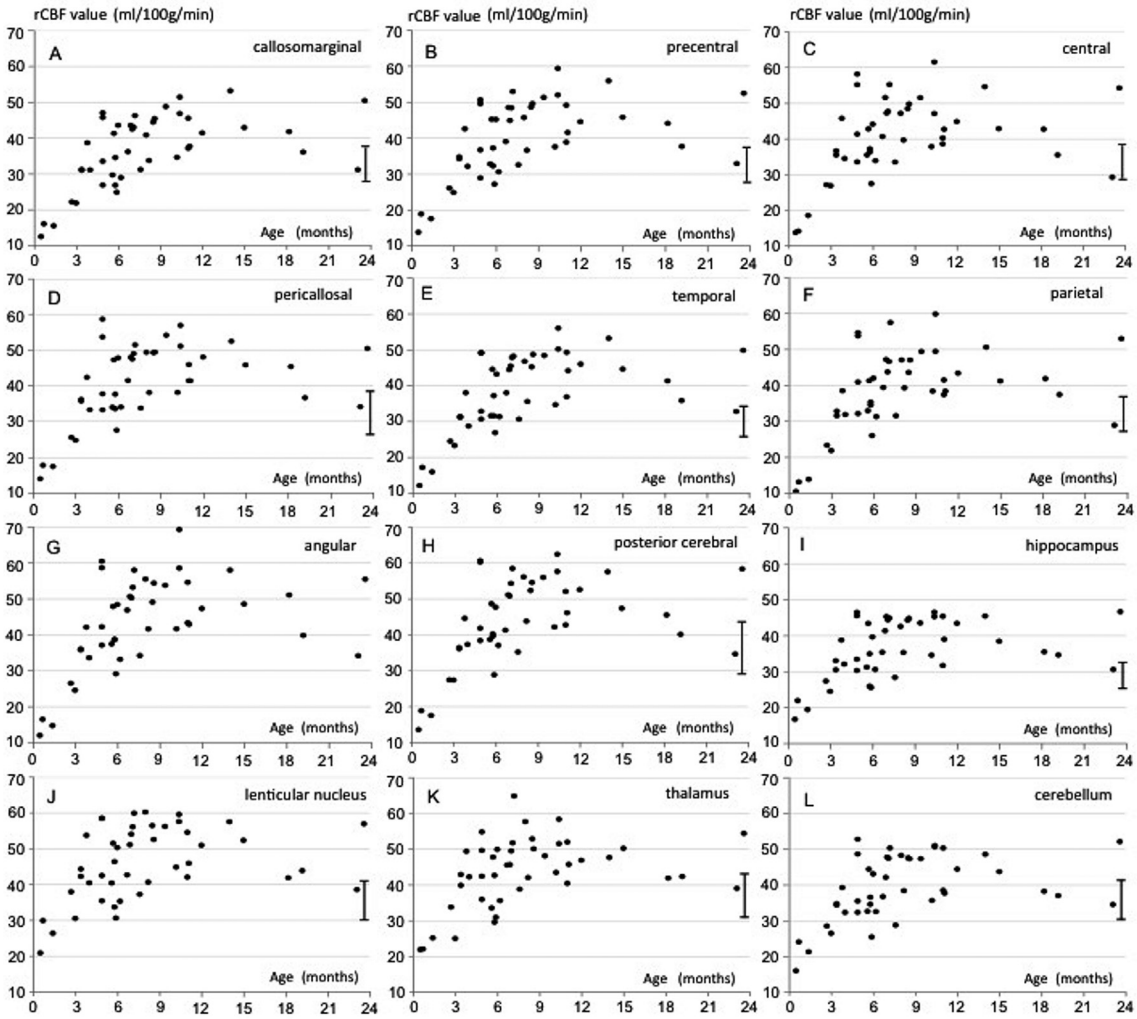

Fig. 1. Regional cerebral blood flow (rCBF) values (the average of left and right in each patient) in 44 infants younger than 2 years. (A) callosomarginal, (B) precentral, (C) central, (D) pericallosal, (E) temporal, (F) parietal, (G) angular, (H) posterior cerebral, (I) hippocampus, (J) lenticular nucleus, (K) thalamus, and (L) cerebellum. Filled circles show values from individual patients. Right-side vertical bars in each graph show the normal adult values [20]. Normal adult values in angular has not been showed.

4. Discussion

Prior to our study, only a few studies had quantitatively analyzed age-related developmental rCBF changes and described characteristic regional patterns during the neonatal period and in young adulthood. Those studies had some limitations regarding sample size, numbers of infants in the study, underlying disorders in the subjects, and the methods used to set ROIs. Using ^{123}I-IMP SPECT analyzed with 3DSRT, we investigated rCBF changes and regional patterns in the above-mentioned age range. Our data comprised quantitatively analyzed ARG measurements. Our study had a larger number of participants than previous studies using nuclear medicines. This enabled us to obtain more detailed information regarding characteristic regional patterns, especially in infants. In fact, our study included 44 infants younger than 2 years of age and 37 infants younger than 1 year of age. This is important, as these ages are periods when CBF and brain metabolism change most dynamically.

In a study investigating developmental CBF changes, Kennedy and Sokoloff [21] recorded whole-brain blood flow data using nitrous oxide. They found that the average global CBF in children was approximately 1.8 times that of normal young adults. Using dimensional measurements, Chiron et al. [1] studied rCBF using ^{133}Xe SPECT. They found that all cortical rCBF at birth was lower than in adulthood, but that it increased after birth until the age of 5 or 6 years, reaching values 150–185% of those seen in adults. rCBF then decreased to adult levels by the late teenage years. Non-cortical rCBF was unclear in neonates, but increased during infancy, reaching a maximum at 5 or 6 years, similar to rCBF in cortical regions. Non-cortical rCBF then progressively decreased to adult levels. Takahashi et al. [5] studied rCBF using $C^{15}O_2$ PET. They found that all

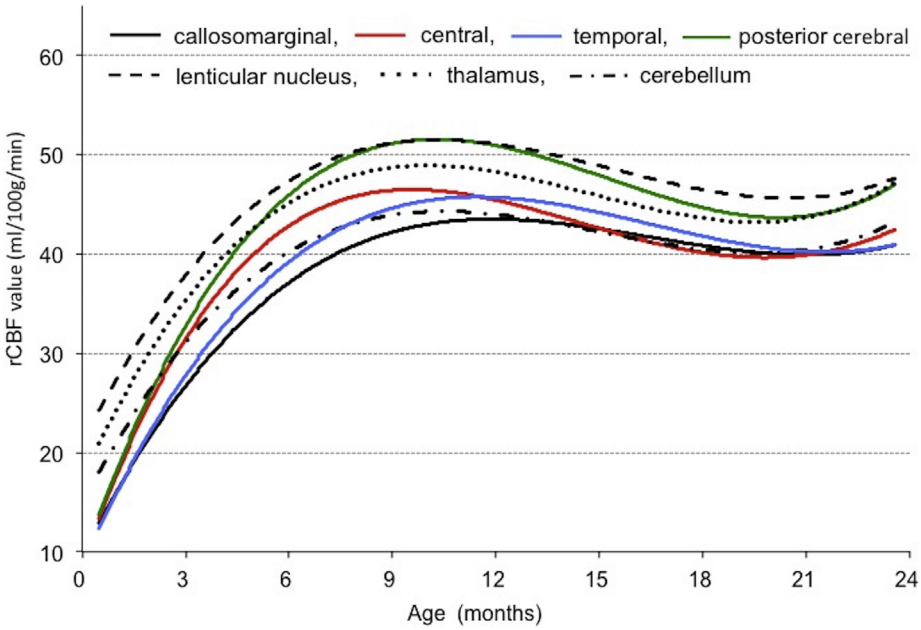

Fig. 2. Approximated curves for the 7 representative regions in 44 infants younger than 2 years. Cortical regions are shown as solid lines. The lenticular nucleus, thalamus, and cerebellum are shown in dashed, dotted, and dashed-dotted line, respectively. The R-squared values for the callosomarginal, central, temporal, posterior cerebral, lenticular nucleus, thalamus, and cerebellum are 0.59, 0.52, 0.62, 0.59, 0.42, 0.48, and 0.50, respectively.

non-cortical rCBF values and all cortical rCBF values, except those in the visual area were lower in neonates than in adulthood. rCBF increased and exceeded levels observed in adults during development, peak at around the age of 7 years. rCBF then decreased to those observed during adulthood. The authors of the above study also found that the latest increase was observed in the frontal association area. One should however note that many of the subjects in that study had cerebrovascular disease or abnormal brain images.

Some studies using ^{123}I-IMP SPECT in children feature qualitative analyses [22–24], but few include quantitative assessments. To our knowledge, only Kobayashi et al. [4] have quantitatively studied developmental changes in rCBF using ^{123}I-IMP SPECT. They reported that rCBF increased in early childhood and then decreased and plateaued in young adulthood. However, their study included only one subject younger than 1 year of age. In addition, several subjects in the above study had cyanotic heart disease, stroke, or tumors, which are factors that may have influenced the ^{123}I-IMP SPECT measurements. In addition, the authors of that study did not use objective ROI settings.

Investigation of cerebral metabolism using FDG PET revealed that local cerebral metabolic rates of glucose (lCMGlc) were low at birth but rapidly reached adult levels by age 2. They remained higher than adult levels until approximately age around 4 to 9 and then declined to adult levels in the teenage years [6,7].

As described above, it is known that rCBF and lCMGlc rapidly change during development and reach maximum values in early childhood. These measures then reach levels observed in adults in the late teenage yeaes, although details regarding regional differences in these measures have not been unclear. Our quantitative data showed rCBF developmental patterns were in agreement with previous studies and were consistent with childhood lCMGlc developmental changes.

Our study has 3 potentially interesting implications. The first concerns the neonatal period. Previous studies have reported different values in a wide range for neonatal rCBF due to the small numbers of neonates enrolled in each study [1,6]. We found that CBF in all regions was lower during the neonatal prtiod than in adulthood, and that rCBF values during the neonatal period were higher in the lenticular nucleus, thalamus, hippocampus, and cerebellum (in descending order) than in the cerebral cortices. Consistent with our results, a study using cerebral FDG PET reported that childhood FDG uptake was highest in the basal ganglia, followed by the thalamus and cerebellum [25].

The second implication of our study concerns the rCBF-incraseing phase. Previous studies have reported that CBF in all regions increases to adult levels by age 2 and then exceeds adult levels until ages 5–9 [1,5]. Our study found that CBF in all regions rapidly exceeded adult levels during the first year of life. We believed that the increasing phase might occur in

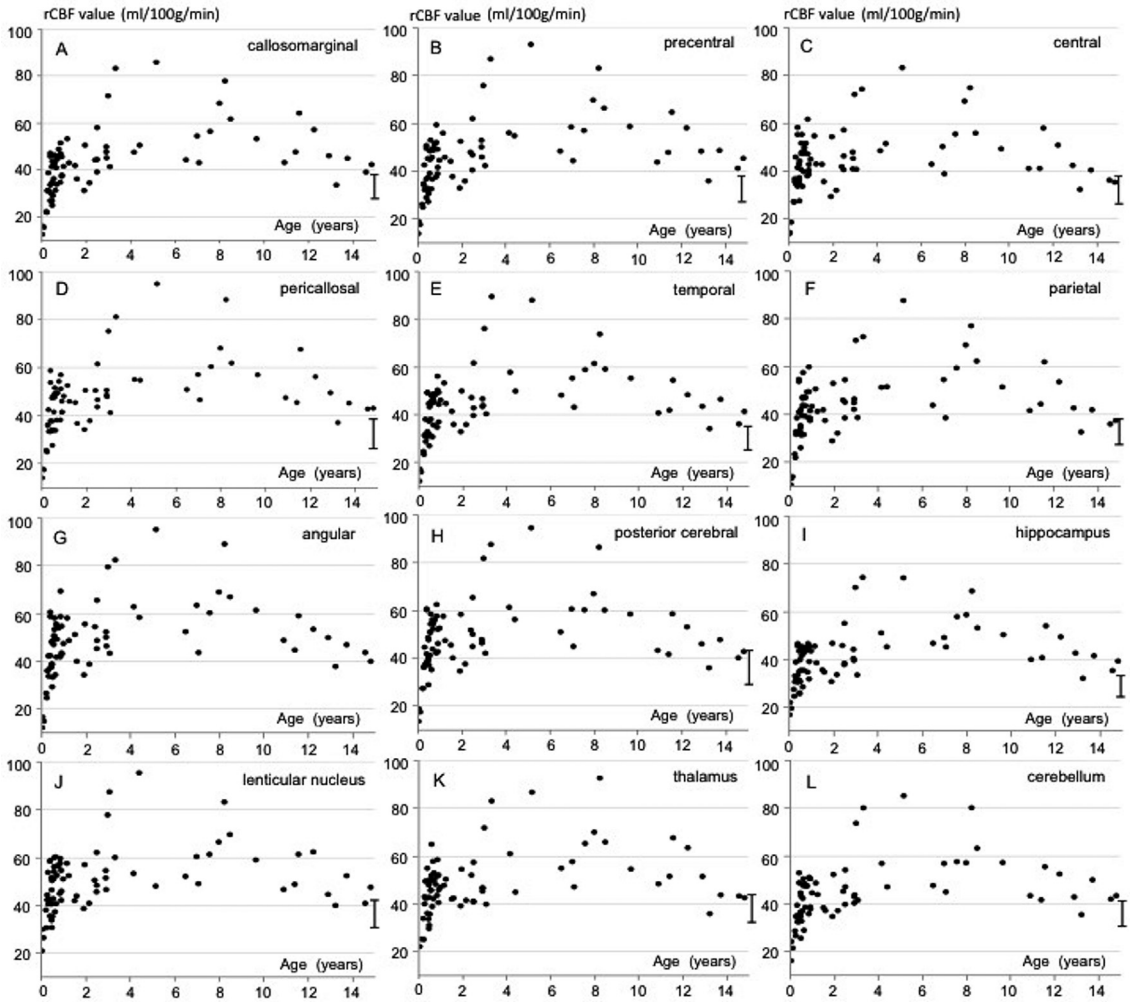

Fig. 3. Regional cerebral blood flow (rCBF) values (the average of left and right for each patient) in all 75 children. (A) callosomarginal, (B) precentral, (C) central, (D) pericallosal, (E) temporal, (F) parietal, (G) angular, (H) posterior cerebral, (I) hippocampus, (J) lenticular nucleus, (K) thalamus, and (L) cerebellum. Filled circles show values from individual patients. Right-side vertical bars in each graph show the normal adult values [20]. Normal adult values in angular has not been showed.

2 stages: from birth to the age of 1 year and during the ages of approximately 2–8 years.

The third implication concerns rCBF trajectories in different brain regions. We were able to show rCBF developmental sequence, which was most prominent during infancy. From the neonatal period to the age of 2 years, the rCBF values in the posterior cerebral and angular regions increased more rapidly than in any other region and reached levels found in the lenticular nucleus at approximately 8 months of age. rCBF values in the central, parietal, precentral, temporal, and callosomarginal regions followed the same trend sequentially. rCBF value in callosomarginal region increased more slowly than in other cortical regions and became as high as that in the posterior cerebral region in the teenage years. Some ^{123}I-IMP SPECT-based qualitative analyses have indicated that uptake within the cerebral cortex is high in the sensorimotor and visual cortices at birth, and that ^{123}I-IMP uptake then occurs in other cerebral regions in a posteroanterior direction [22–24]. In addition, previous investigations of rCBF and glucose metabolism have reported that the frontal lobes matured more slowly than other regions [5–7,24]. An FDG uptake study has also shown that the frontal lobes have the most intense uptake when compared to other cortical regions after the age of approximately 7 years [25].

Childhood rCBF changes are believed to be associated with brain development and anatomical, histological, and functional changes. These changes include changes in neuronal size, neuron numbers, dendritic or axonal arborization, synaptic density, and myelination. The rapid increase stage observed in our study may reflect these intensive brain developmental changes. Neuronal size, dendritic or axonal arborization, and synaptic density rapidly increase during this period,

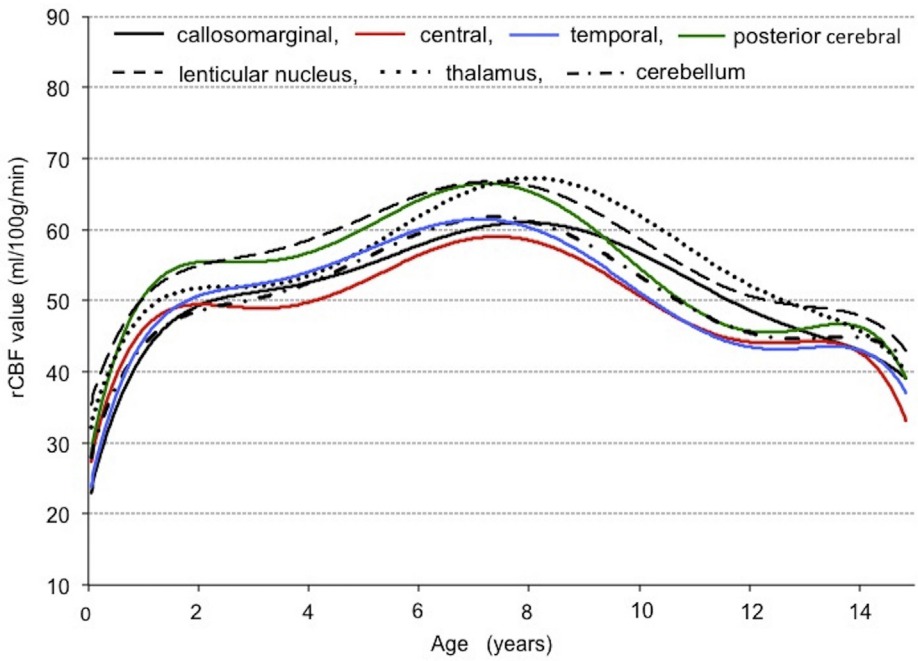

Fig. 4. Approximated curves for the 7 representative regions in all 75 children. Cortical regions are shown as solid lines. The lenticular nucleus, thalamus and cerebellum are shown in dashed, dotted, and dashed-dotted lines, respectively. The R-squared values for the callosomarginal, central, temporal, posterior cerebral, lenticular nucleus, thalamus, and cerebellum are 0.51, 0.34, 0.46, 0.39, 0.36, 0.40, and 0.44, respectively.

and myelination rapidly advances [26–28]. Brain weight and gray and white matter volumes therefore increase at the same time. The slow increase stage in our study may reflect a shift in brain development toward pruning and function potentiation and away from rapid structural changes. Between infancy and school age, myelination continues to advance, although synaptic pruning also starts. These lead to white matter volume increases and gray matter volume decreases [26–28]. The decline phase in our study may reflect a shift in brain development toward potentiation and function maintenance. In this period, brain weight reaches adult levels, but synaptic pruning and myelination continue [28,29]. We also found that developmental changes in rCBF occurred at different speeds in each brain region, consistent with previous reports on the development of brain structure and function. Myelination advances from the basal nucleus to the cerebral white matter [29,30]. In the cerebral cortex, it proceeds from the central sulcus toward the poles and proceeds anteriorly from posterior to frontotemporal sites [29,30]. Some reports have shown that synaptic density changes and increases in gray matter also advance in the same direction [31,32].

Our study has some limitations. First, there were fewer children aged between 2 and 10 years, in whom rCBF may have reached peak values. Second, many younger children were taking sedative drugs, as examining them would have been extremely difficult without their use. Third, our study involved children receiving daily antiepileptic medications. Any sedative or antiepileptic drugs may alter rCBF and cerebral metabolism [33]. Finally, although we selected children according to 6 criteria, our study may have involved children with abnormal rCBF. More than 2 physicians including a radiologist specializing in SPECT estimate the SPECT image to be normal, but it is not an absolute because there are not a normal rCBF values in children. For ethical reasons, studies addressing normal childhood rCBF are limited to children with suspected neurological conditions.

5. Conclusions

We investigated dynamic age-related rCBF changes during childhood and regional-related differences in these changes. These dynamic developmental changes should be considered when evaluating SPECT images from children. Future research will further reveal rCBF developmental changes in children.

6. Author's contributions

SH contributed to the study conception and design. SI, AO, and RM contributed to the acquisition of the date. All authors read and approved the final manuscript.

7. Ethical approval and consent to participate

All procedures performed in studies involving human participants were in accordance with the ethical standards of the institutional and/or national research

committee and with the 1964 Helsinki declaration and its later amendments or comparable ethical standards. For this type of study formal consent is not required.

Informed consent was obtained from all individual participant's parents and assent was obtained from the participants included in the study.

8. Funding

This research did not receive any specific grant from funding agencies in the public, commercial, or non-for-profit sectors.

Appendix A. Supplementary data

Supplementary data associated with this article can be found, in the online version, at https://doi.org/10.1016/j.braindev.2018.06.008.

References

[1] Chiron C, Raynaud C, Mazière B, Zilbovicius M, Laflamme L, Masure MC, et al. Changes in regional cerebral blood flow during brain maturation in children and adolescents. J Nucl Med 1992;33:696–703.
[2] Barthel H, Wiener M, Dannenberg C, Bettin S, Sattler B, Knapp WH. Age-specific cerebral perfusion in 4- to 15-year-old children: a high-resolution brain SPECT study using ^{99m}Tc-ECD. Eur J Nucl Med 1997;24:1245–52.
[3] Schiepers C, Verbruggen A, Casaer P, De Roo M. Normal brain perfusion pattern of Technetium-99m-ethylcysteinate dimer in children. J Nucl Med 1997;38:1115–20.
[4] Kobayashi A, Ito M, Shiraishi H, Kishi K, Sejima H, Haneda N, et al. A quantitative study of regional cerebral blood flow in childhood using ^{123}I-IMP SPECT: with emphasis on age-related changes (in Japanese). No To Hattatsu (Tokyo) 1996;28:501–7.
[5] Takahasi T, Shirane R, Sato S, Yoshimoto T. Developmental changes of cerebral blood flow and oxygen metabolism in children. Am H Neuroradiol 1999;20:917–22.
[6] Chugani HT, Phelps ME, Mazziotta JC. Positron emission tomography study of human functional development. Ann Neurol 1987;22:487–97.
[7] Kinnala A, Suhonenpolvi H, Aarimaa T, Kero P, Korvenranta H, Ruotsalainen U, et al. Cerebral metabolic rate for glucose during the first six months of life: an FDG positron emission tomography study. Arch Dis Child 1996;74:F153–7.
[8] Shan ZY, Leiker AJ, Onar-Tomas A, Li Y, Feng T, Reddick WE, et al. Cerebral glucose metabolism on positron emission tomography of children. Hum Brain Mapp 2014;35:2297–309.
[9] Wintermark M, Lepori D, Cotting J, Roulet E, van Melle G, Meuli R, et al. Brain perfusion in children: evolution with age assessed by quantitateive perfusion computed tomogramphy. Pediatrics 2004;133:1642–52.
[10] Taki Y, Hashizume H, Sassa Y, Takeuchi H, Wu K, Asano M, et al. Correlation between gray matter density-adjusted brain perfusion and age using brain MR images of 202 healthy children. Hum Brain Mapp 2011;32:1973–85.
[11] Avants BB, Duda JT, Kilroy E, Krasileva K, Jann K, Kandel BT, et al. The pediatric template of brain perfusion. Sci Data 2015;2:150003.
[12] Iida H, Itoh H, Nakazawa M, Hatazawa J, Nishimura H, Onishi Y, et al. Quantitative mapping of regional cerebral blood flow using iodo-123-IMP and SPECT. J Nucl Med 1994;35:2019–30.
[13] Takeuchi R, Yonekura Y, Matsuda H, Konishi J. Usefulness of a three-dimensional stereotaxic ROI template on anatomically standardized 99mTc-ECD SPECT. Eur J Nucl Mol Imaging 2002;29:331–41.
[14] Takeuchi R, Yonekura Y, Takeda SK, Fujita K, Konishi J. Fully automated quantification of regional cerebral blood flow with tree-dimensional stereotaxic region of interest template: validation using magnetic resonance imaging – Technical Note. Neurol Med Chir (Tokyo) 2003;43:153–62.
[15] Takeuchi R, Matsuda H, Yoshioka K, Yonekura Y. Cerebral blood flow SPECT in transient global amnesia with automated ROI analysis by 3DSRT. Eur J Nucl Med Mol Imaging 2004;31:578–89.
[16] Ito M, Mori K, Hashimoto T, Miyazaki M, Hori A, Kagami S, et al. Findings of brain 99mTc-ECD SPECT in high-functioning autism-3-dimensional stereotactic ROI template analysis of brain SPECT. J Med Invest 2005;52:49–56.
[17] Kobayashi S, Tateno M, Utsumi K, Takahashi A, Saitoh M, Morii H, et al. Quantitative analysis of brain perfusion SPECT in Alzheimer's disease using a fully automated regional cerebral blood flow quantification software, 3DSRT. J Neurol Sci 2008;264:27–33.
[18] Kimura N, Kumamoto T, Masuda T, Nomura Y, Hanaoka T, Hazama Y, et al. Evaluation of the effect of thyrotropin releasing hormone (TRH) on regional cerebral blood flow in spinocerebellar degeneration using 3DSRT. J Neurol Sci 2009;281:93–8.
[19] Hamano S, Higurashi N, Koichihara R, Oritsu T, Kikuchi K, Yoshinari S, et al. Interictal cerebral blood flow abnormality in cryptogenic West syndrome. Epilepsia 2010;51:1259–65.
[20] Hatazawa J, Iida H, Shimosegawa E, Sato T, Murakami M, Miura Y. Regional cerebral blood flow measurement with iodine-123-IMP autoradiography: normal values, reproducibility and sensitivity to hypoperfusion. J Nucl Med 1997;38:1102–8.
[21] Kennedy C, Sokoloff L. An adaptation of the nitrous oxide method to the study of the cerebral circulation in children; normal values for cerebral blood flow and cerebral metabolic rate in childhood. J Clin Invest 1957;36:1130–7.
[22] Rubinstein M, Denays R, Ham HR, Piepsz A, VanPachterbeke T, Haumont D, et al. Function imaging of brain maturation in humans using iodine-123 iodoamphetamine and SPECT. J Nucl Med 1989;30:1982–5.
[23] Kato T, Okuyama K. Assessment of maturation and impairment of the brain by I-123 iodoamphetamine SPECT and MR imaging in children. Showa Univ J Med Sci 1993;5:99–114.
[24] Tokumura AM, Barkovich AJ, O'uchi T, Matsuo T, Kusano S. The evolution of cerebral blood flow in the developing brain: evaluation with iodine-123 iodoamphetamine SPECT and correlation with MR imaging. Am J Neuroradiol 1999;20:845–52.
[25] London K, Howman-Giles R. Normal cerebral FDG uptake during childhood. Eur J Nucl Med Mol Imaging 2014;41:723–35.
[26] Giedd JN, Blumenthal J, Jeffries NO, Gastellanos FX, Liu H, Zijdenbos A, et al. Brain development during childhood and adolescence: a longitudinal MRI study. Nat Neurosci 1999;2:861–3.
[27] Huttenlocher PR. Synaptic density in human frontal cortex-developmental changes and effects of aging. Brain Res 1979;163:195–205.
[28] Shade JP, Van Groenigen WB. Structural organization of the human cerebral cortex. I. Maturation of the middle frontal gyrus. Acta Anat 1961;47:74–111.
[29] Yakovlev PI, Lecours AR. The myelogenetic cycle of regional maturation of the brain. In: Minkowski A, editor. Regional development of the brain in early life. Oxford, England: Blackwell; 1967. p. 3–70.

[30] Brody BA, Kinney HC, Kloman AS, Gilles FH. Sequence of central nervous system myelination in human infancy. I. An autopsy study of myelination. J Neuropahtol Exp Neurol 1987;46:283–301.

[31] Huttenlocher PR, Dabholkar AS. Regional differences in synaptogenesis in human cerebral cortex. J Comp Neurol 1997;387:167–78.

[32] Gogtay N, Giedd JN, Lusk L, Hayashi KM, Greenstein D, Vaituzis AC, et al. Dynamic mapping of human cortical development during childhood through early adulthood. Proc Natl Acad Sci USA 2004;101:8174–9.

[33] Theodore WH. Antiepileptic drugs and cerebral glucose metabolism. Epilepsia 1988;29(Suppl 2):S48–55.