

Drug delivery system of basic fibroblast growth factor using gelatin hydrogel for restoration of acute vocal fold scar

Toshiki Kobayashi^{a,b}, Masanobu Mizuta^a, Nao Hiwatashi^a, Yo Kishimoto^a,
Tatsuo Nakamura^c, Shin-ichi Kanemaru^d, Shigeru Hirano^{a,*}

^a Department of Otolaryngology-Head and Neck Surgery, Graduate School of Medicine, Kyoto University, Kyoto, Japan

^b Department of Otorhinolaryngology, The Jikei University, School of Medicine Tokyo, Japan

^c Department of Biomaterials, Field of Tissue Engineering, Institute for Frontier Medical Sciences, Kyoto University, Kyoto, Japan

^d Department of Otolaryngology-Head and Neck Surgery, Kitano Hospital, Tazuke Kofukai Medical Research Institute, Osaka, Japan

ARTICLE INFO

Article history:

Received 18 January 2016

Accepted 1 April 2016

Available online 26 April 2016

Keywords:

Basic fibroblast growth factor

Hydrogel

Drug delivery system

Vocal fold scar

ABSTRACT

Objective: There continue to be therapeutic challenges in the management of vocal fold scarring. We previously showed that basic fibroblast growth factor (bFGF) injection has therapeutic potential for vocal fold scarring. However, the working time of bFGF is relatively short, and multiple injections were required in many cases to obtain the regenerative effect. An efficacious delivery system for bFGF has yet to be established. We designed a method of sustained drug delivery system (DDS) of bFGF by using a gelatin hydrogel. Hydrogel has been developed for targeted delivery and controlled release of bFGF. Hydrogel of the particle type is also injectable and commercially available. The current study aims to investigate the effects of a single injection of bFGF-DDS on acute vocal fold scarring using a canine model.

Methods: Vocal folds from eight beagles were unilaterally scarred by stripping the lamina propria. One month later, hydrogels (0.5 ml) containing 10 µg of bFGF were injected into the scarred vocal folds of four beagles (FGF-hydrogel group). Saline (0.5 ml) was injected into the other four beagles (sham group). Vibratory and histological examination of excised larynges was performed 5 months after treatment. Comparative analysis between the current data and our previous data with repeated injection of bFGF solution was also completed.

Results: Vibratory examination demonstrated significantly improved vibration in the bFGF hydrogel-treated group. Histological examination of the bFGF hydrogel group showed restoration of hyaluronic acid in the lamina propria as compared to sham. Comparison between the DDS system and our previous bFGF solution injection indicated better effects of the DDS system on vibratory amplitude.

Conclusion: A single injection of bFGF hydrogel has regenerative effects on acute vocal fold scarring, which is at least similar to repeated injection of bFGF solution.

© 2016 Elsevier Ireland Ltd. All rights reserved.

* Corresponding author at: Department of Otolaryngology-Head & Neck Surgery, Graduate School of Medicine, Kyoto University, Sakyo-ku, Kyoto 606-8507, Japan. Tel.: +81 75 751 3346; fax: +81 75 751 7225.

E-mail addresses: toshiki-koba@jikei.ac.jp (T. Kobayashi), m_mizuta@ent.kuhp.kyoto-u.ac.jp (M. Mizuta), n_hiwatashi@ent.kuhp.kyoto-u.ac.jp (N. Hiwatashi), y_kishimoto@ent.kuhp.kyoto-u.ac.jp (Y. Kishimoto), nakamura@frontier.kyoto-u.ac.jp (T. Nakamura), kanemaru@ent.kuhp.kyoto-u.ac.jp (S.-i. Kanemaru), hirano@ent.kuhp.kyoto-u.ac.jp (S. Hirano).

1. Introduction

Vocal fold scarring may occur following injury, inflammation, or phonosurgery. Scarring disrupts the layered structure of the lamina propria leading to changes in the viscoelasticity of the vocal fold mucosa, often resulting in severe and intractable dysphonia [1].

Previous histological studies [2–5] on vocal fold scarring have revealed changes in the organization and distribution of extracellular matrix components (ECM), such as dense and/or disorganized type I collagen deposition, decreased elastin, and decorin, increased fibronectin, and occasional decreases in hyaluronic acid (HA).

Medialization thyroplasty, fat/collagen injection, and scar dissection have been tried in an attempt to restore normal properties to scarred vocal folds [6]. However, these approaches do not restore normal ECM distribution. Due to the difficulty of replacing scar tissue with innate ECM, there is a lack of reliable therapeutic strategies for vocal fold scarring.

Growth factors are a strong tool for inducing tissue regeneration by stimulating and controlling cell behavior. We have previously reported on the therapeutic potential of basic fibroblast growth factor (bFGF) [7–9] and hepatocyte growth factor (HGF) [10,11] for vocal fold scarring.

It has been reported that bFGF, a stimulant for the growth of fibroblasts, decreases the deposition of collagen and increases the production of hyaluronic acid [12,13]. A subsequent *in vivo* study using canines showed the recovery of vibratory properties of scarred vocal folds after local injection of bFGF [9].

However, the working time of bFGF is relatively short, and in many cases, multiple injections are required to obtain the regenerative effects. Thus it is important to investigate alternative ways of administering growth factors that may enable these effects to be strengthened, such as through the exploration of various drug delivery systems.

A biodegradable hydrogel has been developed to enhance the *in vivo* regenerative effects of growth factors, such as HGF, bFGF, platelet-derived growth factor, and epidermal growth factor. This hydrogel has proven successful in the controlled release of biologically active growth factors in other parts of the body [14–20]. Moreover, gelatin hydrogel is commercially available (Medgel; Wako Pure Chemical Industries, Osaka, Japan), and this particular type is easily injectable.

The current study aims to investigate the effects of a single injection of bFGF hydrogel on acute vocal fold scarring using a canine model. Furthermore, comparative analyses were performed between the effects of b-FGF hydrogel obtained from the current study and injection of a bFGF solution obtained from our previous data [9].

2. Materials and methods

2.1. Animals

Eight beagle dogs, weighing 8–10 kg, were used in this study. All experimental protocols were approved by the Animal Research Committee of the Graduate School of Medicine, Kyoto University. Animal care was provided under the

supervision of the Institute of Laboratory Animals of the Graduate School of Medicine, Kyoto University.

2.2. Preparation of bFGF hydrogel

A commercially available form of human recombinant bFGF (Fiblast; Kaken Co., Tokyo, Japan) and gelatin hydrogel of particle type (Medgel P15; Wako Pure Chemical Industries, Osaka, Japan) was prepared. The hydrogel is constituted by chemically cross-linking acidic gelatin with glutaraldehyde, developed by the Department of Biomaterials, Field of Tissue Engineering, Institute for Frontier Medical Sciences, Kyoto University [14,15]. 1 mg of gelatin was mixed with 10 μ l of medicinal liquid following the instruction. To formulate the bFGF hydrogel, 10 μ g (100 μ l) of bFGF was added to 10 mg of gelatin hydrogel, and the compound was then incubated for 1 h at 37 °C to create the final product. It was dissolved in 0.5 ml of saline just before injection.

2.3. Procedure for vocal fold injury

Animals were sedated under general anesthesia with intramuscular injections of ketamine hydrochloride (6 mg/kg; Sankyo Co., Tokyo, Japan) and xylazine hydrochloride (15 mg/kg; Bayer, Tokyo, Japan). Under direct laryngoscopy, right vocal folds were injured by removal of the entire layer of the lamina propria using microscissors and microforceps under a microscope. The contralateral vocal folds were left intact as normal controls. The vocal fold scars were allowed to mature for one month and endoscopic examination under anesthesia was performed to observe wound healing every two weeks.

One month after the initial surgery, bFGF hydrogel was injected into the injured vocal fold of four beagles (bFGF hydrogel group) under direct laryngoscopy using a transoral intracordal injector. The remaining four beagles received injection of saline (0.5 ml) into the injured vocal fold (sham group).

After injection, endoscopic examination under anesthesia was performed every four weeks to observe wound healing. All animals were euthanized 6 months after initial scarring by intracardiac injection of pentobarbital sodium (25 mg/kg; Dainippon Pharmaceutical Co. Ltd, Osaka, Japan). Larynges were immediately harvested and used for vibratory examination and subsequently subjected to histological examination.

2.4. Set-up for vibratory examination of excised larynges

Vocal fold vibration was examined using an excised larynx set-up developed in previous studies [11]. For better visualization of the vocal fold, supraglottic structures, including the epiglottis, false vocal folds, and aryepiglottic folds, were removed after the resection of the superior portion of the thyroid cartilage. The arytenoid cartilages were sutured together, and an arytenoid adduction procedure was performed bilaterally using a 3-0 Prolene suture to close the glottis. The larynx was mounted on a table, and an intubation tube was inserted into the trachea and clamped tightly. Air was pumped through the tube to generate vocal fold vibrations. During the vibratory examination, saline was dripped onto the vocal folds

to keep them moist. A high-speed digital imaging system (Memrecam Ci; NAC Image Technology, Osaka, Japan) was used to record vocal fold vibrations from the superior view. The camera was mounted 50 cm above the larynx, and the image was displayed on a monitor. The images were recorded at a frame rate of 4000 frames per second, and the images were then scanned into a computer. Phonation threshold pressure (PTP) was recorded with the minimum amount of subglottal pressure required to initiate vocal fold oscillation.

The amplitude of the mucosal wave was measured to evaluate the mucosal vibration and elasticity of the vocal fold structures, namely the lamina propria, using ImageJ software (National Institutes of Health, Bethesda, MD, USA). The distance (d_1) from the midline of the glottis to the free edge of the vocal fold was measured at the anteroposterior middle portion of the vocal fold during the closed phase. The closed phase was determined based on the motion of the upper and lower lips of the vocal folds. The same distance (d_2) was measured at the maximum open phase. The mucosal wave amplitude was defined by subtracting d_1 from d_2 and was normalized by dividing this number by the anteroposterior length of the glottis, from the anterior commissure to the vocal process (L) (Fig. 1). The following formula was used: normalized mucosal wave amplitude (NMWA) = $(d_2 - d_1)/L$. Normalized glottal gap (NGG) was calculated to evaluate glottal closure during the closed phase. The glottal gap area (a) was measured using ImageJ software, and the glottal gap area was normalized by dividing it by L^2 . The following formula was used: $NGG = a/L^2 \times 100$. Each parameter of d_1 , d_2 , L , and a was measured at the most suitable cycle of vibration in which the largest displacement of the vocal fold was observed.

2.5. Histological examination

Immediately following vibratory examination, the larynges were fixed in 10% formaldehyde for later tissue examination. Larynges were subsequently embedded in paraffin, and 5 μ m-thick serial sections were prepared in the coronal plane from the anteroposterior middle portion of the vocal folds. The level of collagen, elastin, and HA in the lamina propria of each vocal fold was examined by light microscopy. Elastica van Gieson staining

was performed to identify collagen and elastin. Alcian blue staining and hyaluronidase digestion were used to identify HA. Images were captured with a Bioevo BZ-9000 microscope (Keyence Corp., Osaka, Japan). The sections were examined at $4\times$ to $40\times$ magnification. The thickness of the lamina propria (TLP) was assessed to determine the degree of scar contraction. The TLP was determined by measuring the distance from the free edge of the vocal fold down to the thyroarytenoid muscle. The following formula was used: normalized TLP (NTLP) = (TLP of the treated side)/(TLP of the normal side). These assessments were performed in a blinded fashion in which the examiners were not informed of the group to which each slide belonged.

2.6. Statistical analysis

Non-paired t tests were used to ascertain differences in NMWA, PTP, NGG, and NTLP between the bFGF hydrogel-treated group and the sham-treated group after comparing their variances using the F test. Also one-way factorial analysis of variance (ANOVA) followed by a post hoc Scheffé test were used for comparison of bFGF hydrogel group and bFGF solution group and sham group. $P < .05$ was considered statistically significant.

3. Results

3.1. Vibratory examination

Vibratory examination of excised larynges revealed improved mucosal vibration in the bFGF hydrogel group compared with the sham group. Fig. 2 shows representative cases of the bFGF hydrogel group (Fig. 2A) and the sham group (Fig. 2B). The normalized mucosal wave amplitude was significantly higher ($P = .023$) in the bFGF hydrogel group than in the sham group (Fig. 3A). The phonation threshold pressure and normalized glottal gap were significantly lower ($P = .037$ and $.023$) in the bFGF hydrogel group than in the sham group (Fig. 3B and C).

3.2. Histological examination

The results from the histological examination are shown in Fig. 4.

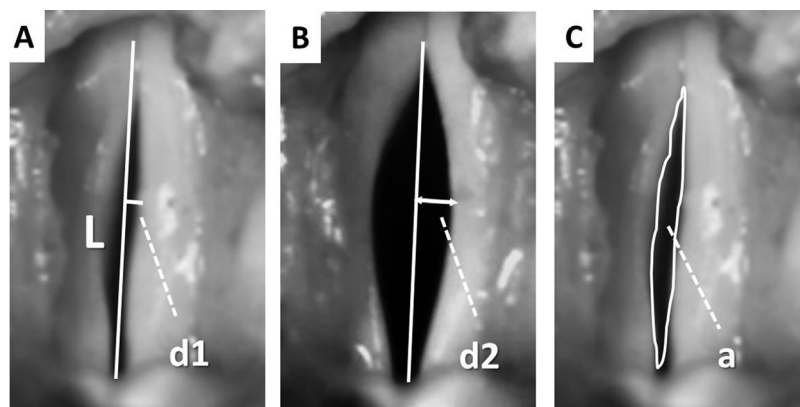


Fig. 1. Measurement of normalized mucosal wave amplitude (NMWA) and normalized glottal gap (NGG). (A) Maximum closed phase, L : membranous vocal fold length, d_1 : distance from the midline of the glottis to the free edge of the vocal fold at the closed phase; (B) maximum open phase, d_2 : the same distance at maximum open phase; (C) a : glottal area at maximum closed phase. $NMWA = (d_2 - d_1)/L$, $NGG = a/L^2$.

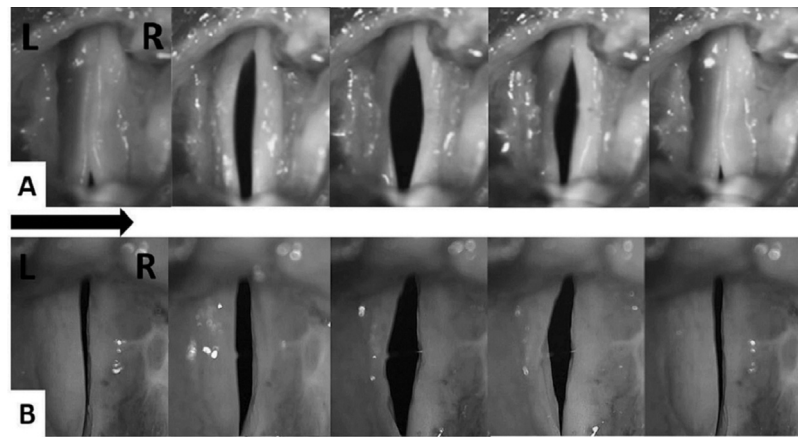


Fig. 2. In both cases, the right vocal fold was scarred. The bFGF hydrogel-treated vocal fold showed almost normal mucosal vibration (A); however, the sham-treated vocal fold was bowed and mucosal vibration was limited (B).

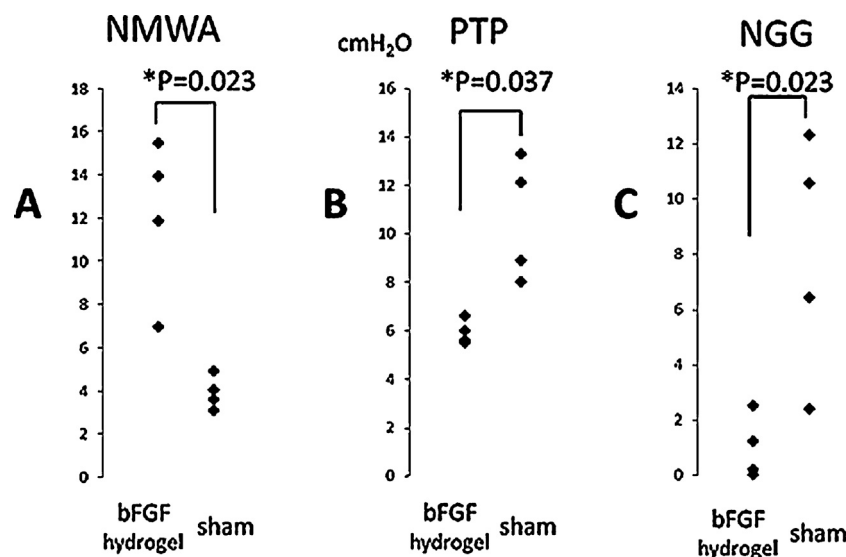


Fig. 3. Phonation threshold pressure (PTP) (A), normalized mucosal wave amplitude (NMWA) (B), and normalized glottal gap (NGG) (C) for bFGF hydrogel-treated larynges and sham-treated larynges. Measurements of excised larynges revealed significantly lower PTP, lower NGG, and increased NMWA in bFGF hydrogel-treated larynges compared with sham-treated larynges.

HA and elastin were significantly reduced in the vocal folds of the sham group, whereas the level of HA and elastin in the bFGF hydrogel group was maintained similar to the normal vocal folds.

Alcian blue staining revealed better restoration in bFGF hydrogel-treated vocal folds compared to the sham-treated group.

Elastica van Gieson staining revealed the suppression of dense collagen deposition and reorganization of elastin in the injured vocal folds of the bFGF hydrogel group compared to the sham group. NTLP was higher in bFGF hydrogel-treated vocal folds relative to the sham-treated folds ($P = .023$; Fig. 5).

4. Discussion

Vocal fold scarring remains a significant therapeutic challenge. Although various surgical injections or implantation therapies have been attempted, including fat implants [21],

collagen injection [22], and fascia implants [23], no effective therapeutic method has been established.

Recently, regenerative approaches based on the principles of tissue engineering have been examined using various growth factors. Among these, bFGF [8], HGF [10], and transforming growth factor $\beta 3$ (TGF $\beta 3$) [24] have been examined as possible effective pharmaceuticals for restoration of vocal fold scarring.

Basic fibroblast growth factor (bFGF) is an effective growth factor that induces angiogenesis and improves wound healing as a result of its action on smooth muscle cells, endothelial cells, fibroblasts, and epithelial cells [25,26]. We have confirmed that bFGF stimulated vocal fold fibroblasts to produce hyaluronic acid and suppress production of collagen type I, which appears to play a positive role in preventing scar formation within this tissue [27]. A gene expression study also revealed that bFGF significantly increases expression levels of hyaluronic acid synthase type I–III from vocal fold fibroblasts [8].

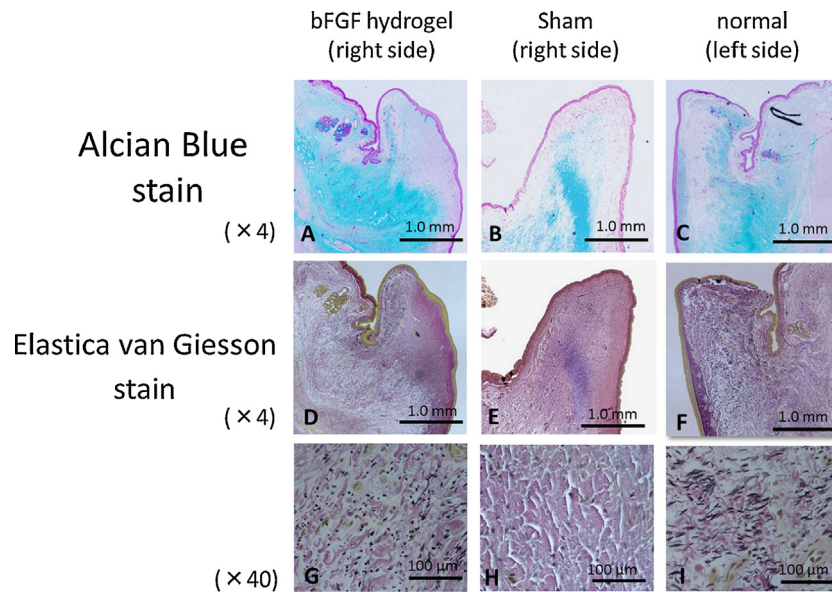


Fig. 4. Histological findings. (A–C) Alcian blue staining, (G–I) Elastica van Gieson staining; bFGF hydrogel-treated folds (A, D, G), sham-treated folds (B, E, H), and normal folds (C, F, I). Scale bars represent 1 mm (A–F) and 100 μm (G–I). The bFGF hydrogel-treated folds showed markedly favorable restoration of elastin and HA, such that they resembled the normal folds. Although there was little evidence of dense collagen deposition in the bFGF hydrogel-treated fold, excessive collagen deposition was observed in the sham-treated fold. Note that the laminar structure seen vertically in the bFGF hydrogel-treated fold (G) resembles the normal fold (I).

We have previously examined the regenerative effects of bFGF on canine vocal fold scarring by repeatedly injecting bFGF solution into the scarred vocal folds using the same set-up as in the current study. Injection of bFGF solution showed improvement in vibratory parameters and histological recovery of hyaluronic acid and reduction of excessive collagen deposition [8]. It is possible that this simple injection of bFGF solution may have considerable effects due to the exogenous

administration of bFGF stimulating production of endogenous bFGF from fibroblasts in an autocrine fashion [27].

Even with the autocrine effect, however, it is well known that bFGF rapidly diffuses from the injection site when applied in solution [28–30]; moreover, it has been reported that the half-life of bFGF in solution is 15 min [31]. These reports thus warranted further exploration into systems of administration for bFGF that would allow longer retention of the growth factor.

The gelatin hydrogel used in the current study incorporates bFGF allowing slow release within the adjacent tissues. Incorporation of bFGF into the gelatin occurs by means of ionic interactions, as well as hydrogen bonding and hydrophobic bonding; it is then gradually released from the gelatin in situ along with the degradation of the gelatin over time.

We have utilized a commercially available bFGF product suitable for human use in Japan along with a commercially available gelatin hydrogel to create a DDS for bFGF. The results are encouraging with improved vibratory properties and histological architecture. Furthermore, comparative analyses between the current data and our previous data [9] in which repeated injection of bFGF solution was performed in an identical experimental set-up indicated significantly improved NMWA in the bFGF hydrogel group than in the bFGF solution group ($P = .019$), although PTP and NGG showed no significant difference between the two groups (Fig. 6). This is not a direct comparison, but it suggests that bFGF-DDS may be same or possibly superior to injection of bFGF solution in terms of its regenerative effects on vibratory function.

Tamura et al. used the similar gelatin hydrogel with bFGF for fat injection to paralyzed canine vocal folds [32]. The hydrogel was delivered together with fat into the lateral portion of the vocal folds for augmentation, and was found to contribute in maintaining fat with minimal absorption for a long time. The

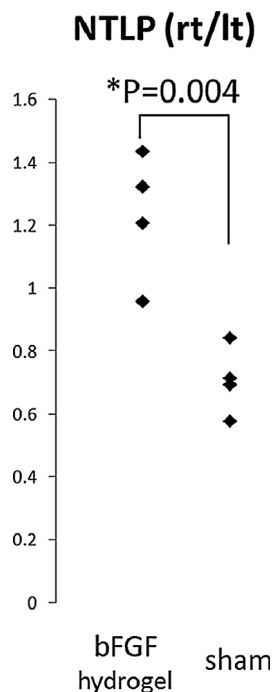


Fig. 5. NTLP was higher in bFGF hydrogel-treated vocal folds relative to the sham-treated folds ($P = .023$).

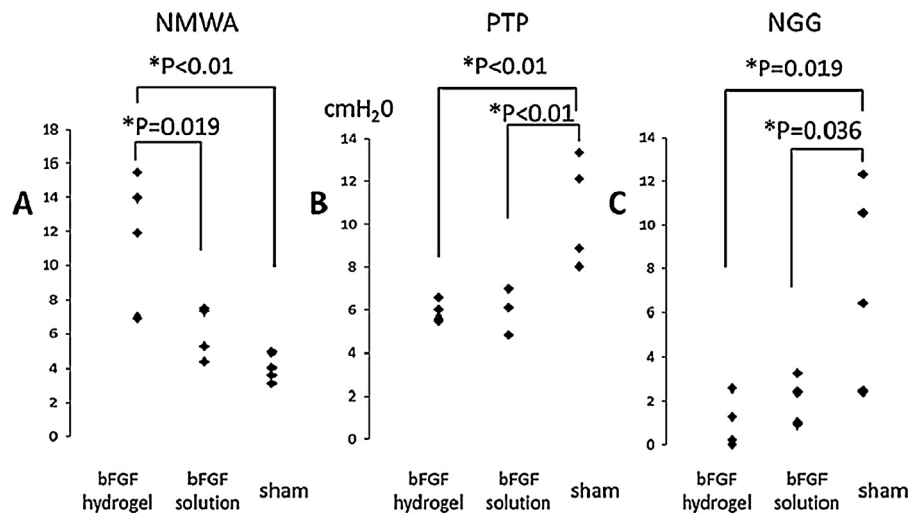


Fig. 6. Comparative analysis of vibratory examinations between the current study and a previous study using a bFGF solution. The bFGF hydrogel group showed a significantly higher ratio of NMWA than the bFGF solution group. No significant differences were observed for PTP and NGG between the two groups.

current results suggested that the hydrogel also worked inside the vocal fold mucosa.

A weak point of the current study may be lack of data of scarred vocal folds treated with hydrogel only. However, we have already had data on effects of hydrogel only in our previous study, in which the scarred canine vocal folds were treated in exactly the same protocol using the same hydrogel only [33], and the results indicated no positive effect of hydrogel injection to scarred vocal folds in terms of vibratory and histological aspects. We skipped the hydrogel group also because of restriction of a number of large experimental animals by the national regulation on animal study.

5. Conclusion

The current study examined effects of drug delivery system of basic FGF on acute vocal fold scar by comparing those of repeated injection of bFGF solution in our previous study. The results suggest that a single injection of bFGF hydrogel has regenerative effects on acute vocal fold scarring, which seems to be stronger than injection of bFGF solution.

Financial disclosure

None.

Conflict of interest

The authors declare that they have no conflict of interest.

Acknowledgement

This study was supported by a Grant from the Ministry of Health and Welfare of Japan.

References

- [1] Hirano S. Current treatment of vocal fold scarring. *Curr Opin Otolaryngol Head Neck Surg* 2005;13:143–7.
- [2] Hirano S, Minamiguchi S, Yamashita M, Ohno T, Kanemaru S, Kitamura M. Histologic characterization of human scarred vocal folds. *J Voice* 2009;23:399–407.
- [3] Rousseau B, Hirano S, Scheidt TD, Welham NV, Thibeault SL, Chan RW, et al. Characterization of vocal fold scarring in a canine model. *Laryngoscope* 2003;113:620–7.
- [4] Rousseau B, Hirano S, Chan RW, Welham NV, Thibeault SL, Ford CN, et al. Characterization of chronic vocal fold scarring in a rabbit model. *J Voice* 2004;18:116–24.
- [5] Tateya T, Tateya I, Sohn JH, Bless DM. Histologic characterization of rat vocal fold scarring. *Ann Otol Rhinol Laryngol* 2005;114:183–91.
- [6] Dailey SH, Ford CN. Surgical management of sulcus vocalis and vocal fold scarring. *Otolaryngol Clin North Am* 2006;39:23–42.
- [7] Hirano S, Bless DM, Heisey D, Ford CN. Effect of growth factors on hyaluronan production by canine vocal fold fibroblasts. *Ann Otol Rhinol Laryngol* 2003;112:617–24.
- [8] Suehiro A, Hirano S, Kishimoto Y, Tateya I, Rousseau B, Ito J. Effects of basic fibroblast growth factor on rat vocal fold fibroblasts. *Ann Otol Rhinol Laryngol* 2010;119:690–6.
- [9] Suehiro A, Hirano S, Kishimoto Y, Rousseau B, Nakamura T, Ito J. Treatment of acute vocal fold scar with local injection of basic fibroblast growth factor: a canine study. *Acta Oto-Laryngol* 2010;130:844–50.
- [10] Hirano S, Bless DM, Rousseau B, Welham NV, Montequin DW, Chan RW, et al. Prevention of vocal fold scarring by topical injection of hepatocyte growth factor in a rabbit model. *Laryngoscope* 2004;114:548–56.
- [11] Hirano S, Bless DM, Nagai H, Rousseau B, Welham NV, Montequin DW, et al. Growth factor therapy for vocal fold scarring in a canine model. *Ann Otol Rhinol Laryngol* 2004;113:777–85.
- [12] Hong HH, Trackman PC. Cytokine regulation of gingival fibroblast lysyl oxidase, collagen, and elastin. *J Periodontol* 2004;73:145–52.
- [13] Heldin P, Laurent TC, Heldin CH. Effect of growth factors on hyaluronan synthesis in cultured human fibroblasts. *Biochem J* 1989;258:919–22.
- [14] Ozeki M, Ishii T, Hirano Y, Tabata Y. Controlled release of hepatocyte growth factor from gelatin hydrogels based on hydrogel degradation. *J Drug Target* 2001;9:461–71.
- [15] Ikada Y, Tabata Y. Protein release from gelatin matrices. *Adv Drug Deliv Rev* 1998;31:287–301.
- [16] Sakaguchi G, Tambara K, Sakakibara Y, Ozeki M, Yamamoto M, Premaratne G, et al. Control released hepatocyte growth factor prevents the progression of heart failure in stroke-prone spontaneously hypertensive rats. *Ann Thorac Surg* 2005;79:1627–34.
- [17] Haraguchi T, Okada K, Tabata Y, Maniwa Y, Hayashi Y, Okita Y. Controlled release of basic fibroblast growth factor from gelatin

- hydrogel sheet improves structural and physiological properties of vein graft in rat. *Arterioscler Thromb Vasc Biol* 2007;27:548–55.
- [18] Nakae M, Kamiya H, Naruse K, Horio N, Ito Y, Mizubayashi R, et al. Effects of basic fibroblast growth factor on experimental diabetic neuropathy in rats. *Diabetes* 2006;55:1470–7.
- [19] Hokugo A, Sawada Y, Hokugo R, Iwamura H, Kobuchi M, Kambara T, et al. Controlled release of platelet growth factors enhances bone regeneration at rabbit calvaria. *Oral Surg Oral Med Oral Pathol Oral Radiol Endod* 2007;104:44–8.
- [20] Hori K, Sotozono C, Hamuro J, Yamasaki K, Kimura Y, Ozeki M, et al. Controlled-release of epidermal growth factor from cationized gelatin hydrogel enhances corneal epithelial wound healing. *J Control Release* 2007;118:169–76.
- [21] Sataloff RT, Spiegel JR, Hawkshaw M, Rosen DC, Heuer RJ. Autologous fat implantation for vocal fold scar: a preliminary report. *J Voice* 1997;11:238–46.
- [22] Remacle M, Lawson G, Degols JC, Evrard I, Jamart J. Microsurgery of sulcus vergeture with carbon dioxide laser and injectable collagen. *Ann Otol Rhinol Laryngol* 2000;109:141–8.
- [23] Tsunoda K, Takanosawa M, Niimi S. Autologous transplantation of fascia into the vocal fold: a new phonosurgical technique for glottal incompetence. *Laryngoscope* 1999;109:504–8.
- [24] Ohno S, Hirano S, Kanemaru S, Kitani Y, Kojima T, Ishikawa S, et al. Transforming growth factor β 3 for the prevention of vocal fold scarring. *Laryngoscope* 2012;122:583–9.
- [25] Przybylski M. A review of the current research on the role of bFGF and VEGF in angiogenesis. *J Wound Care* 2009;18:516–9.
- [26] Nakajima H, Sakakibara Y, Tambara K, Iwakura A, Doi K, Marui A, et al. Therapeutic angiogenesis by the controlled release of basic fibroblast growth factor for ischemic limb and heart injury: toward safety and minimal invasiveness. *J Artif Organs* 2004;7:58–61.
- [27] Hirano S, Bless DM, del Río A, Connor NP, Ford CN. Therapeutic potential of growth factors for aging voice. *Laryngoscope* 2004;114:2161–7.
- [28] Ellman MB, An HS, Muddasani P, Im HJ. Biological impact of the fibroblast growth factor family on articular cartilage and intervertebral disc homeostasis. *Gene* 2008;420:82–9.
- [29] Lazarous DF, Shou M, Stiber JA, Dadhania DM, Thirumurti V, Hodge E, et al. Pharmacodynamics of basic fibroblast growth factor: route of administration determines myocardial and systemic distribution. *Cardiovasc Res* 1997;36:78–85.
- [30] Edelman ER, Nugent MA, Karnovsky MJ. Perivascular and intravenous administration of basic fibroblast growth factor: vascular and solid organ deposition. *Proc Natl Acad Sci U S A* 1993;90:1513–7.
- [31] Whalen GF, Shing Y, Folkman J. The fate of intravenously administered bFGF and the effect of heparin. *Growth Factors* 1989;1:157–64.
- [32] Tamura E, Fukuda H, Tabata Y. Adipose tissue formation in response to basic fibroblast growth factor. *Acta Oto-Laryngol* 2007;127:1327–31.
- [33] Ohno T, Hirano S, Kanemaru S, Yamashita M, Umeda H, Suehiro A, et al. Drug delivery system of hepatocyte growth factor for the treatment of vocal fold scarring in canine model. *Ann Otol Rhinol Laryngol* 2007;116:762–9.