

Case Report

Concomitant Esophageal Achalasia and Early Gastric Cancer Operated on Simultaneously : Report of a Case

Fumiaki YANO, Nobuo OMURA, Kazuto TSUBOI, Yoshiyuki HOYA, Tomoyoshi OKAMOTO,
and Katsuhiko YANAGA

Department of Surgery, The Jikei University School of Medicine

ABSTRACT

The annual incidence of achalasia in Japan is extremely low at 1 case per 100,000 persons. To the best of our knowledge, no cases of concomitant esophageal achalasia and gastric cancer have previously been reported. We report a case in which concomitant esophageal achalasia and early gastric cancer were operated on simultaneously. A 65-year-old man was suspected, on the basis of barium contrast examination, to have an abnormality of the esophagus. Although upper gastrointestinal endoscopy showed a normal esophagus, early gastric cancer was diagnosed, and the patient was referred to us. Endoscopic ultrasonography showed that the tumor had invaded the submucosal layer. Therefore, we decided to perform gastrectomy. An esophageal contrast X-ray examination at our hospital showed that the lower esophagus was significantly curved and that the greatest transverse diameter of the esophagus was 43 mm. Therefore, concomitant esophageal achalasia was diagnosed. Laparoscopic Heller myotomy and Dor fundoplication and laparoscopy-assisted distal partial gastrectomy were performed. The duration of surgery was 295 minutes, and blood loss was minimal. The postoperative course was unremarkable except for left shoulder pain, and the patient was discharged on postoperative day 21. (Jikeikai Med J 2013 ; 60 : 29-33)

Key words : achalasia, gastric cancer, Heller myotomy and Dor fundoplication, laparoscopy-assisted distal partial gastrectomy

INTRODUCTION

Although gastric cancer is common in Asian countries, the annual incidence of achalasia in Japan is low at 1 case per 100,000 persons per year. To the best of our knowledge, no cases of concomitant esophageal achalasia and gastric cancer have been reported. We report on a patient with concomitant esophageal achalasia and early gastric cancer who underwent laparoscopic Heller myotomy and Dor fundoplication (LHD) and laparoscopy-assisted distal partial gastrectomy (LADG).

CASE REPORT

A 65-year-old man was found, with a barium contrast examination performed as part of a routine medical examination, to have an abnormality of the esophagus. He had a 6-month history of progressive dysphagia without weight loss. Although esophagogastroduodenoscopy (EGD) was judged to show a normal esophagus, he was found to have early gastric cancer and was referred to us. Subsequent EGD showed esophageal dilatation, retention of secretions (Fig. 1A), and a tight esophagogastric junction (Fig. 1B).

Received for publication, March 29, 2013

矢野 文章, 小村 伸朗, 坪井 一人, 保谷 芳行, 岡本 友好, 矢永 勝彦

Mailing address : Fumiaki YANO, Department of Surgery, The Jikei University School of Medicine, 3-25-8 Nishi-shimbashi, Minato-ku, Tokyo 105-8461, Japan.

E-mail : f-yano@jikei.ac.jp

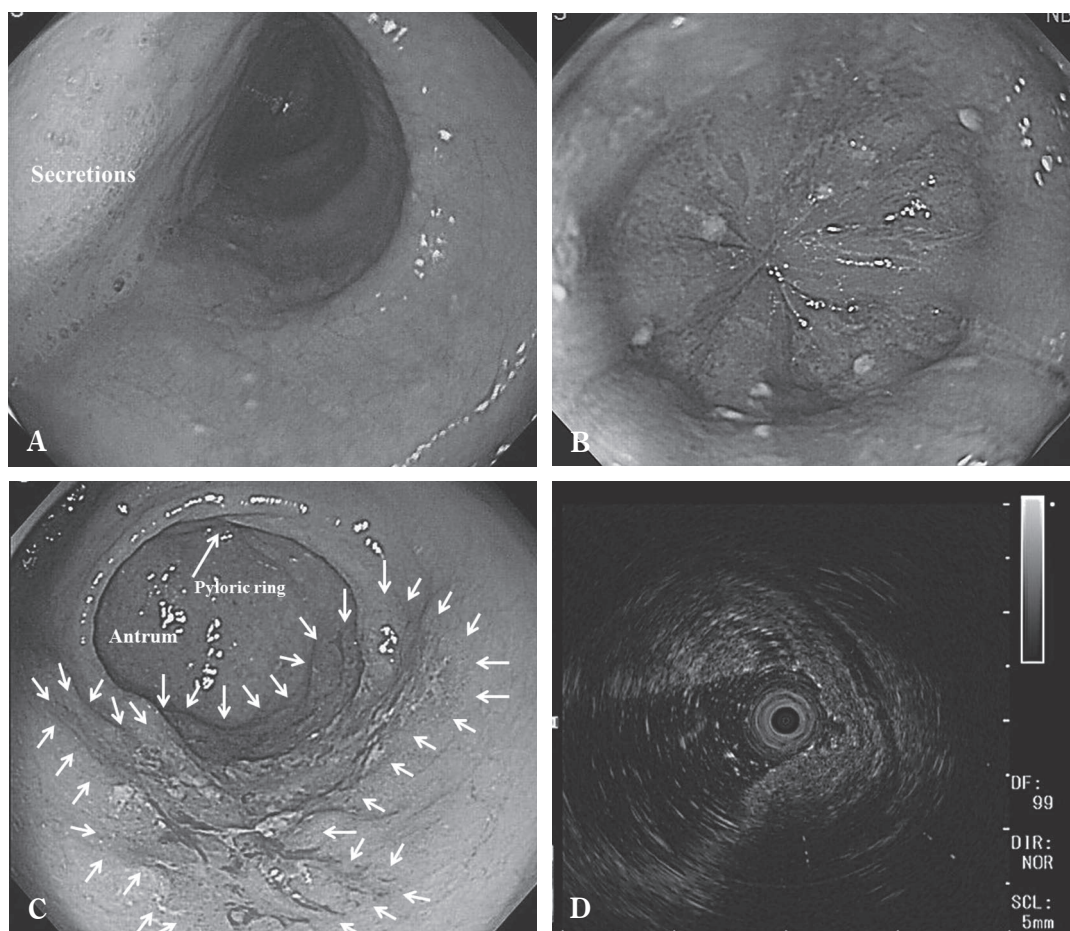


Fig. 1. Esophagogastroduodenoscopy

- A : The distal part of the esophagus was dilated and retained secretions.
- B : The esophagogastric junction was tightly closed.
- C : The tumor was in the lower third of the stomach.
- D : Endoscopic ultrasonography revealed submucosal invasion.

The gastric cancer was in the lower third of the stomach (Fig. 1C) and was found, with endoscopic ultrasonography, to have invaded the submucosal layer (Fig. 1D). Barium esophagography showed that the distal esophagus was significantly curved and that the greatest transverse diameter of the esophagus was 43 mm (Fig. 2A). Computed tomography of the chest demonstrated fluid in the esophagus. The final diagnosis was concomitant esophageal achalasia and early gastric cancer, for which LHD and LADG were planned.

The patient was placed in the supine position with the legs straddled. The cameraman (second assistant) stood between the legs, and the surgeon and the first assistant stood on the right side and left side of the patient, respectively.

A total of 5 trocars were used: two 12-mm trocars and three 5-mm trocars. First, a 12-mm trocar was inserted above the umbilicus with the open technique. Carbon dioxide pneumoperitoneum was maintained at 12 mm H₂O. Under laparoscopic observation, 4 other atraumatic trocars were placed in the upper abdomen. Before LADG was performed, LHD was performed with a procedure previously described¹. Briefly, the patient was placed in an anti-Trendelenburg position and rotated to the right under general anesthesia. The abdominal esophagus was exposed with the technique used for selective proximal vagotomy, and a 10-Fr Penrose drain was placed around the abdominal esophagus to allow safe retraction. We usually divide all the short gastric vessels to relieve the tension from the wrap, but to maintain blood flow to the remnant

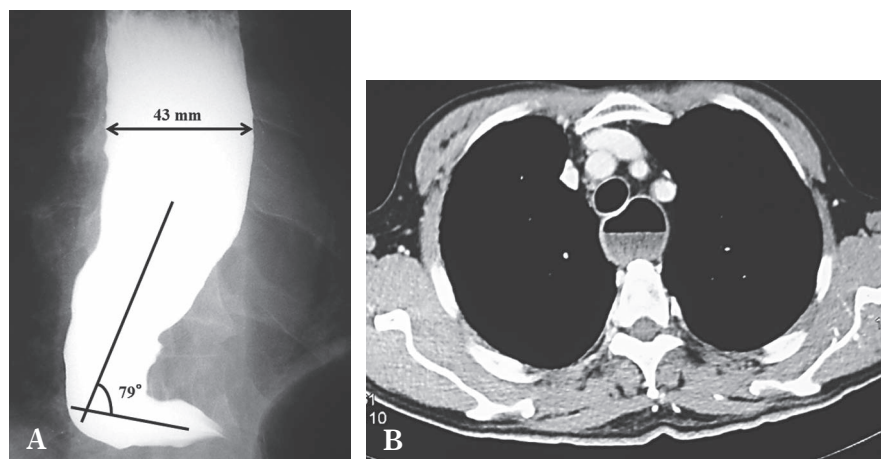


Fig. 2. A : Advanced sigmoid-type achalasia is seen at an angle of 79 degrees with a maximal transverse diameter of 43 mm. B : Computed tomography of the chest demonstrates fluid in the esophagus.

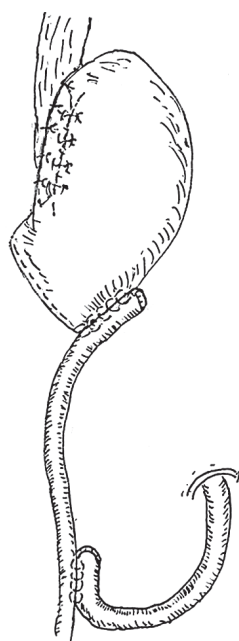


Fig. 3. Schematic view of the antireflux procedure and reconstruction of the remnant stomach.

stomach we did not do so in the present patient. Heller myotomy was performed with a 6-cm incision of the abdominal esophagus and a 2-cm incision of the gastric wall, after which a 56-Fr esophageal bougie inserted orally was passed through the area of obstruction into the stomach. During Heller myotomy, esophageal mucosal injury was confirmed and repaired laparoscopically.

After the myotomy was judged to be sufficient, Dor fundoplication was performed as an antireflux procedure (Fig. 3). Then, LADG was performed after the bougie had




Fig. 4. Moderately differentiated adenocarcinoma was seen in the pathological specimen. Cancer cells had invaded the submucosal layer (hematoxylin and eosin, $\times 40$).

been removed. The greater omentum and gastrocolic ligament were dissected laparoscopically outside the epigastric arcade toward the splenic flexure. The left gastroepiploic vein and artery were divided individually at their root. The right gastroepiploic vessels were divided at the pancreatic surface to facilitate dissection of lymph nodes in the subpyloric region. The common hepatic and splenic arteries were prepared along the upper border of the pancreas by lifting the stomach. The right gastric vein and artery were divided in the hepatoduodenal ligament. The lesser omentum was opened, and the lymph nodes around the celiac axis were dissected. The left gastric vein and artery were isolated and doubly ligated with clips at the origin of the celiac axis. The perigastric lymph nodes were dissected along the upper lesser curvature to the esophagocardiac

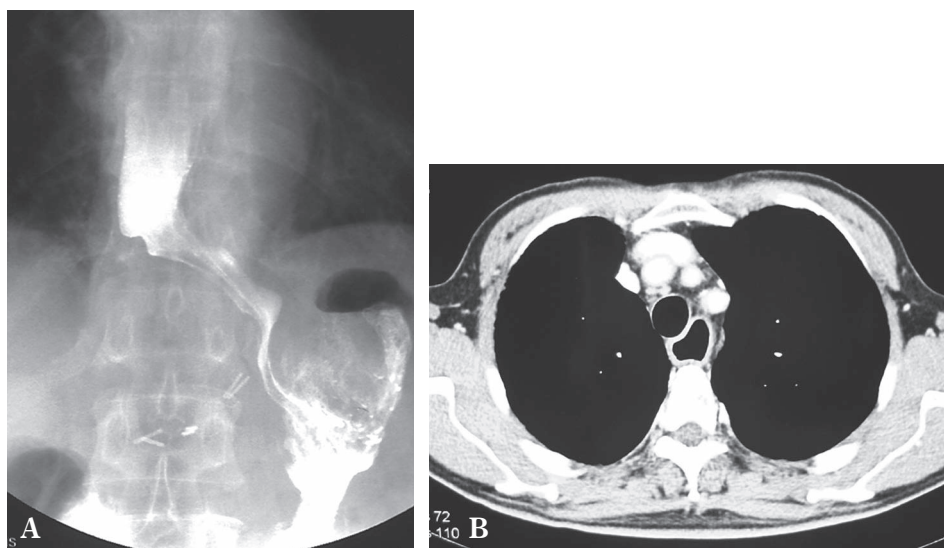


Fig. 5. Postoperative imaging studies.

A : Postoperative barium esophagogram demonstrates good passage at the esophagogastric junction.

B : Computed tomography of the chest after surgery demonstrates no fluid in the esophagus.

junction. Furthermore, lymph nodes along the left gastric artery, common hepatic artery, and celiac axis and the D1 lymph nodes were dissected².

After complete laparoscopic mobilization of the lower two-thirds of the stomach, the trocar incision in the epigastrium was extended to 5 cm vertically. The distal two-thirds of the stomach containing the cancer was resected with an autostapler. Roux-en-Y reconstruction was chosen because the remnant stomach was too small to prevent postoperative duodenogastroesophageal reflux (Fig. 3). After the remnant stomach was reconstructed, anchor stitches were placed to prevent the abdominal esophagus and fundic wrap from being dislodged into the mediastinum.

The operative time was 295 minutes, and blood loss was minimal. The histopathological diagnosis was moderately differentiated adenocarcinoma with submucosal invasion (Fig. 4). The postoperative course was unremarkable except for left shoulder pain, and the patient was discharged on postoperative day 21. The results of postoperative barium swallow examinations and computed tomography of the chest were satisfactory (Fig. 5A and 5B). Neither tumor metastasis nor recurrence has been found as of 29 months postoperatively, and dysphagia has not recurred.

DISCUSSION

The annual incidence of esophageal achalasia is ex-

tremely low at 1 case per 100,000 person, and the prevalence is 10 case per 100,000 persons^{3,4}, which may account for the absence of reports of concomitant esophageal achalasia and gastric cancer. Esophageal achalasia is rarely complicated by other diseases⁵. In fact, of the 455 patients with esophageal achalasia treated at our institution from August 1994 through December 2012, only 13 patients (2.9%) had concomitant diseases that required additional procedures. These conditions included gallstones in 4 patients, epiphrenic diverticula in 3 patients⁶, and gastric cancer, esophageal gastrointestinal stromal tumor, submucosal tumor of the stomach, lymphoma, incisional hernia, and inguinal hernia in 1 patient each. Another patient had concomitant gastric cancer but refused LHD and underwent distal partial gastrectomy alone. To our knowledge, the present case is the first in which LHD and LADG were simultaneously performed. On the other hand, we have treated 2 patients with esophageal achalasia in whom gastric cancer developed during follow-up after LHD.

Several tests are available to confirm the diagnosis of esophageal achalasia, of which radiographic studies, EGD, and esophageal manometry are the primary tools of investigation⁷. The present patient was found with a barium swallow examination to have an abnormality of the esophagus. Thereafter, EGD was performed twice to examine the esophagus, but the endoscopists could not diagnose esophageal achalasia. All endoscopic examinations

were performed by a trained surgeon or endoscopist, who found only early gastric cancer despite knowing of the esophageal abnormality beforehand. Endoscopy is the most valid and reliable methods of assessing the alimentary tract because a biopsy specimen can be taken from any area that appears cancerous. Howard et al have reported that 44% of patients with esophageal achalasia have normal EGD findings, whereas other patients might show esophageal dilation and retention of food or secretions⁸. Therefore, barium swallow seems to be the most reliable examination for diagnosing esophageal achalasia.

Authors have no conflict of interest.

REFERENCES

1. Omura N, Kashiwagi H, Tsuboi K, Ishibashi Y, Kawasaki N, Yano F, et al. Therapeutic effects of a laparoscopic Heller myotomy and Dor fundoplication on the chest pain associated with achalasia. *Surg Today*. 2006 ; 36 : 235-40.
2. Japanese Gastric Cancer Association. Japanese classification of gastric carcinoma. Tokyo : Kanehara ; 2010.
3. Omura N, Kashiwagi H, Yano F, Tsuboi K, Yanaga K. Reoperations for esophageal achalasia. *Surg Today*. 2012 ; 42 : 1078-81.
4. Francis DL, Katzka DA. Achalasia : update on the disease and its treatment. *Gastroenterology*. 2010 ; 139 : 369-74.
5. Emami MH, Raisi M, Amini J, Daghighzadeh H. Achalasia and thyroid disease. *World J Gastroenterol*. 2007 ; 13 : 594-9.
6. Hoshino M, Omura N, Yano F, Tsuboi K, Matsumoto A, Kashiwagi H, et al. Laparoscopic Heller myotomy and Dor fundoplication combined with laparoscopic diverticular introversion suturing for achalasia complicated by epiphrenic diverticulum : report of a case. *Surg Today*. 2010 ; 40 : 158-61.
7. Eckardt AJ, Eckardt VF. Current clinical approach to achalasia. *World J Gastroenterol*. 2009 ; 15 : 3969-75.
8. Howard PJ, Maher L, Pryde A, Cameron EW, Heading RC. Five years prospective study of the incidence, clinical features, and diagnosis of achalasia in Edinburgh. *Gut*. 1992 ; 33 : 1011-5.