

## Embolotherapy of Pulmonary Arteriovenous Malformation Using Detachable Coils

Kanichiro SHIMIZU, Shinji YAMAZOE, Kotaro OUCHI, Takuji MOGAMI, and Junta HARADA

*Department of Radiology, The Jikei University Kashiwa Hospital*

### ABSTRACT

The purpose of this study was to evaluate the long-term safety and efficacy of venous sac and feeding artery embolization with detachable coils for treating pulmonary arteriovenous malformations (PAVMs). From 1998 through 2011, we treated 18 PAVMs in 11 patients (4 men and 7 women ; mean age, 52.0 years) and embolized all venous sacs with detachable coils while controlling blood flow with a balloon catheter and afterward deploying fibered platinum coils or fibered detachable coils in the feeding arteries. We then retrospectively assessed the safety and efficacy of this treatment over time in all patients. We successfully embolized PAVMs without serious complications. In 9 of 11 patients, the mean PaO<sub>2</sub> increased from 73.8 mmHg before treatment to 91.7 mmHg after treatment ( $P=0.005$ ). In 8 of 11 patients, the mean shunt ratio on technetium-macroaggregated albumin scintigraphy improved from 16.0% before treatment to 7.0% after treatment ( $P<0.05$ ). No patient had symptoms of recurrence during a mean follow-up period of 51.8 months. Long-term follow-up showed that the treatment of PAVMs with venous sac embolization using detachable coils followed by feeding artery embolization is safe and effective and prevents reperfusion.

(Jikeikai Med J 2012 ; 59 : 37-43)

Key words : pulmonary arteriovenous malformation, embolotherapy, long-term outcome, venous sac embolization, detachable coil

### INTRODUCTION

Pulmonary arteriovenous malformations (PAVMs) are direct communications between pulmonary arteries and veins with no normal capillary bed<sup>1,2</sup>. Of patients with PAVMs, about 70% have hereditary hemorrhagic telangiectasia (HHT) in Western countries. The rate is lower in Asians than European people. And about 30% of people with HHT have PAVM in Asian countries. Symptoms of PAVMs depend on the size and number of lesions<sup>1-4</sup>. Typical manifestations are dyspnea caused by right-to-left shunt and neurologic disorders caused by paradoxical embolism. Approximately 18% of patients with PAVM experience

stroke, and 9% experience cerebral abscess<sup>3,4</sup>.

Surgical resection has long been the standard treatment for PAVMs. Minor lung resection may be curative for a PAVM that is solitary, small, and peripheral. However, invasive therapy, such as lobectomy and segmentectomy, is often needed depending on the size, number, and location of lesions<sup>5</sup>.

Portmann first reported embolotherapy with metallic coils for PAVMs in 1977<sup>6</sup>. Use of stainless steel coils or detachable balloons has been reported since the early 1980s<sup>7,8</sup>. Endovascular therapy is the current method of choice for treating PAVMs<sup>3,4</sup>. The most serious complication of this procedure is infarction of various organs, including stroke

---

Received for publication, August 30, 2012

清水勸一朗, 山添 真治, 大内厚太郎, 最上 拓児, 原田 潤太

Mailing address : Kanichiro SHIMIZU, Department of Radiology, The Jikei University Kashiwa Hospital, 163-1 Kashiwashita, Kashiwa, Chiba 277-8567, Japan.

E-mail : shimikan@jikei.ac.jp

Table 1. Clinical characteristics of patients with PAVM

Patient	Age (years)/Sex	Symptom	Number of PAVMs	PaO <sub>2</sub> (mm Hg)	Shunt fraction (%)
1	65/F	Cerebral infarction	5	62.6	30.0
2	65/F	Cerebral infarction	3	72.1	13.7
3	60/M	Cerebral infarction	1	85.6	15.0
4	57/F	Dyspnea on exertion	1	72.1	not available
5	61/F	Dyspnea on exertion	1	69.7	13.4
6	15/M	Dyspnea on exertion	1	76.9	32.1
7	34/M	No symptom	1	70.9	11.6
8	48/F	No symptom, HHT	1	96.0	7.3
9	37/M	Brain abscess	4	49.6	15.1
10	51/F	No symptom	1	84.6	9.7
11	77/F	No symptom	1	83.5	8.3

caused by systemic migration of embolic coils via the right-to-left shunt<sup>9,10</sup>. Unintentional embolization of the proximal normal branch can also occur, and reperfusion occurs in as many as 17% of PAVMs after initially successful treatment<sup>11,12</sup>. To avoid these complications and to reduce the risk of reperfusion, we performed venous sac embolization with detachable coils while controlling blood flow with a balloon catheter and then embolized the feeding artery with fibered platinum coils or fibered detachable coils. To assess the long-term safety and efficacy of this treatment, we evaluated clinical variables, including decreased PaO<sub>2</sub> or SpO<sub>2</sub> and findings of 3-dimensional (3D) computed tomography (CT) and <sup>99m</sup>Tc-macroaggregated albumin (MAA) scintigraphy, in patients in follow-up examinations at least 9 months after their initially successful treatment with this routine procedure.

## MATERIALS AND METHODS

### Patients

From 1998 through 2011, we treated 18 PAVMs in 11 patients (4 men and 7 women; age range, 15 to 77 years, mean age, 52.0 years). The PAVMs had been detected with examinations for cerebral infarction (3 patients), dyspnea on exertion (3 patients), and cerebral abscess (1 patient) and had been incidentally detected with chest radiography or CT in 4 asymptomatic patients, 1 of whom had HHT.

None of the patients had causes of dyspnea on exertion or abnormality of PaO<sub>2</sub> other than PAVM on chest radiography or CT, and none had other causes of right-to-left shunt, such as liver cirrhosis. Pulmonary function testing was

not performed.

We confirmed all diagnoses of PAVM with 3D contrast-enhanced CT and performed embolotherapy when the diameter of feeding arteries exceeded 3 mm<sup>8,13,14</sup>. Three patients were treated for multiple PAVMs, and 1 of these patients had a PAVM of complex type. Each of the other 8 patients was treated for a single lesion of simple type<sup>15-17</sup>.

Before and after treatment, we measured PaO<sub>2</sub> and

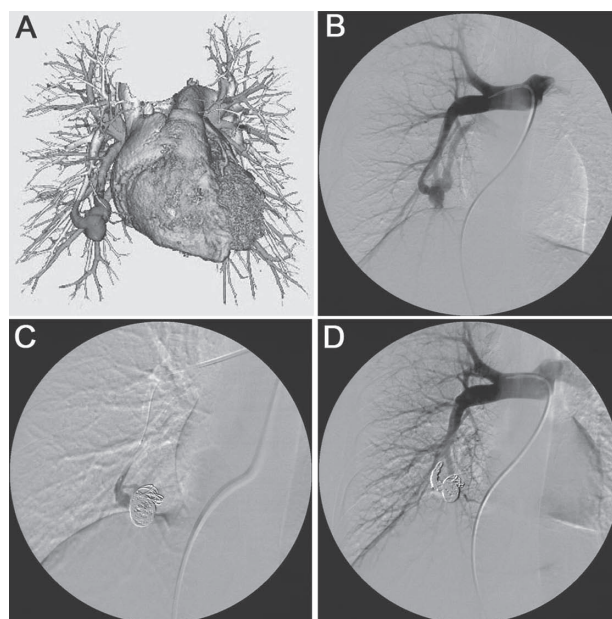


Fig. 1. Embolization of a PAVM with a large venous sac and drainage vein of a 34-year-old man. A, B. A PAVM with a venous sac 26 mm in diameter is seen in the right S8 on 3D CT and right pulmonary angiography. C. Embolization of the venous sac with GDCs under flow control with a balloon catheter avoided coil migration via the right-left shunt. D. Embolization of the venous sac and feeding artery was confirmed with pulmonary angiography after the procedure.

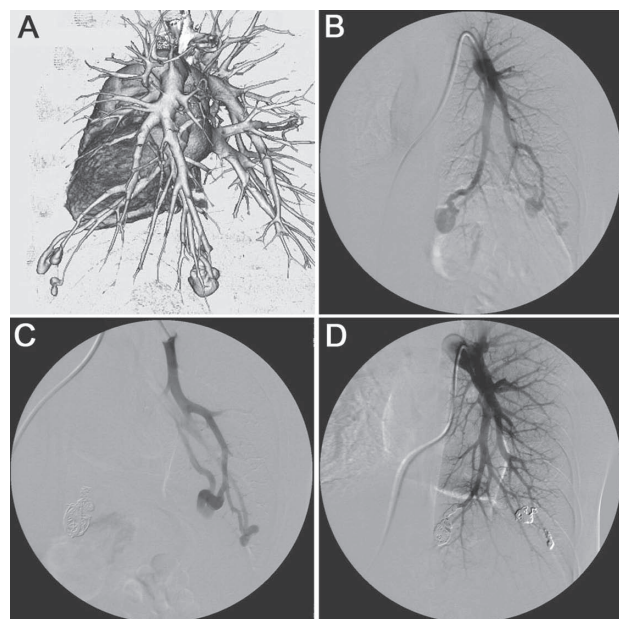


Fig. 2. Embolization of a PAVM with a small, tortuous feeding artery in a 37-year-old man. A, B. Three PAMVs were confirmed with 3D CT and left pulmonary angiography. B. Feeding arteries were small and tortuous on selective angiography of the left A10. C. We successfully inserted a 2.5-Fr microcatheter into the venous sac and embolized the venous sac and feeding arteries.

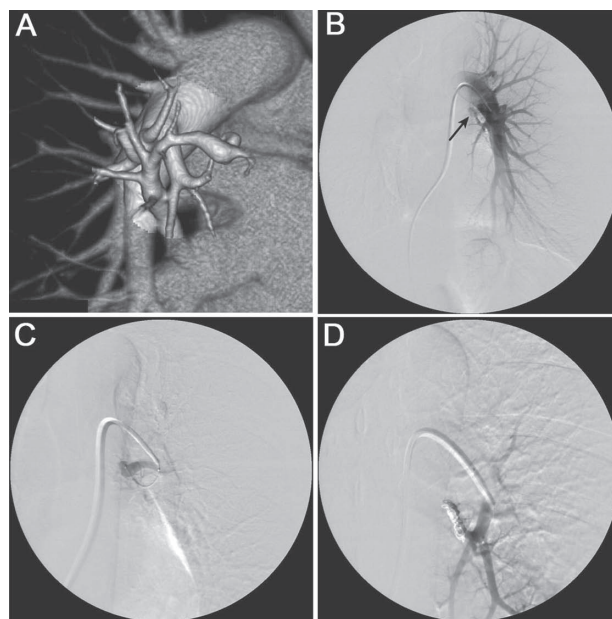


Fig. 3. Embolization of a PAVM with a short feeding artery. Left pulmonary angiogram of a 48-year-old woman. A, B. A PAMV with a short feeding artery (arrow) was observed in the right S6 with 3D CT and left pulmonary angiography. C. We successfully inserted a 2.5-Fr microcatheter into the venous sac. D. We embolized the venous sac and feeding artery with detachable coils and fibered platinum coils and avoided embolization of the proximal normal branch.

used  $^{99m}\text{Tc}$ -MAA scintigraphy to measure the shunt fraction. We calculated the right-to-left shunt fraction with the modified Gates method<sup>10,18-21</sup> and the percentage of the  $^{99m}\text{Tc}$ -MAA shunt fraction as:  $(\text{total body count} - \text{total lung counts}) / \text{total body counts} \times 100 = \text{percent right-to-left shunt}^{10,18-21}$ . The data were analyzed with the Mann-Whitney U-test. Table 1 shows the characteristics of each patient.

#### Embolization technique

After applying local anesthesia around the right femoral vein, we inserted a 7-Fr 25-cm sheath using Seldinger's method and administered a single intravenous dose (3,000 units) of heparin and then 1,000 units per hour during the procedure. We performed initial pulmonary arteriography by digital subtraction angiography using a 7-Fr Berman angiographic balloon catheter (Arrow International, Inc., Reading, PA, USA). The images were used to measure the size of the feeding artery and venous sac and to analyze the angioarchitecture of the PAVMs. We then exchanged the 7-Fr Berman angiography catheter for a 7-Fr balloon

wedge-pressure catheter (Arrow International, Inc.), through which we advanced a 2.5-Fr microcatheter coaxially into the venous sac of the PAVM. We first embolized the venous sac with Guglielmi detachable coils (GDCs) (Boston Scientific Corp., Natick, MA, USA, until 2010, Stryker Neurovascular, Fremont, CA, USA, since 2011) or interlocking detachable coils (IDCs) (Boston Scientific Corp.) to make a scaffold to prevent coil migration and then deployed fibered platinum GDC Vortx (Boston Scientific Corp. until 2010, Stryker Neurovascular since 2011), or Interlock (Boston Scientific Corp.) in the feeding artery (Fig. 1, 2). We used GDC Vortx or Interlock to avoid embolizing the proximal normal branch, especially when the feeding artery was short (Fig. 3).

#### Definition of success

The PAVMs were embolized until completely occluded, as indicated by disappearance of the drainage vein from the venous sac, except backflow from normal pulmonary veins, on pulmonary angiography during the procedure. Clinical success was defined as the disappearance of symptoms, the

absence of new symptoms, and an increased PaO<sub>2</sub> or a decreased shunt fraction on <sup>99m</sup>Tc-MAA scintigraphy.

#### Follow-up

If patients had symptoms, decreased PaO<sub>2</sub> or SpO<sub>2</sub>, or an increased shunt fraction on <sup>99m</sup>Tc-MAA scintigraphy, we suspected recurrence or the development of a new lesion and confirmed our suspicion with 3D CT. Following previous reports that described long-term outcomes after embolotherapy with minimum follow-up of 9 months<sup>22-25</sup>, we defined long-term as 9 months or more and investigated patient outcomes thereafter.

### RESULTS

Embolotherapy was successful in all patients, with no serious complications, such as systemic migration of coils. One patient with multiple lesions underwent embolotherapy 3 times. The only minor complication was transient hemisensory disturbance in 1 patient which resolved spontaneously. Embolization of the proximal normal branch did not occur in any case.

We confirmed the resolution of symptoms in the 3 patients who had dyspnea on exertion.

We measured PaO<sub>2</sub> in 10 of 11 patients; postoperative PaO<sub>2</sub> was not measured in 1 patient. We confirmed an increase in PaO<sub>2</sub> in 9 of 10 patients and improved shunt fraction in the tenth patient. The mean PaO<sub>2</sub> increased from 73.8 mm Hg (range, 49.6 to 84.6 mm Hg) before treatment to 91.7 mm Hg (range, 82.2 to 108.4 mm Hg) after treatment ( $P = 0.005$ ) (Fig. 4).

The mean right-to-left shunt fraction on <sup>99m</sup>Tc-MAA scintigraphy decreased from 16.0% (range, 7.3% to 30.0%) before treatment to 7.0% (range, 0% to 12.2%) after treatment ( $P < 0.05$ ) in 8 of 11 patients; 1 patient did not undergo scintigraphy, and the postoperative fraction was not measured in the other 2 patients (Fig. 5).

No patient showed symptoms of recurrence or the development of new lesions during the mean follow-up period of 51.8 months (range, 9-141 months). In 1 patient without HHT (patient 7), a small PAVM that had a feeding artery smaller than 2 mm in diameter was not treated. The absence of change in this lesion had been confirmed with follow-up 3D CT. All patients were followed up for more than 9 months, and, as of this writing, we continue to follow

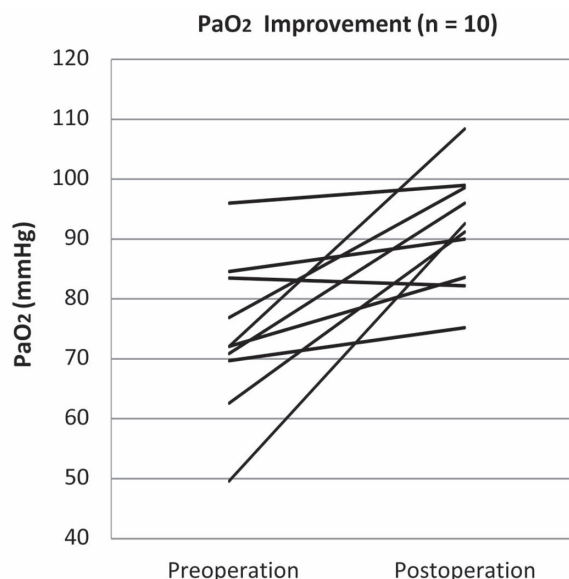


Fig. 4. The PaO<sub>2</sub> increased in 10 patients and was not measured postoperatively in 1 patient.

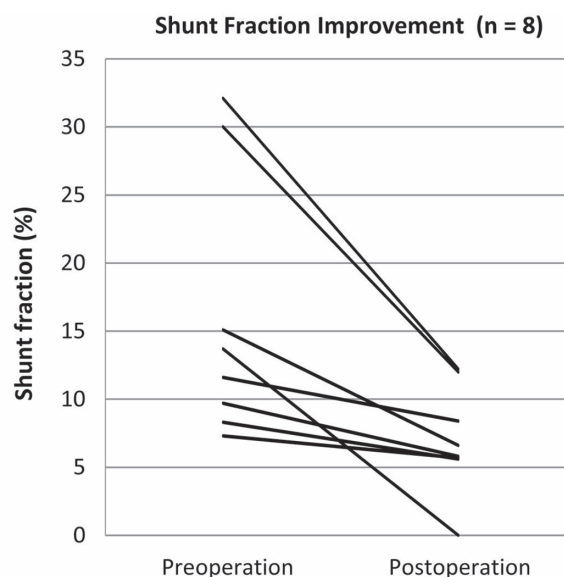


Fig. 5. The shunt fraction decreased on <sup>99m</sup>Tc-MAA scintigraphy in 8 patients. One patient did not undergo scintigraphy, and the postoperative shunt fraction was not measured in 2 patients.

up 6 patients; 1 patient died of uterine cancer.

### DISCUSSION

#### 1. Indications for embolotherapy for PAVMs

We performed embolotherapy when the diameter of the feeding artery exceeded 3 mm, despite a recent report

describing paradoxical embolization as independent of the diameter of the feeding artery<sup>8,13,14,26</sup>. Although the 2009 treatment guidelines for HHT support the treatment of a PAVM with a feeding artery exceeding 2 mm in diameter<sup>27</sup>, most reports describe this treatment as appropriate, specifically for patients with HHT. Only 1 of our patients had HHT (patient 8). Indications for treatment of patients without HHT remain unclear. In 1 patient without HHT (patient 7), preoperative CT pulmonary angiography showed a small ipsilateral PAVM that had not been apparent on unilateral pulmonary angiography during the procedure. Remy and colleagues have reported detection of 38.5% of PAVMs with only CT using contrast enhancement; pulmonary angiography failed to demonstrate lesions smaller than 5 mm<sup>2</sup>. In our series some small PAVMs detected with preoperative CT could not be detected with pulmonary angiography; as a result, they could not be treated. However, we believe that we should treat small PAVMs that have feeding arteries smaller than 2 mm in diameter and that can be observed on pulmonary angiography.

## 2. *Improvement of symptoms and PaO<sub>2</sub>*

Endovascular therapy is the current treatment of choice for PAVMs<sup>3,4</sup>, and venous sac embolization is reportedly effective<sup>28,29</sup>. In all our study patients, we confirmed the successful embolization of PAVMs on the basis of the disappearance of the venous sac and drainage vessels during the procedure and the resolution of symptoms in symptomatic patients. We measured PaO<sub>2</sub> in 10 of 11 patients, observed an increase in PaO<sub>2</sub> in 9 of the 10, and confirmed a decreased shunt fraction in the patient in tenth patient. We did not observe recurrence of symptoms, including cerebral infarction and brain abscess, during follow-up. Our findings are similar to those of previous reports of venous sac embolization<sup>28,29</sup>.

## 3. *Improved shunt fraction using <sup>99m</sup>Tc-MAA*

We confirmed improved shunt fraction in all patients who underwent scintigraphy before and after treatment. To our knowledge, no previous study has evaluated shunt fraction with <sup>99m</sup>Tc-MAA or has focused on assessing outcomes of venous sac embolization. Two-thirds of the mechanism of reperfusion is the recanalization of the initially occluded artery; the other third is the development of accessory vessels or bronchial arteries<sup>11,12,30</sup>, which are

easily detected with CT. However, detachable coils in the venous sac create metallic artifacts, disturb sac decompression, and make detecting recanalization on CT more difficult. Because <sup>99m</sup>Tc-MAA scintigraphy is not affected by the condition of the venous sac, it can help detect reperfusion<sup>10,18-21</sup>.

## 4. *Venous sac embolization*

The most serious complication of embolotherapy of a PAVM is systemic migration of embolic coils<sup>9,10</sup>, which occurs in 0.7% to 3.0% of procedures<sup>8,9,13,31</sup>. Use of detachable coils in a venous sac is a reliable means of preventing systemic migration of coils deployed in feeding arteries. Controlling blood flow with a balloon catheter permits safe deployment of detachable coils in the venous sac. Recently some authors have described embolotherapy with Amplatzer vascular plugs (AVPs). Systemic migration of AVPs has not been reported; however, deployment of AVP distal to feeding arteries is often difficult, especially when the feeding artery is small and tortuous<sup>32,33</sup>. Regardless of the shape or diameter of the feeding arteries, we successfully advanced the microcatheter into all venous sacs.

The numbers of detachable coils in the venous sac should be reduced, because of problems of procedure time, radiation exposure, and cost. It just makes a scaffold to prevent migration of coil, although the coils in feeding arteries are strongly pushed out, but dense coil packing in the venous sac is not needed.

## 5. *Complications*

One of our patients had the minor complication of transient hemisensory disturbance. Some authors have feared that thrombi on coils would migrate into the systemic circulation and cause cerebral infarction<sup>10,34</sup>. We believe this was the case in our patient with transient hemisensory disturbance, which resolved spontaneously. Our patients had no other minor complications, including self-limiting pleurisy<sup>27</sup>. We did not observe major complications. Prompt use of intravenous heparin is needed in this procedure. Coley and Jackson<sup>34</sup> and Takahashi et al.<sup>29</sup> have described the risk of rupture of the venous sac during embolization. In our experience, we find the variety of shapes and the softness of GDCs make them superior to IDCs for safe deployment to prevent rupture of the venous sac.

## 6. *Avoiding embolization of the proximal normal branch and reperfusion*

Reperfusion occurs in as many as 17% of PAVMs after initially successful treatment using coil. When embolization with both coils and AVPs is performed, the rate of recanalization has been reported to be 5%<sup>35,36</sup>. Milic et al. have described a significant association between recanalization and proximal placement of coils within the feeding artery<sup>12</sup>. More-distal and tighter placement of appropriately sized coils in the feeding artery is needed to avoid recanalization and embolization of the proximal normal branch. The strong thrombogenicity of fibered GDCs or interlocking coils enables the use of shorter coils to embolize the feeding artery, which is especially useful when feeding arteries are short to avoid embolization of the proximal normal branches. To our knowledge, the use of fibered detectable coils to embolize feeding arteries has not been reported.

## 7. *Long-term follow-up*

We observed no recurrence of symptoms in any patient during a mean follow-up period of 51.8 months (range, 9 to 141 months). Although several reports of long-term follow-up of large groups of patients have described reperfusion<sup>22,31,37</sup>, to our knowledge, there have been no reports of long-term follow-up after venous sac embolization. During a follow-up period similar to that of earlier reports, we did not observe reperfusion.

Using detachable coils to embolize the venous sac is a reliable means of preventing systemic migration of coils, and the tight deployment of appropriately sized coils in the feeding artery avoids embolization of the proximal normal branch. Long-term follow-up confirmed that this procedure reduces the risks of complications and recanalization.

Authors have no conflict of interest.

## REFERENCES

- White RI Jr, Pollak JS, Wirth JA. Pulmonary arteriovenous malformations: diagnosis and transcatheter embolotherapy. *J Vasc Interv Radiol.* 1996; 7: 787-804.
- Remy J, Remy-Jardin M, Wattine L, Deffontaines C. Pulmonary arteriovenous malformations: evaluation with CT of the chest before and after treatment. *Radiology.* 1992; 182: 809-16.
- Gossage JR, Kanj G. Pulmonary arteriovenous malformations. A state of the art review. *Am J Respir Crit Care Med.* 1998; 158: 643-61.
- Iqbal M, Rossoff LJ, Steinberg HN, Marzouk KA, Siegel DN. Pulmonary arteriovenous malformations: a clinical review. *Postgrad Med J.* 2000; 76: 390-4.
- Puskas JD, Allen MS, Moncure AC, Wain JC Jr, Hilgenberg AD, Wright C, et al. Pulmonary arteriovenous malformations: therapeutic options. *Ann Thorac Surg.* 1993; 56: 253-7.
- Portmann W. Therapeutic embolization of arteriovenous pulmonary fistula by catheter technique. In: Eklöf O, editor. *Current Concepts in Pediatric Radiology.* Berlin: Springer; 1977. p. 23-31.
- Terry PB, Barth KH, Kaufman SL, White RI Jr. Balloon embolization for treatment of pulmonary arteriovenous fistulas. *N Engl J Med.* 1980; 302: 1189-90.
- White RI, Lynch-Nyhan A, Terry P, Buescher PC, Farnlett EJ, Charnas L, et al. Pulmonary arteriovenous malformation: techniques and long-term outcome of embolotherapy. *Radiology.* 1988; 169: 663-9.
- Haitjema TJ, Overtom TT, Westermann CJ, Lammers JW. Embolization of pulmonary arteriovenous malformations: results and follow up in 32 patients. *Thorax.* 1995; 50: 719-23.
- Gupta P, Mordin C, Curtis J, Hughes JM, Shovlin CL, Jackson JE. Pulmonary arteriovenous malformations: effect of embolization on right-to-left shunt, hypoxemia, and exercise tolerance in 66 patients. *AJR Am J Roentgenol.* 2002; 179: 347-55.
- Pollak JS, Saluja S, Thabet A, Henderson KJ, Denbow N, White RI Jr. Clinical and anatomic outcomes after embolotherapy of pulmonary arteriovenous malformations. *J Vasc Interv Radiol.* 2006; 17: 35-44.
- Milic A, Chan RP, Cohen JH, Faughnan ME. Reperfusion of pulmonary arteriovenous malformation after embolotherapy. *J Vasc Interv Radiol.* 2005; 16: 1675-83.
- Dutton JA, Jackson JE, Hughes JM, Whyte MK, Peters AM, Ussov W, et al. Pulmonary arteriovenous malformations: results of treatment with coil embolization in 53 patients. *AJR Am J Roentgenol.* 1995; 165: 1119-25.
- Rosenblatt M, Pollak J, Fayad P, Eggin T, White RI Jr. Pulmonary arteriovenous malformations: what size should be treated to prevent embolic stroke? *Radiology.* 1992 (abstr); 185(P): 134.
- White RI, Mitchell SE, Barth KH, Kaufman SL, Kadir S, Chang R, et al. Angioarchitecture of pulmonary arteriovenous malformations: an important consideration before embolotherapy. *AJR Am J Roentgenol.* 1983; 140: 681-8.
- Hofmann LV, Kuszyk BS, Mitchell SE, Horton KM, Fishman EK. Angioarchitecture of pulmonary arteriovenous malformations: characterization using volume-rendered 3-D CT angiography. *Cardiovasc Intervent Radiol.* 2000; 23: 165-70.
- Remy J, Remy-Jardin M, Giraud F, Wattinne L. Angioarchitecture of pulmonary arteriovenous malformations: clinical utility of three-dimensional helical CT. *Radiology.* 1994;

- 191 : 657-64.
18. Gates GF, Orme HW, Dore EK. Cardiac shunt assessment in children with macroaggregated albumin technetium-99m. *Radiology*. 1974 ; 112 : 649-53.
  19. Sugiyama M, Sakahara H, Igarashi T, Takahashi M. Scintigraphic evaluation of small pulmonary right-to-left shunt and therapeutic effect in pulmonary arteriovenous malformation. *Clin Nuc Med*. 2001 ; 26 : 757-60.
  20. Chilvers ER, Peter AM, George P, Hughes JM, Allison DJ. Quantification of right to left shunt through pulmonary arteriovenous malformations using 99Tcm albumin microspheres. *Clin Radiol*. 1988 ; 39 : 611-4.
  21. Whyte MK, Peters AM, Hughes JM, Henderson BL, Bellingan GJ, Jackson JE, et al. Quantification of right to left shunt at rest and during exercise in patients with pulmonary arteriovenous malformations. *Thorax*. 1992 ; 47 : 790-6.
  22. Brillet PY, Dumont P, Bouaziz N, Duhamel A, Laurent F, Remy J, et al. Pulmonary arteriovenous malformation treated with embolotherapy : systemic collateral supply at multi-detector CT angiography after 2-20-year follow-up. *Radiology*. 2007 ; 242 : 267-76.
  23. Mager JJ, Overtom TT, Blauw H, Lammers JW, Westermann CJ. Embolotherapy of pulmonary arteriovenous malformations : long-term results in 112 patients. *J Vasc Interv Radiol*. 2004 ; 15 : 451-6.
  24. Andersen PE, Kjeldsen AD. Clinical and radiological long-term follow-up after embolization of pulmonary arteriovenous malformations. *Cardiovasc Intervent Radiol*. 2006 ; 29 : 70-4.
  25. Remy-Jardin M, Dumont P, Brillet PY, Dupuis P, Duhamel A, Remy J. Pulmonary arteriovenous malformations treated with embolotherapy : helical CT evaluation of long-term effectiveness after 2-21-year follow-up. *Radiology*. 2006 ; 239 : 576-85.
  26. Shovin CL, Jackson JE, Bamford KB, Jenkins IH, Benjamin AR, Ramadan H, et al. Primary determinants of ischaemic stroke/brain abscess risks are independent of severity of pulmonary arteriovenous malformations in hereditary haemorrhagic telangiectasia. *Thorax*. 2008 ; 63 : 259-66.
  27. Faughnan ME, Palda VA, Garcia-Tsao G, Geisthoff UW, McDonald J, Proctor DD, et al. International guidelines for the diagnosis and management of hereditary haemorrhagic telangiectasia. *J Med Genet*. 2011 ; 48 : 73-87.
  28. Dinkel HP, Triller J. Pulmonary arteriovenous malformations : embolotherapy with superselective coaxial catheter placement and filling of venous sac with Guglielmi detachable coils. *Radiology*. 2002 ; 223 : 709-14.
  29. Takahashi K, Tanimura K, Honda M, Kikuno M, Toei H, Hyodoh H, et al. Venous sac embolization of pulmonary arteriovenous malformation : preliminary experience using interlocking detachable coils. *Cardiovasc Intervent Radiol*. 1999 ; 22 : 210-3.
  30. Sagara K, Miyazono N, Inoue H, Ueno K, Nishida H, Nakajo M. Recanalization after coil embolotherapy of pulmonary arteriovenous malformations : study of long-term outcome and mechanism for recanalization. *AJR Am J Roentgenol*. 1998 ; 170 : 727-30.
  31. Lee DW, White RI Jr, Egglin TK, Pollak JS, Fayad PB, Wirth JA, et al. Embolotherapy of large pulmonary arteriovenous malformations : long-term results. *Ann Thorac Surg*. 1997 ; 64 : 930-9.
  32. Letourneau-Guillon L, Faughnan ME, Soulez MF, Oliva VL, Boucher LM, Dubois J, et al. Embolization of pulmonary arteriovenous malformations with amplatzer vascular plugs : safety and midterm effectiveness. *J Vasc Interv Radiol*. 2010 ; 21 : 649-56.
  33. Trerotola SO, Pyeritz RE. PAVM embolization : an update. *AJR Am J Roentgenol*. 2010 ; 195 : 837-45.
  34. Coley SC, Jackson JE. Venous sac embolization of pulmonary arteriovenous malformation in two patients. *AJR Am J Roentgenol*. 1996 ; 167 : 452-4.
  35. Hundt W, Kalinowski M, Kiessling A, Heverhagen JT, Eivazi B, Werner J, et al. Novel approach to complex pulmonary arteriovenous malformation embolization using detachable coils and Amplatzer vascular plugs. *Eur J Radiol*. 2012 ; 81 : 732-8.
  36. Trerotola SO, Pyeritz RE. Does use of coils in addition to Amplatzer vascular plugs prevent recanalization ? *AJR Am J Roentgenol*. 2010 ; 195 : 766-71.
  37. Ando K, Mochizuki A, Kurimoto N, Yokote K, Nakajima Y, Osada H, et al. Coil embolization for pulmonary arteriovenous malformation as an organ-sparing therapy : outcome of long-term follow up. *Ann Thorac Cardiovasc Surg*. 2011 ; 17 : 118-23.