

Case Report

Solitary Fibrous Tumor Arising from Periosteum in the Thoracic Spine

Shigeru SOSHI¹, Takeshi INOUE¹, Yoshikuni KIDA¹, Miki OZAWA¹,
Keishi MARUMO¹, Kunihiko FUKUDA², and Takashi NIKAI³

¹*Department of Orthopaedic Surgery, The Jikei University School of Medicine*

²*Department of Radiology, The Jikei University School of Medicine*

³*Division of Pathology, Kosei General Hospital*

ABSTRACT

We report a dumbbell-type solitary fibrous tumor of the thoracic spine. The patient complained of hypoesthesia and numbness in the distal area of the Th10 dermatome and muscle weakness in both lower limbs. Magnetic resonance (MR) revealed a well-circumscribed extradural mass at the T2-4 level which was hypointense on both T1- and T2-weighted images. The tumor showed heterogeneous enhancement on T1-weighted MR images after injection of gadolinium-diethylenetriamine pentaacetic acid and extended paravertebrally through the neural foramen with a dumbbell-type appearance on axial images. Computed tomography showed no calcification within the tumor. The tumor was extremely firm and was tightly adherent to the posterior vertebral wall. We speculated that the tumor had arisen from the periosteum of the vertebrae or the posterior longitudinal ligament. Two years after surgery, MR demonstrated no signs of recurrent tumor. Solitary fibrous tumor, especially fibrous meningioma and hemangiopericytoma, should be included in the differential diagnosis of any intraspinal tumor. Immunohistochemical staining is useful for distinguishing a solitary fibrous tumor from other tumors. On MR imaging with T2-weighted sequences, low-intensity signals without calcification is suggestive of a solitary fibrous tumor. The recommended treatment is gross total resection because the natural history of solitary fibrous tumor is unknown.

(Jikeikai Med J 2011 ; 58 : 63-7)

Key words : CD34, magnetic resonance imaging, solitary fibrous tumor, thoracic spine, periosteum

INTRODUCTION

The first report of solitary fibrous tumor (SFT) as a localized form of mesothelioma involving the pleura was by Klemperer and Rabin in 1931¹. Subsequently reported SFTs have been predominantly from serosal sites, especially the pleura. Such tumors are now thought to arise from submesothelial mesenchymal cells, and the increasing awareness of SFTs has led to their being recognized in oth-

er extrathoracic and nonserosal sites, including soft tissues, the upper respiratory tract, the peritoneum and retroperitoneum, the periosteum, and the extra-axial cranial and paracranial compartments²⁻⁵. The spine, however, remains an unusual site of occurrence. We report a SFT of the thoracic spinal region which was attached to the vertebral posterior wall with an extension into the extraforaminal space, forming a dumbbell-shaped mass.

Received for publication, January 11, 2011

曾雌 茂, 井上 雄, 木田 吉城, 小澤 美貴, 丸毛 啓史, 福田 国彦, 二階堂 孝

Mailing address : Shigeru SOSHI, Department of Orthopaedic Surgery, The Jikei University School of Medicine, 3-25-8 Nishi-shimbashi, Minato-ku, Tokyo 105-8461, Japan.

E-mail : s-soshi@jikei.ac.jp

Case Report

History

The patient was a 53-year-old woman who presented with a 2- to 3-month history of hypoesthesia and numbness in the distal area of the Th10 dermatome. Initially the patient was thought to have a herniated intervertebral disc and was treated with an epidural block at another hospital before presenting to our institution. During the weeks before presentation at our hospital, the patient experienced muscle weakness in both lower limbs and gait disturbances and was using a wheelchair when admitted to our hospital. Past medical history was noncontributory.

Physical examination

Muscle weakness (grade 3/5) was found in both lower limbs, more pronounced proximally on the right, and the patient could not walk. Deep tendon reflexes in the lower limbs were decreased, and the Babinski sign and ankle clonus were absent on both sides. Vibration and light touch below T12 were decreased.

Image findings

Magnetic resonance (MR) revealed a well-circumscribed extradural mass at the T2-4 level which was hypointense on both T1- and T2-weighted images. The tumor demonstrated heterogeneous enhancement on T1-weighted images after injection of gadolinium-diethylenetriamine pentaacetic acid (Gd-DTPA) and extended paravertebrally through the neural foramen with a dumbbell-type appearance on axial images (Fig. 1). Computed tomography showed no calcification within the tumor. Results of chemical and cytological examinations of the cerebrospinal fluid were normal.

OPERATION

The T2-4 laminectomy and a right-sided T3/4 facetectomy were performed to expose the tumor, which was located in the anterolateral portion of the thecal sac. The tumor was extremely firm, surrounded by a tough pseudocapsule, and tightly adherent to the posterior vertebral wall (Fig. 2). Because the tumor was easily separated from the dura mater, total resection was performed. During the immediate postoperative period, the motor functions of both

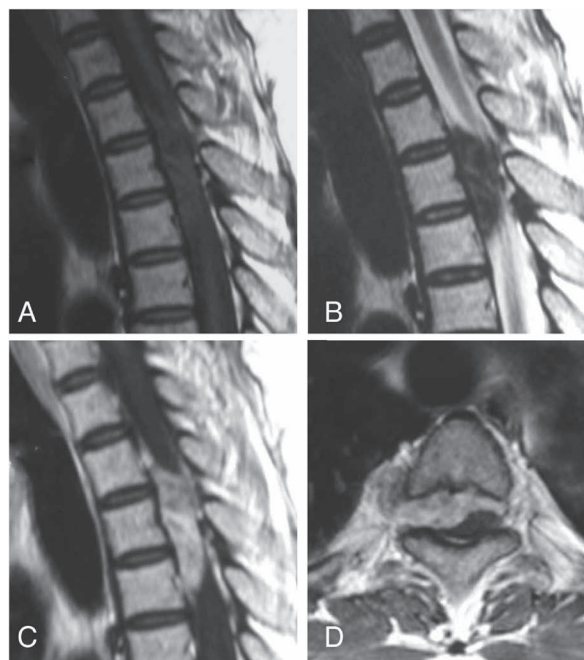


Fig. 1. MR images : A) T1-weighted sagittal image, B) T2-weighted sagittal image, C) T1-weighted sagittal image after administration of Gd-DTPA. D) T1-weighted axial image at the T3/4 level. The tumor is hypointense both on T1- and T2-weighted images and homogeneously enhances after intravenous injection of Gd-DTPA. On the axial image, the tumor extends into the right paravertebral space through the neural foramen and presents as a dumbbell-type lesion.



Fig. 2. Photograph of the tumor. The tumor is surrounded by a thick pseudocapsule and firmly adheres to the vertebral posterior wall. (▲ tumor)

lower limbs improved, and the patient could walk without crutches. Two years after surgery, MR revealed no signs of recurrent tumor, and the patient had no complaints, except for mild dysesthesia of the right foot and mild back pain.

HISTOPATHOLOGICAL EXAMINATION

On macroscopic examination, the tumor was solid and yellow on its cut surface. Necrotic foci were not seen. Microscopic examination showed that the tumor was composed of a proliferation of spindle cells admixed with abundant collagenous and hyalinized stroma (Fig. 3). The tu-

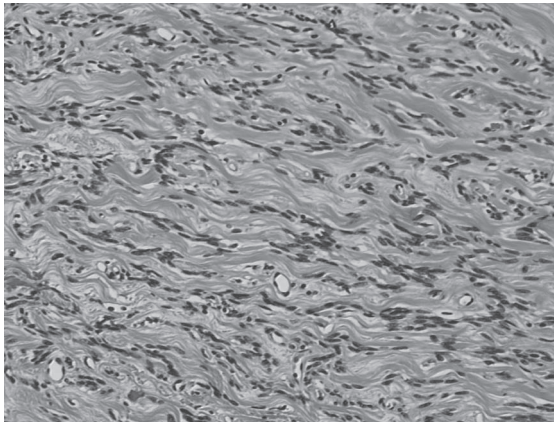


Fig. 3. Histological findings of an hematoxylin and eosin-stained specimen (original magnification : 1 : 200). The H-E stained specimen demonstrates a predominantly spindle-cell proliferation with deposition of dense collagen fibers between the fibroblast-like cells.

mor cells were organized either in a straight, interlacing pattern or in a vaguely storiform fashion (the so-called “patternless pattern”). Nuclei were fusiform or ovoid with inconspicuous nucleoli. Mitotic figures were infrequent. Stromal vessels demonstrated various patterns, including staghorn-like shapes. Psammoma bodies and whorl patterns were not seen. On immunohistochemical staining, almost all tumor cells were strongly positive for CD34, vimentin, bcl-2, and CD99 but were negative for cytokeratin, epithelial membrane antigen (EMA), and S100 protein (Fig. 4).

DISCUSSION

SFT was first reported by Klemperer and Rabin in 1931 as a tumor arising in the pleura¹. The tumor is now thought to originate from mesenchymal and fibroblastic cells, and reports of SFTs elsewhere in the body have accumulated²⁻⁵. Spinal SFTs are usually intraspinal and occupy various regions, including extradural, intradural, intramedullary, and extramedullary sites, as well as any combination of these sites, and are thought to arise from nerve roots, dura, the spinal cord, or parenchyma. In the majority of cases, they are intradural or simultaneously occupy both

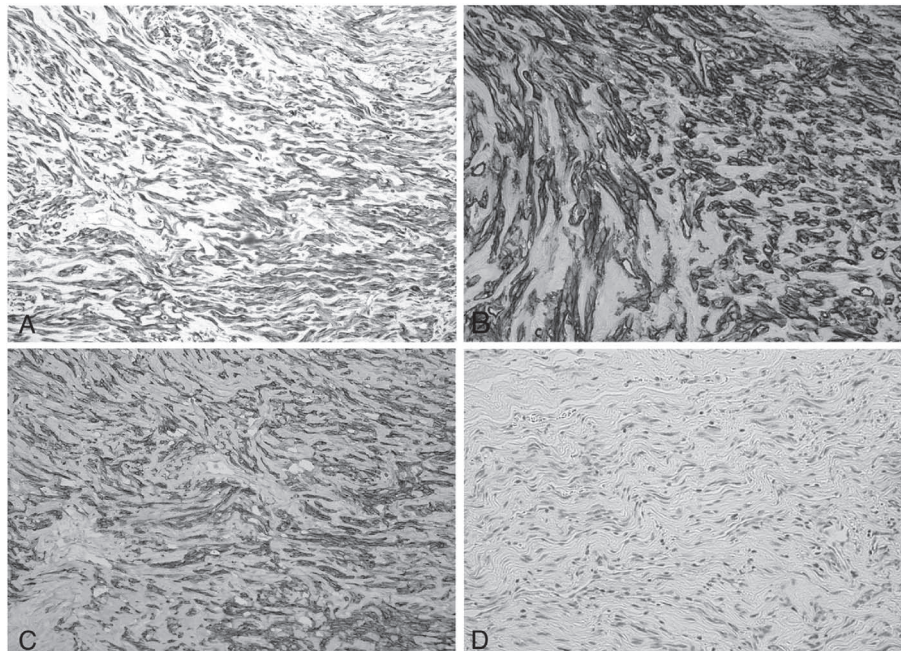


Fig. 4. Immunohistochemistry (original magnification : 1 : 400). Almost all spindle-shaped tumor cells reveal intracytoplasmic reactions for antibodies against vimentin, CD34, and bcl-2. There are no immunoreactions for S100 protein (A : vimentin ; B : CD34 ; C : bcl-2 ; D : S100).

the intradural and extradural regions⁶⁻²². Therefore, the tumor purely extradural and dumbbell-shaped like observed in the present case should be considered a rare pathology. In the present case, the tumor was confined to the extradural space and was firmly adherent to the posterior aspect of the vertebrae but was loosely attached to the dura mater and nerve roots. On the basis of these findings, we concluded that the tumor had arisen from the periosteum of the vertebrae or the posterior longitudinal ligament, although the precise origin could not be determined. O'Connell et al. have documented a case of SFT arising from the periosteum of the tibia²; however, the present report is, to our knowledge, the first of a spinal SFT that could have arisen from the periosteum of the vertebrae or the posterior longitudinal ligament.

The preoperative differential diagnosis for SFT should include schwannoma, meningioma, ependymoma, astrocytoma, and hemangiopericytoma. On MR, nearly all intraspinal SFTs appear to be well-defined, homogeneously to slightly heterogeneously enhancing lesions that are isointense on T1 weighted sequences and hypointense on T2-weighted images. However, these signal characteristics are not specific and do not distinguish SFTs from other tumors. In the present case, the tumor showed low intensity on both T1- and T2-weighted images, but there was no calcification or bony matrix within the tumor on computed tomography. In addition, no susceptibility artifacts (due to hemosiderin deposition within the lesion) were seen on gradient echo imaging. We hypothesize that the hypointensity of the tumor on T2-weighted images was not due to calcification or old hemorrhage but rather due to the tumor's extensive fibrocollagenous component. Therefore, we believe that the low signal intensity on T2-weighted images without calcification is of diagnostic value for SFTs.

The histopathological differential diagnosis of SFT in the spine includes fibrous meningioma, schwannoma, hemangiopericytoma, neurofibroma, ependymoma, astrocytoma, meningeal fibroma, and meningeal myofibroblastoma. The tumor was composed of fibroblast-like spindle cells without pleomorphism or nuclear atypia. Abundant collagenous matrix, without myxoid changes, was also detected. The tumor cells were immunoreactive for vimentin, CD34, bcl-2, and CD99. If these findings are considered, the most likely histological diagnosis is fibrous meningioma. No whorl patterns or psammoma bodies

were present, however, and the immunohistochemical staining was negative for EMA, cytokeratin, and S100 protein. Although fibrous meningiomas may exhibit a weak CD34 immunoreactivity, they are frequently positive for EMA and S100 protein. Conversely, SFT is strongly positive for CD34 in most of its cells, but negative for epithelial membrane antigen and S100 protein. Therefore, the histological findings in the present case are compatible with SFT²³⁻²⁵.

Although SFTs are usually benign, malignant cases have been reported^{26,27}. Thus, malignant transformation and local recurrence cannot be completely ruled out, particularly as the natural history of SFTs in the central nervous system is unclear because of the limited follow-up data. Further studies including long-term follow-up will determine the optimal therapy for these tumors.

CONCLUSION

We report a spinal SFT that we believe had arisen from either the periosteum or the longitudinal ligament of the vertebrae. A SFT should be included in the differential diagnosis of any intraspinal tumor, especially fibrous meningioma and hemangiopericytoma. Immunohistochemical staining is useful for distinguishing a SFT from other tumors. On MR imaging with T2-weighted sequences, a low-intensity signal without calcification is suggestive of a SFT. The recommended treatment is gross total resection because the natural history of SFT is unclear.

REFERENCES

1. Klemperer P, Rabin C. Primary neoplasms of the pleura. A report of five cases. *Arch Pathol* 1931; 11: 385-412.
2. O'Connell JX, Logan PM, Beauchamp CP. Solitary fibrous tumor of the periosteum. *Hum Pathol* 1995; 26: 460-2.
3. Suster S, Nascimento AG, Miettinen M, Sickel JZ, Moran CA. Solitary fibrous tumors of soft tissue. A clinicopathologic and immunohistochemical study of 12 cases. *Am J Surg Pathol* 1995; 19: 1257-66.
4. Briselli M, Mark EJ, Dickersin GR. Solitary fibrous tumors of the pleura: eight new cases and review of 360 cases in the literature. *Cancer* 1981; 47: 2678-89.
5. Chan JK. Solitary fibrous tumour—everywhere, and a diagnosis in vogue. *Histopathology* 1997; 31: 568-76.
6. Alston SR, Francel PC, Jane JA Jr. Solitary fibrous tumor of the spinal cord. *Am J Surg Pathol* 1997; 21: 477-83.
7. Arantes M, Honavar M, Vaz AR, Resende M, Pereira

- JR. Solitary fibrous tumor of the thoracic spine. *Neurochirurgie* 2009 ; 55 : 573-5.
8. Bohinski RJ, Mendel E, Aldape KD, Rhines LD. Intramedullary and extramedullary solitary fibrous tumor of the cervical spine. Case report and review of the literature. *J Neurosurg* 2004 ; 100 : 358-63.
 9. Brunori A, Cerasoli S, Donati R, Giangaspero F, Chiappetta F. Solitary fibrous tumor of the meninges : two new cases and review of the literature. *Surg Neurol* 1999 ; 51 : 636-40.
 10. Donnellan RB, Govender D, Chite SH, Landers AT. An unusual presentation of solitary fibrous tumor. *Spine (Philadelphia, 1976)* 2000 ; 25 : 749-51.
 11. Endo K, Komagata M, Ikegami H, Nishiyama M, Tanaka S, Imakiire A, et al. Dumbbell-type solitary fibrous tumor in the cervical spine. *J Orthop Sci* 2003 ; 8 : 428-31.
 12. Ishii K, Nakamura M, Matsumoto M, Mukai M, Toyama Y, Chiba K. Intramedullary solitary fibrous tumor of the spinal cord. *J Orthop Sci* 2009 ; 14 : 450-4.
 13. Jallo GI, Roonprapunt C, Kothbauer K, Freed D, Allen J, Epstein F. Spinal solitary fibrous tumors : a series of four patients : case report. *Neurosurgery* 2005 ; 57 : E195.
 14. Kakimaru H, Matsusaki M, Sanada H, Iwata A, Uchio Y. Dumbbell-type spinal solitary fibrous tumor with paraplegia. *Orthopedics* 2009 ; 32 : 213.
 15. Kataoka H, Akiyama Y, Kubo S, Itoh H, Hamasuna R, Tajima N, et al. Solitary fibrous tumor of the spinal nerve rootlet : case report and literature survey *Pathol Int* 1999 ; 49 : 826-30.
 16. Kawamura M, Izawa K, Hosono N, Hirano H. Solitary fibrous tumor of the spinal cord : case report and review of the literature. *Neurosurgery* 2004 ; 55 : 433.
 17. Kurtkaya O, Elmaci I, Sav A, Pamir MN. Spinal solitary fibrous tumor : seventh reported case and review of the literature. *Spinal Cord* 2001 ; 39 : 57-60.
 18. Malek AM, Weller SJ, Price DL Jr, Madsen JR. Solitary fibrous tumor presenting as a symptomatic intraspinal mass : case report. *Neurosurgery* 1997 ; 40 : 844-7.
 19. Mordani JP, Haq IU, Singh J. Solitary fibrous tumour of the spinal cord. *Neuroradiology* 2000 ; 42 : 679-81.
 20. Ogawa T, Moriyama E, Beck H, Sonobe H. Solitary fibrous tumor of the thoracic spinal cord. *Neurol Med Chir* 2005 ; 45 : 371-4.
 21. Shin DA, Kim SH, Yoon do H, Kim TS. A dumbbell-shaped solitary fibrous tumor of the cervical spinal cord. *Yonsei Med J* 2008 ; 49 : 167-70.
 22. Vorster SJ, Prayson RA, Lee JH. Solitary fibrous tumor of the thoracic spine. Case report and review of the literature. *J Neurosurg* 2000 ; 92 : 217-20.
 23. Pakasa NM, Pasquier B, Chambonnière ML, Morrison AL, Khaddage A, Perret AG, et al. Atypical presentations of solitary fibrous tumors of the central nervous system : an analysis of unusual clinicopathological and outcome patterns in three new cases with a review of the literature. *Virchows Arch* 2005 ; 447 : 81-6.
 24. Perry A, Scheithauer BW, Nascimento AG. The immunophenotypic spectrum of meningeal hemangiopericytoma : a comparison with fibrous meningioma and solitary fibrous tumor of meninges. *Am J Surg Pathol* 1997 ; 21 : 1354-60.
 25. Sawada N, Ishiwata T, Naito Z, Maeda S, Sugisaki Y, Asano G. Immunohistochemical localization of endothelial cell markers in solitary fibrous tumor. *Pathol Int* 2002 ; 52 : 769-76.
 26. Sun Y, Naito Z, Ishiwata T, Maeda S, Sugisaki Y, Asano G. Basic FGF and Ki-67 proteins useful for immunohistological diagnostic evaluations in malignant solitary fibrous tumor. *Pathol Int* 2003 ; 53 : 284-90.
 27. Vallat-Decouvelaere AV, Dry SM, Fletcher CD. Atypical and malignant solitary fibrous tumors in extrathoracic locations : evidence of their comparability to intra-thoracic tumors. *Am J Surg Pathol* 1998 ; 22 : 1501-11.