Jikeikai Med J 2010 ; 57 : 67-71

Twenty-three-gauge Vitrectomy with Bevacizumab in Patients Having Proliferative Diabetic Retinopathy with an Active Fibrovascular Membrane

Akira WATANABE, Tamaki GEKKA, Tomohiro SHIBATA,
Hirotsugu TAKASHINA, and Hiroshi TSUNEOKA

Department of Ophthalmology, The Jikei University School of Medicine

ABSTRACT

Outcomes were investigated in 8 eyes of 6 patients who had proliferative diabetic retinopathy with an active fibrovascular membrane and in whom 23-gauge microincision vitrectomy surgery was performed after intravitreal administration of 1.25 mg of bevacizumab 3 or 5 days before surgery. The efficacy of the procedure was evaluated in terms of preventing bleeding during and after vitrectomy and of early postoperative visual recovery. The fibrovascular membrane could be removed with a 23-gauge vitreous cutter in all cases. Removal of the fibrovascular membrane was accompanied by only minor bleeding. No iatrogenic retinal tears occurred during surgery. The preoperative level of visual acuity was maintained or improved 1 month after surgery in 7 eyes and 3 and 12 months after surgery in all eyes. This study suggests that intravitreal administration of 1.25 mg of bevacizumab several days before planned 23-gauge microincision vitrectomy surgery is a safe and efficacious adjuvant treatment in eyes undergoing pars plana vitrectomy for treatment of proliferative diabetic retinopathy with an active fibrovascular membrane.

(Jikeikai Med J 2010 ; 57 : 67-71)

Key words : bevacizumab, proliferative diabetic retinopathy, 23-gauge viterctomy

INTRODUCTION

When vitrectomy is performed in patients who have proliferative diabetic retinopathy with an active fibrovascular membrane, removal of the fibrovascular membrane is often accompanied by bleeding, which may decrease visibility during surgery[1]. Hemostasis has conventionally been achieved by increasing the intraocular irrigation pressure ; however, doing so can place stress on the retina and optic nerve. In addition, introducing and extracting hemostatic devices during vitrectomy may cause surgical complications and extend the surgical time. In other words, control of intraoperative bleeding decreases the incidence of intraoperative complications, leading to decreases in surgical stress and operation time. Intravitreal administration of bevacizumab, an antibody against vascular endothelial growth factor (VEGF), in patients with proliferative diabetic retinopathy has been reported to induce regression of the fibrovascular membrane, simplifying its removal during vitrectomy[1-3].

Transconjunctival small-incision 23-gauge vitrectomy, which has recently become popular, is less invasive than conventional 20-gauge vitrectomy[4], but particular caution is required in patients with proliferative diabetic retinopathy, because of the limited available devices. In this study, we examined the

Received for publication, March 11, 2010
渡辺　朗，月花　環，柴田　朋宏，高階　博嗣，常岡　寛
Mailing address : Akira WATANABE, Department of Ophthalmology, The Jikei University School of Medicine, 3-25-8 Nishi-Shimbashi, Minato-ku, Tokyo 105-8461, Japan.
E-mail : akirawa@jikei.ac.jp

performance of transconjunctival small-incision 23-gauge vitrectomy after administration of bevacizumab in patients who had diabetic retinopathy with a fibrovascular membrane. The efficacy of the procedure was evaluated in terms of preventing bleeding during and after vitrectomy and of early postoperative visual recovery.

Subjects and Methods

Outcomes were investigated in 8 eyes of 6 patients who had proliferative diabetic retinopathy with an active fibrovascular membrane and in whom 23-gauge transconjunctival vitrectomy was performed after intravitreal administration of 1.25 mg of bevacizumab (Avastin®, Genetech, Inc., South San Francisco, CA, USA) 3 or 5 days before surgery at The Jikei University School of Medicine Hospital from September 2007 through April 2008 (Fig. 1). The patients were 2 men (2 eyes) and 4 women (6 eyes), ranging in age from 32 to 54 years and with a mean age of 38.7 years (Table 1). Vitrectomy alone was performed in 5 eyes, and vitrectomy plus simultaneous cataract surgery was performed in 3 eyes. The intraoperative complications and postoperative courses were investigated retrospectively on the basis of medical records. Bevacizumab was administered intravitreally with the approval of our hospital's institutional review board, after informed consent had been obtained from the patients. During the follow-up period, the best-corrected visual acuity was measured with a Landolt C chart.

Results

After the preoperative administration of bevacizumab, regression of the fibrovascular membrane was observed at the time of vitrectomy (Fig. 2). This

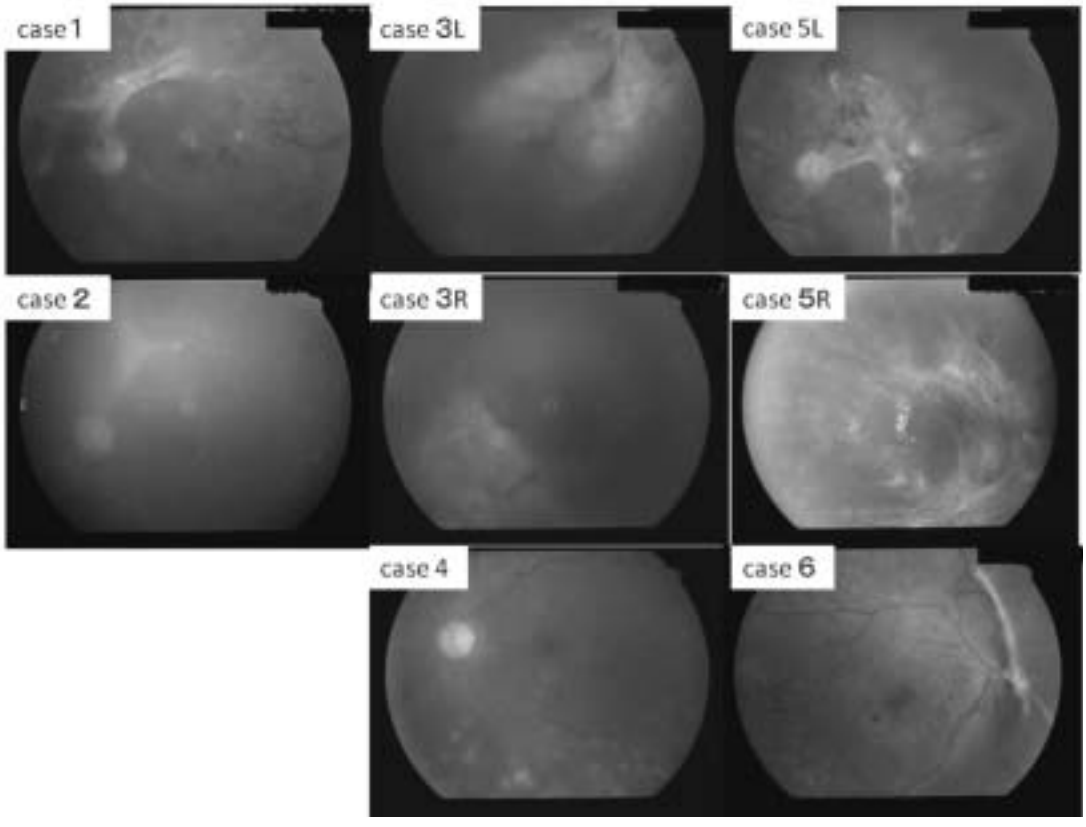

Fig. 1. Preoperative fundus photographs of all cases. Fundus photographs demonstrate severe proliferative diabetic retinopathy in all eyes.

Table 1. Summary of patients

case	Surgical eye	sex	age	Baseline BCVA	T-RD	HbA1c %	IVB-Vit days	surgery	3M BCVA	12M BCVA
1	L	M	38	0.4	−	9.3	5	Vitrectomy	0.5	0.8
2	L	F	35	0.3	−	6.6	5	Vitrectomy+PEA+IOL +trabeculotomy	0.4	0.3
3	L	F	54	0.15	+	8.6	5	Vitrectomy+PEA+IOL	0.2	0.1
3	R	F	54	0.02	+	8.6	5	Vitrectomy+PEA+IOL	0.1	0.08
4	L	M	40	0.2	−	6.7	5	Vitrectomy	0.6	0.6
5	L	F	32	0.08	+	10.6	5	Vitrectomy+silicone oil	0.15	0.08
5	R	F	32	0.06	+	10.6	5	Vitrectomy+silicone oil	0.2	0.06
6	R	F	33	1.0	−	9.6	3	Vitrectomy+SF6gas	1.2	1.0

M=male ; F=female ; IVB-Vit days=time of surgery after intravitreal injection of bevacizumab ; T-RD+=tractional retinal detachment extending to the macula ; PEA+IOL=phacoemulsification and aspiration and intraocular lens implantation ; SF6=sulfur hexafluoride ; BCVA=best-corrected visual acuity

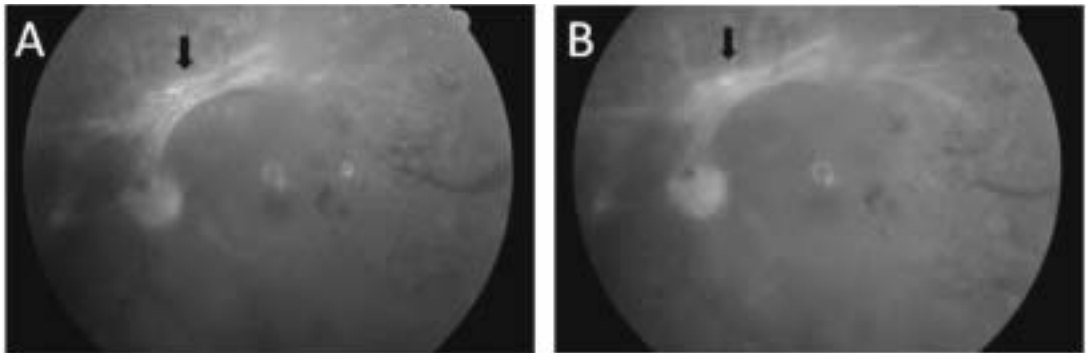

Fig. 2. Case 1. Fundus photographs before (A) and after (B) intravitreal administration of bevacizumab. (A) Fundus photograph demonstrates proliferative diabetic retinopathy in the left eye with localized tractional detachment. (B) Fundus photograph 5 days after administration of 1.25 mg of intravitreal bevacizumab demonstrates contraction of the fibrovascular membrane. ↓

regression resulted in the formation of a space between the retina and the fibrovascular membrane which allowed insertion of the tip of a 23-gauge vitreous cutter for segmental excision of the fibrovascular membrane. The fibrovascular membrane could be removed with a 23-gauge vitreous cutter in all cases. Removal of the fibrovascular membrane was accompanied by only minor intraoperative bleeding (Fig. 3). Hemostasis was achieved with only a transient increase in the intraocular pressure at the time of bleeding. No iatrogenic retinal tears occurred during surgery. The preoperative level of visual acuity was maintained or improved 1 month after surgery in 7 eyes and 3 and 12 months after surgery in all eyes (Fig. 4). Vitreous hemorrhage caused a decrease in visual acuity from the preoperative level 1 month after surgery in 1 eye (case 3-L). No ocular or systemic complications that were attributable to the use of bevacizumab were observed in any case.

Discussion

Elevated vitreal levels of VEGF have been reported in patients with proliferative diabetic retinopathy[5]. Furthermore, injection of the anti-VEGF antibody bevacizumab to treat elevated levels of VEGF in the vitreous body induces shrinkage of the fibrovascular membrane in cases of diabetic retinopathy[1-3]. In the present cases, regression of the fibrovascular membrane was also observed following intravitreal bevacizumab administration before vitrectomy, with minimal bleeding when the fibrovascular membrane was removed during vitrectomy. Thus, vitrectomy can be performed while maintaining a normal intraocular

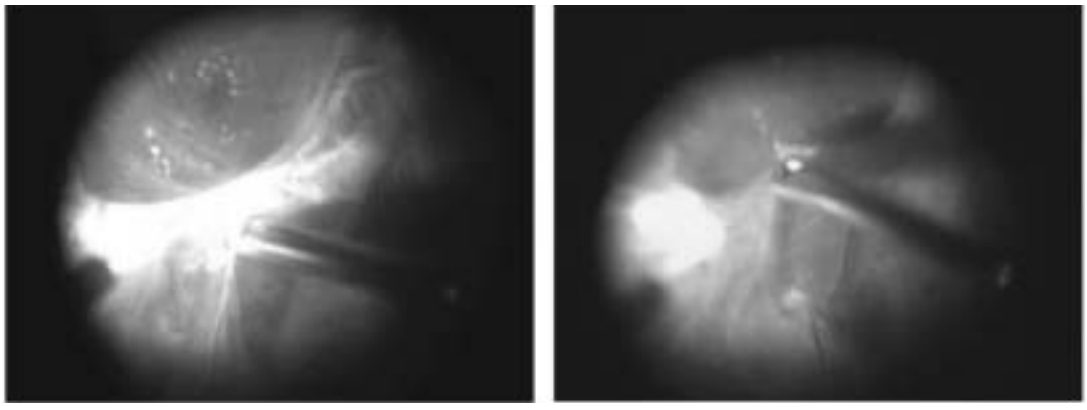

Fig. 3. Case 1. Intraoperative appearance during the cutting of fibrovascular tissue. Minimal bleeding occurred during surgery.

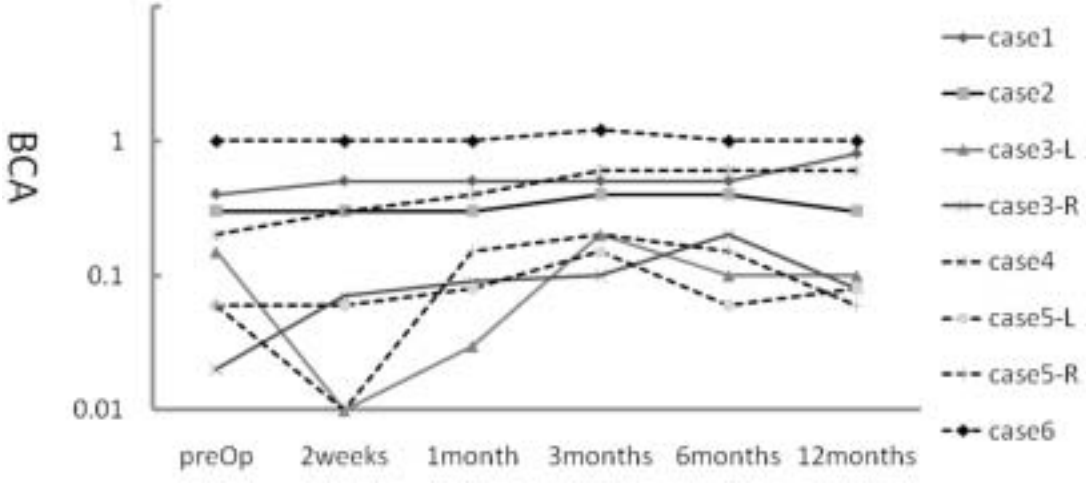

Fig. 4. BCVA changes at different time points after vitrectomy in all eyes. The preoperative level of visual acuity was maintained or improved 1 month after surgery in 7 eyes and 3 and 12 months after surgery in all eyes.

pressure without stress to the retina or the optic nerve.

Rebleeding after vitrectomy may delay visual recovery and cause visual acuity to decrease to less than preoperative levels. In the present series, postoperative rebleeding occurred in 1 eye. In this case, visual acuity 1 month after surgery was worse than that before surgery. The preoperative level of visual acuity was maintained or improved 1 month after surgery in 7 eyes and 3 and 12 months after surgery in all cases. The incidence of postoperative rebleeding in young patients who had undergone vitrectomy surgery for proliferative diabetic retinopathy at our hospital was 66.7%[7]. The incidence of postoperative rebleeding in this study was low (12.5%), suggesting that the use of bevacizumab in combination with vitrectomy effectively prevents postoperative rebleeding and contributes to early visual recovery and vision maintenance. As reported in previous studies[7], improving visual acuity was difficult in patients with preoperative tractional retinal detachment extending to the macula, as seen in cases 3 and 5 (Fig. 1).

Minimally invasive transconjunctival small-incision vitrectomy using a 25-gauge or 23-gauge system has recently become increasingly popular. The advantages of this procedure are reduced levels of postoperative discomfort because 3 ports are created instead of a conjunctival incision[4]. This procedure is

also favorable for future glaucoma surgery in patients with proliferative diabetic retinopathy because the conjunctiva is extensively preserved. However, the availability of devices, including vitreous scissors, for this type of surgery is limited. Therefore, a 23-gauge vitreous surgery system is commonly used for patients who have proliferative diabetic retinopathy with an active fibrovascular membrane. Because the port of a 23-gauge system vitreous cutter is opened at the further end of its shaft than that of a 20-gauge vitreous cutter, segmental excision of the fibrovascular membrane is easier with a 20-gauge vitreous cutter. A space is created between the retina and the epicenter of the fibrovascular membrane following intravitreal administration of bevacizumab[8], which facilitates both insertion of the tip of the 23-gauge cutter under the membrane and segmental excision of the fibrovascular membrane, which is associated with minimal bleeding. Although fewer devices are available for the 23-gauge and 25-gauge vitreous systems than for the 20-gauge system, in most cases of diabetic retinopathy, the fibrovascular membranes can be removed with a vitreous cutter following preoperative administration of bevacizumab. Therefore, we believe that the limited availability of devices does not pose a problem. In addition, if the bimanual method with chandelier illumination is used, the fibrovascular membrane can be removed in all cases.

Systemic complications attributable to the use of bevacizumab include cerebral infarction and myocardial infarction[6]. In regard to ocular complications in eyes having a fibrovascular membrane, retinal pigment epithelial tears and enlargements of tractional retinal detachment have been reported[1]. Although none of the patients in this study showed enlargement of tractional retinal detachment after the use of bevacizumab, tractional retinal detachment may rapidly enlarge in patients with both tractional retinal detachment and retinal tear, as in case 6. Therefore, we performed vitrectomy 3 days after administering bevacizumab to this patient, although vitrectomy used to be performed 5 days after administration. The optimal interval between the administration of bevacizumab and vitrectomy needs to be examined.

References

1. Arevalo JF, Maia M, Flynn HW Jr, Saravia M, Avery RL, Wu L, et al. Tractional retinal detachment following intravitreal bevacizumab (Avastin) in patients with severe proliferative diabetic retinopathy. Br J Ophthalmol 2008 ; 92 : 213-6.
2. Chen E, Park CH. Use of intravitreal bevacizumab as a preoperative adjunct for tractional retinal detachment repair in severe proliferative diabetic retinopathy. Retina 2006 ; 26 : 699-700.
3. Avery RL, Pearlman J, Pieramici DJ, Rabena MD, Castellarin AA, Nasir MA, et al. Intravitreal bevacizumab (Avastin) in the treatment of proliferative diabetic retinopathy. Ophthalmology 2006 ; 113 : 1695-705.
4. Wimpissinger B, Kellner L, Brannath W, Krepler K, Stolba U, Mihalics C, et al. 23-gauge versus 20-gauge system for pars plana vitrectomy : a prospective randomised clinical trial. Br J Ophthalmol 2008 ; 92 : 1483-7.
5. Aiello LP, Avery RL, Arrigg PG, Keyt BA, Jampel HD, Shah ST, et al. Vascular endothelial growth factor in ocular fluid of patients with diabetic retinopathy and other retinal disorders. N Engl J Med 1994 ; 22 : 1480-7.
6. Emerson MV, Lauer AK, Flaxel CJ, Wilson DJ, Francis PJ, Stout JT, et al. Intravitreal bevacizumab (Avastin) treatment of neovascular age-related macular degeneration. Retina 2007 ; 27 : 439-44.
7. Watanabe A, Kouzaki K, Hayashi T. Outcome of vitrectomy for proliferative diabetic retinopathy in patients below 40 years of age (in Japanese). Ganka Shujutu (Jpn J Ophthal Surg) 2005 ; 18 : 279-81.
8. Oshima Y, Shima C, Wakabayashi T, Kusaka S, Shiraga F, Ohji M, et al. Microincision vitrectomy surgery and intravitreal bevacizumab as a surgical adjunct to treat diabetic traction retinal detachment. Ophthalmology 2009 ; 116 : 927-38.