Jikeikai Med J 2003 ; 50 : 29-36

Significance of the Mucin Phenotype of Early Gastric Cancer

Mika Matsuoka, Yoshio Aizawa, Hiroyuki Nagamata, Satoshi Sutoh,
Yoshinari Miyagawa, and Akira Torii

Division of Gastroenterology and Hepatology, Department of Internal Medicine,
The Jikei University School of Medicine

ABSTRACT

Background and Objectives : Histochemical studies have shown that differentiated gastric cancer (D-GC) can be classified according to the phenotype of expressed mucin. In the present study, we investigated the biological divergence of early stage D-GCs expressing different types of mucin.

Methods : Specimens from 73 surgically resected early stage D-GCs were classified on the basis of the phenotype of expressed mucin and immunohistochemical staining for p53, c-*erb*B-2, and Ki-67 protein. We also examined the relationship between the nature of adjacent mucosa and the mucin phenotype of D-GC.

Results : Expression of p53 protein did not differ among the samples. C-*erb*B-2 was overexpressed in some D-GCs but not in those expressing gastric-type mucin. Although the ratio of Ki-67-positive cancer cells was similar among D-GCs with different types of mucin, the distribution of these cells in cancer glands differed. In addition, we identified pure-type intestinal metaplasia in 11.8% of D-GCs expressing gastric-type mucin and in 46.5% of D-GCs expressing intestinal-type mucin.

Conclusion : These findings suggest that biological properties and the nature of the gastric mucosa adjacent to the tumor differ between early stage D-GCs expressing gastric-type and those expressing intestinal-type mucin. (Jikeikai Med J 2003 ; 50 : 29-36)

Key words : gastric cancer, mucin histochemistry, p53, c-*erb*B-2, Ki-67

Introduction

Gastric cancers were originally classified into two major types according to the tendency to form glands, namely intestinal and diffuse types that are related to differentiated and undifferentiated types, respectively. The differentiated gastric cancer (D-GC) was believed to develop in the mucosa of intestinal metaplasia and to exhibit properties of intestinal mucosal cells[1-3].

However, recent developments in mucin immunohistochemistry have shown that approximately 30% of D-GCs express a type of mucin characteristic of the gastric mucosa[4,5]. This type of D-GC has been defined as the gastric-type mucin phenotype (G-phenotype). The G-phenotype has increased malignant potential during the incipient phase of invasion and metastasis and can therefore be distinguished clinicopathologically from D-GCs that express intestinal-type mucin (I-phenotype)[6-10].

To investigate the biological divergence of early D-GCs expressing various mucin phenotypes, we examined 73 early stage D-GCs and classified them into four phenotypes on the basis of mucin histochemistry. We then examined the relations between the mucin phenotype and the expression of proteins (c-*erb*B-2[11-13], p53[14], and Ki-67[15,16]) associated with

Received for publication, November 29, 2002
松岡　美佳，相澤　良夫，長又　博之，須藤　　訓，宮川　佳也，鳥居　　明
Mailing address : Mika Matsuoka, Division of Gastroenterology and Hepatology, Department of Internal Medicine, The Jikei University School of Medicine, 3-25-8, Nishi- Shimbashi, Minato-ku, Tokyo 105-8461, Japan.

the development and proliferation of D-GC. We also histochemically investigated the nature of mucin in adjacent noncancerous mucosa and its relation to the mucin phenotype of D-GCs.

Materials and Methods

Patients

We studied specimens of 73 early stage D-GCs that were surgically resected from June 1994 through September 1999. Twenty-three patients had submucosal cancer, and 50 patients had intramucosal cancer according to the criteria of the Japanese Research Society of Gastric Cancer[17]. Some of the intramucosal cancers may be regarded as severe dysplasia by pathologists outside Japan. However, such tumors represent initial lesions of cancers that invade the submucosa.

The macroscopic appearance of the early D-GCs was as follows: elevated, flat and depressed. The median maximal diameter of these tumors (tumor size) was 18 mm.

The resected tumors were fixed in 10% buffered formalin and cut into 5 mm-thick slices. Slices encompassing the maximal diameter of a tumor were embedded in paraffin, and 3 μm-thick sections were cut for hematoxylin-eosin staining. The samples were histologically classified according to the Japanese Research Society of Gastric Cancer[17] as follows: papillary adenocarcinoma, well differentiated tubular adenocarcinoma, and moderately differentiated tubular adenocarcinoma. The clinicopathological features of these specimens are summarized in Table 1.

Table 1. Clinicopathological features in 73 early stage D-GC

Characteristic	Value
Age (years): Mean±SD(range)	57.3±9.2 (39-79)
Gender (male : female)	67 : 6
Location (C : M : A)	5 : 40 : 28
Macroscopic type (elevated : flat : depressed)	24 : 3 : 46
Size (mm): Mean±SD (range)	22.9±19.6 (2-120)
Histology (pap : well : mod)	4 : 50 : 19
Lymph node metastasis (negative : positive)	71 : 2
Submucosal invasion (− : +)	50 : 23

pap, papillary; well, well differentiated; mod, moderately differentiated

Classification of D-GCs on the basis of histochemical analysis of expressed mucin

Mucin was histochemically analyzed in 3 μm-thick sections of paraffin-embedded specimens. The mucin phenotypes were determined with galactose-oxidase/Schiff (GOS), paradoxical concanavalin A (ConA)[18], and high-iron diamine/alcian blue (pH 2.5; HID-AB) staining[19] as described by Egashira et al.[8] The GOS stain identifies gastric gland surface mucous cell-type mucin, ConA stains stable class III mucosubstances of gastric gland neck cell and pyloric gland cell-type mucin, and HID-AB stains mucin of the intestinal phenotype. The results of the mucin histochemistry were used to classify D-GCs into four phenotypes as follows: G-phenotype, in which at least 90% of cancer cells were positive for GOS or ConA staining or both; I-phenotype, in which at least 90% of cancer cells were positive for HID-AB but negative for GOS and ConA staining; mixed mucin phenotype (M-phenotype), in which cancer cells were stained by one of these methods but could not be classified as either G- or I-phenotypes; and the null mucin phenotype (N-phenotype), in which cancer cells were not stained by any of these methods[8].

Immunohistochemical analyses

Immunohistochemical analyses were performed on 3 μm-thick sections. Sections were processed for c-*erb*B-2, p53, and Ki-67 immunostaining as follows. After sections were heated in a microwave oven with minor modifications, proteins were visualized with the avidin-biotin complex method (ABC Kit, Vector Laboratories, Burlingame, CA, USA). Briefly, sections were incubated overnight at room temperature with the primary antibodies, monoclonal anti-c-*erb*B-2 antibody (Nichirei, Tokyo, Japan) diluted 1 : 200, anti-p53 antibody (Novocastra, Newcastle, UK) diluted 1 : 100, and anti-Ki-67 antibody (Immunotech, Marseille, France) diluted 1 : 100, then processed and stained according to the manufacturer's instructions.

Immunoreactivity was evaluated with light microscopy. When the cancer cell plasma membrane

was distinctly stained for c-*erb*B-2, the specimen was considered positive (overexpressed), regardless of the percentage of stained cells. If the membrane was not stained for c-*erb*B-2, the specimen was considered negative. Only distinct nuclear p53 staining was considered positive.

The frequency of cancer cells positive for Ki-67 was evaluated as the percentage labeling index (LI%)[15]. The distribution of Ki-67-positive cancer cells was evaluated in 10 randomly selected cancer glands from each specimen which were equally divided into upper-, middle-, and lower-third layers. A total of 500 cancer cells in each layer were investigated to calculate the LI%. We then determined differences in the LI% in these layers.

Examination of adjacent noncancerous mucosa

Various degrees of intestinal metaplasia were evident in the adjacent gastric mucosa of 66 of 73 specimens (90.4%). The nature of the mucin in intestinal metaplasia within 5 mm of the tumor border was evaluated with mucin histochemistry described above. Intestinal metaplasia was classified on the basis of mucin phenotype as follows: metaplasia with a mixed gastric and intestinal mucin phenotype was considered mixed gastric and intestinal metaplasia (G-IM) and metaplasia with the intestinal mucin phenotype alone was considered pure intestinal metaplasia (P-IM)[20].

Statistical analysis

Differences were statistically evaluated using the chi-square, Fisher probability, or Mann-Whitney U tests. Differences with a P value less than 0.05 were considered significant.

Results

Classification of D-GCs by mucin histochemistry

The phenotypes of 73 samples were classified as follows: G, 17 (23.3%); I, 43 (58.9%); M, 11 (15.1%); and N, 2 (2.7%).

Relationship between mucin phenotype of D-GC and clinicopathological factors

The clinicopathological features of each mucin phenotype are summarized in Table 2. Because only two specimens were classified as N-phenotype, the clinicopathological features of this type were excluded from the Table. Tumors of G-phenotype were larger than tumors of I-phenotype. The rate of submucosal invasion was slightly, but not significantly, higher in G-phenotype tumors. Papillary adenocarcinomas were of G-phenotype or M-phenotype or both but not of I-phenotype. Lymph node metastasis was found in only 3 patients.

Expression of c-erbB-2 and p53 protein

c-*erb*B-2 was expressed in 19 specimens (26.0%) and was frequently associated with the I- and M-phenotypes (Fig. 1). In contrast, c-*erb*B-2 was not expressed in G-phenotype cancers (Table 3). The relationship between positive c-*erb*B-2 expression and clinicopathological factors in M- and I-phenotype cancers is summarized in Table 4. The rate of c-*erb*B-2 expression was slightly, but not significantly, higher in well differentiated tubular adenocarcinoma

Table 2. Clinicopathological features in various mucin phenotypes of early stage D-GC

Characteristics	G-phenotype ($n=17$)	M-phenotype ($n=11$)	I-phenotype ($n=43$)
Age (years): Mean±SD(range)	60.3±8.3 (49-79)	59.8±9.0 (43-73)	5.0±9.1 (26-72)
Gender (male:female)	16 : 1	11 : 0	38 : 5
Location (C : M : A)	1 : 10 : 6	0 : 4 : 7	4 : 24 : 15
Macroscopic type (elevated:flat:depressed)	6 : 0 : 11	3 : 0 : 8	14 : 3 : 26
Size (mm): Mean±SD (range)	31.5±24.1 (10-120)*	22.8±25.3 (2-100)	19.9±14.8 (2-80)*
Histology (pap : well : mod)	2 : 11 : 4	2 : 6 : 3	0 : 32 : 11
Lymph node metastasis (negative : positive)	15 : 2	11 : 0	43 : 0
Submucosal invasion (− : +)	9 : 8	7 : 4	32 : 11

*$p<0.05$; pap, papillary; well, well differentiated; mod, moderately differentiated

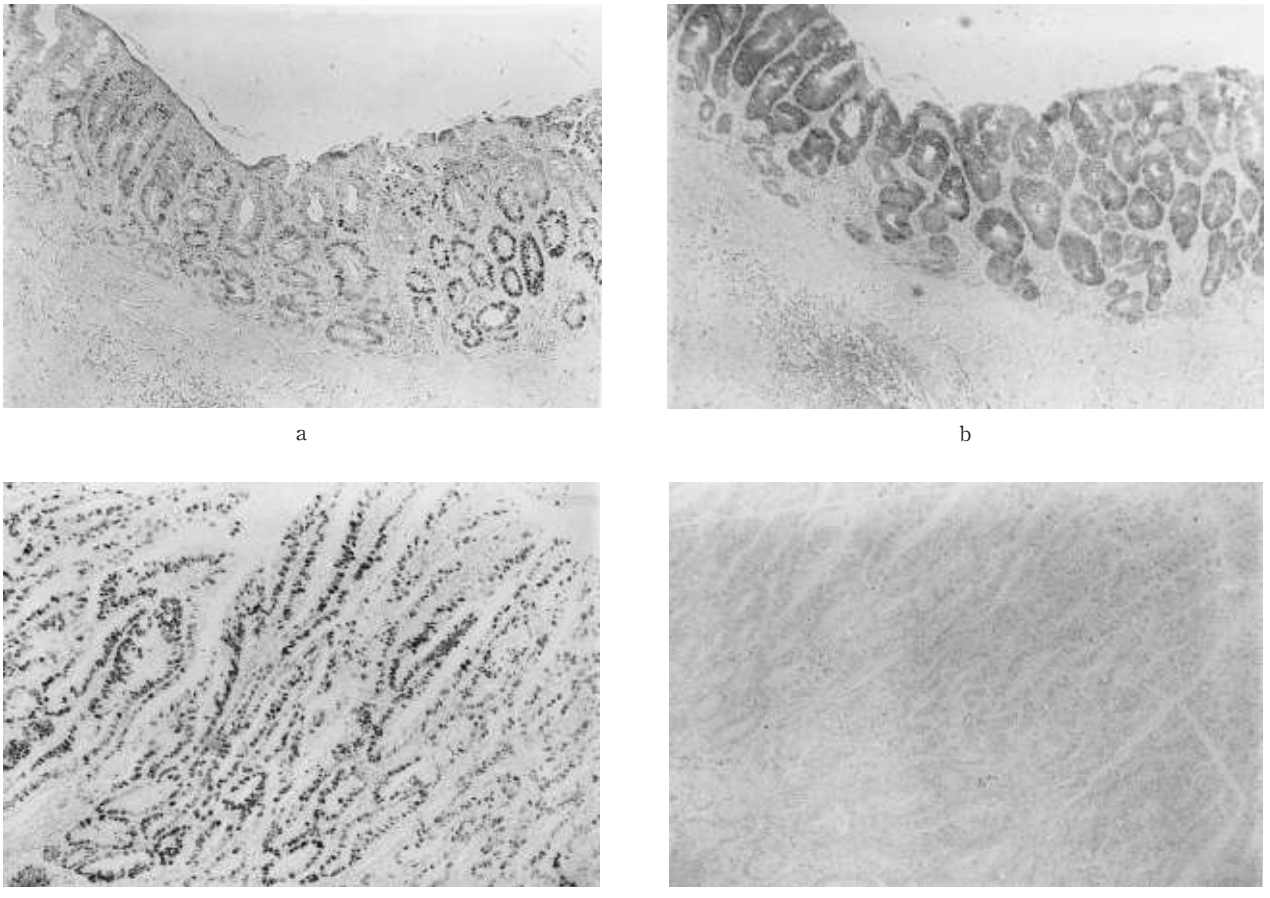

Fig. 1. Immunohistochemical staining of gastric cancer
There is a nuclear staining for p53 (a) and strong membrane immunoreactivity for c-*erb*B-2 (b) in a tumor cell of the I-phenotype.
There is a nuclear staining for p53 (c), but no membrane immunoreactivity for c-*erb*B-2 (d) in a tumor cell of the G-phenotype.

Table 3. Expression of c-*erb*B-2 and p53 protein in D-GC with various mucin phenotypes

	Number of cases positively expressing	
	c-*erb*B-2 (%)	p53 (%)
G-phenotype ($n=17$)	0 (0)*	7 (41.2)
M-phenotype ($n=11$)	2 (18.2)	7 (63.6)
I-phenotype ($n=43$)	17 (39.5)*	16 (37.2)
N-phenotype ($n=2$)	0 (0)	1 (50)

*$p<0.01$

than in moderately differentiated tubular adenocarcinoma. Expression of c-*erb*B-2 and depth of invasion were not correlated. Tumors positive for c-*erb*B-2 were significantly larger than tumors negative for c-*erb*B-2.

Staining for p53 was positive in 31 specimens (42.5%) and did not correlate with the mucin phenotype of D-GC.

LI% and the mucin phenotype of D-GC

The LI% was similar in D-GCs of various mucin phenotypes. The LI% of G-phenotype cancerous glands was higher in the upper-third and middle-third layers than in the lower-third layer. The LI% of I-phenotype glands was significantly higher in the middle-third layer than in the upper-third or lower-third layer. In the upper-third layer, the LI% of G-phenotype D-GCs was significantly higher than that of I-phenotype D-GCs. In contrast, the LI% values

Table 4a. The relation between positive expression c-*erb*B-2 and clinicopathological features in I-phenotype D-GC

Characteristics	c-*erb*B-2 negative ($n=26$)	c-*erb*B-2 positive ($n=17$)
Age (years) : Mean±SD (range)	53.5±8.9 (31-70)*	57.6±8.5 (44-72)
Gender (male : female)	23 : 3	15 : 2
Location (C : M : A)	2 : 13 : 11	2 : 11 : 4
Macroscopic type (elevated : flat : depressed)	6 : 3 : 17	8 : 0 : 9
Size (mm) : Mean±SD (range)	18.2±12.0 (2-52)	22.6±18.7 (2-80)
Histology (pap : well : mod)	0 : 18 : 8	0 : 14 : 3
Submucosal invasion (− : +)	19 : 7	13 : 4

*$p<0.01$ by U test ; pap, papillary ; well, well differentiated ; mod, moderately differentiated

Table 4b. The relation between positive expression c-*erb*B-2 and clinicopathological features in M-phenotype D-GC

Characteristics	c-*erb*B-2 negative ($n=9$)	c-*erb*B-2 positive ($n=2$)
Age (years) : Mean±SD (range)	61.7±9.1 (43-73)	51.5±6.4 (47-56)
Gender (male : female)	9 : 0	2 : 0
Location (C:M:A)	0 : 4 : 5	0 : 0 : 2
Macroscopic type (elevated : flat : depressed)	2 : 0 : 7	1 : 0 : 0
Size (mm) : Mean±SD (range)	16.6±6.0 (6-23)	51.0±69.3 (2-100)
Histology (pap : well : mod)	1 : 5 : 3	1 : 1 : 0
Submucosal invasion (− : +)	7 : 2	0 : 2

*$p<0.01$ by U test ; pap, papillary ; well, well differentiated ; mod, moderately differentiated

of the G-phenotype D-GCs in the lower-third layers were lower than those of the I-phenotype D-GCs (Table 5).

Table 5. LI% of upper, middle and lower layers of cancerous gland showing each mucin phenotype

	LI%		
	G-phenotype ($n=17$)	M-phenotype ($n=11$)	I-phenotype ($n=43$)
Upper layer	41.8±18.5	34.6±17.2	31.8±19.9*
Middle layer	42.3±17.2	43.9±20.1*	42.6±17.1***
Lower layer	19.6±13.7	23.5±10.3*	27.6±14.4**
Whole gland	34.7±11.6	34.0±12.3	34.2±13.5

*$p<0.01$; **$p<0.001$

Mucin phenotype of D-GC and surrounding intestinal metaplasia

Intestinal metaplasia was G-IM in 38 of 66 specimens (57.6%) and P-IM in 28 specimens (42.4%). However, intestinal metaplasia was not evident in 7 specimens, of which 4 were of the I-phenotype. The relation between the mucin phenotype of D-GC and the type of adjacent intestinal metaplasia is shown in Table 6. Intestinal metaplasia of the G-IM type was more frequently associated with the G-phenotype than with the M-phenotype or I-phenotype.

Discussion

Approximately 30% of D-GCs principally express gastric-type mucin[4,5]. This type of D-GC should be distinguishable from other types because of its tendency to invade and metastasize during the incipient phase[6-10]. Here, we investigated the nature of expressed mucin in 73 early stage D-GCs, including 50 intramucosal cancers, and their clinicopathological and biological features. We also examined the histochemical nature of mucin in surrounding noncancerous mucosa with respect to the histopathological background of D-GC.

Table 6. Relation between mucin phenotype of gastric cancer and mucin histochemical findings of intestinal metaplasia in the surrounding mucosa

		G-phenotype* (%)	M-phenotype (%)	I-phenotype (%)	N-phenotype (%)
G-IM	($n=38$)	14/17 (82.3)	4/11 (36.4)	19/43 (44.2)	1/2 (50)
P-IM	($n=28$)	2/17 (11.8)	5/11 (45.4)	20/43 (46.5)	1/2 (50)
No metaplasia	($n=7$)	1/17 (5.9)	2/11 (18.2)	4/43 (9.3)	0/2 (0)

*$p<0.05$

We found G-phenotype mucin expression in 23.3% of early stage D-GCs. However, Egashira et al. have reported that the rate of the G-phenotype is as high as 41.1% in minute (smaller than 5 mm) D-GCs and even higher in cancers smaller than 2.45 mm[20]. This difference might be explained by their hypothesis that some very early G-phenotype D-GCs metamorphose into M- or I-phenotype D-GCs during tumor expansion. We studied G-phenotype D-GCs with a mean diameter of 31.5 mm, which were significantly larger than tumors of the I-phenotype. This finding may be related to the comparatively low rate of G-phenotype tumors found in this study. Another important feature of G-phenotype tumors in our study was that the rate of submucosal invasion was relatively higher than with I-phenotype tumors. Our findings of tumor size and the relatively high rate of submucosal invasion in G-phenotype D-GCs suggest that G-phenotype D-GCs are difficult to correctly diagnose at a very early stage[10]. Conversely, tumors of the G-phenotype might grow so rapidly that they would be more likely than tumors of the I-phenotype to be diagnosed as relatively large tumors with submucosal invasion.

Further differences in clinicopathological features between the G- and I-phenotypes were not statistically significant. However, differences in tumor histology and a tendency toward lymph node metastasis were distinct. Indeed, no papillary adenocarcinomas were of the I-phenotype and metastasis to regional lymph nodes was found only from tumors G-phenotype. The finding that G-phenotype D-GCs tend to metastasize to lymph nodes is consistent with previous findings[9].

Furthermore, to determine differences in the biological features of D-GCs with various mucin phenotypes, we examined the expression of c-*erb*B-2, p53, and Ki-67. The p53 gene is a tumor suppressor ; overexpression of its product indicates that the gene has mutated. Overexpression of the p53 gene product is widespread in D-GC but rare in undifferentiated gastric cancer[14]. However, whether p53 expression differs among various mucin phenotypes has not been studied. The present study showed frequent expression of the p53 gene product in early stage D-GCs with various mucin phenotypes.

In contrast, expression of the c-*erb*B-2 protein was restricted to I- and M-phenotype D-GCs. The oncogene c-*erb*B-2 is mapped to 17q21, encodes the receptor for an epidermal growth factor-like growth factor, and shows tyrosine kinase activity. This gene is preferentially overexpressed in D-GC and is associated with the stage of disease. The c-erbB-2 protein is reportedly overexpressed in 29.5% to 76.5% of D-GCs but in only 9.0% to 29.4% of undifferentiated cancers[11-13]. The overexpression of c-*erb*B-2 has been implicated in the prognosis of D-GC[21]. The present study found that c-*erb*B-2 was overexpressed by 18.2% and 39.5% of tumors of the M- and I-phenotype D-GCs but not by no tumors of the G- or N-phenotype. Thus, we have shown that c-*erb*B-2 overexpression selectively participates in the development and progression of I- and M-phenotype D-GCs.

Because overexpression of c-*erb*B-2 protein indicates a poor prognosis for patients with gastric cancer, we further examined the features of I- and M-phenotype D-GCs overexpressing c-*erb*B-2. Tumors overexpressing c-*erb*B-2 were significantly larger, but their depth of invasion was not related to c-*erb*B-2 overexpression ; therefore, we could not define the significance of c-*erb*B-2 overexpression in early stage D-GCs. However, this issue should be examined further in advanced D-GCs.

Ki-67 is a protein that is expressed in the nucleus during the G1, S, G2, and M phases but not during the G0 phase. Thus, the LI% for Ki-67 indicates proliferative activity[15,16]. Our findings on Ki-67 expression suggest that the proliferative activity of D-GCs is similar regardless of mucin phenotype. However, the distribution of Ki-67-positive cancer cells in cancerous glands differs between G- and I-phenotype tumors. The LI% of the upper-third layer was significantly higher in G-phenotype cancers than in I- or M-phenotype cancers. This finding suggests that G-phenotype cancers tend to extend to the surface of the gastric mucosa, causing G-phenotype D-GCs to be significantly larger than I-phenotype D-GCs in the present study.

The development of D-GCs has been considered to be closely related to intestinal metaplasia[22,23]. The

present study has shown that 90.4% of D-GCs were accompanied by intestinal metaplasia in the surrounding gastric mucosa. In addition, the mucin phenotype of intestinal metaplasia is differs between cancers of the G-phenotype and those of the I- phenotype. The rate of G-IM was significantly higher in G-phenotype D-GCs, whereas the rate of P-IM was higher in I-phenotype D-GCs than in G-phenotype D-GCs. These findings indicate that G-phenotype cancers develop in areas of intestinal metaplasia that express mixed gastric-type and intestinal-type mucin or that I-phenotype D-GCs arise from areas of intestinal metaplasia that express only intestinal-type mucin. However, the mucin phenotype of early stage D-GCs may not be related to the nature of the mucin in the surrounding gastric mucosa. P-IM was observed in 11.8% of G-phenotype cancers, whereas 9.3% of I-phenotype D-GCs were not associated with metaplasia in the surrounding gastric mucosa. These findings indicate that the mucin phenotype of D-GCs cannot be determined on the basis of the mucin phenotype of the environmental gastric mucosa.

In conclusion, these findings suggest that early stage G-phenotype D-GCs differ from I-phenotype D-GCs in c-*erb*B-2 protein expression, the distribution of Ki-67-positive cancer cells in the cancerous gland, and the nature of the gastric mucosa adjacent to the tumor.

Acknowledgements : The authors wish to thank Prof. G Toda (Jikei University) and Dr. T Shimoda (National Cancer Center Hospital) for their excellent suggestions and comments during the preparation of this manuscript.

References

1. Nakamura K, Sugano H, Takagi K. Carcinoma of the stomach : its histogenesis and histological appearances. Jpn J Cancer Res 1969 ; 59 : 251-8.
2. Lauren P. The two histological main types of gastric carcinoma : diffuse and so-called intestinal type carcinoma. Acta Pathol Microbiol Scand 1965 ; 64 : 31-45.
3. Jarvi O, Lauren P. On the role of heterotopias of intestinal epithelium in the pathogenesis of gastric cancer. Acta Pathol Microbiol Scand 1951 ; 29 : 26-43.
4. Tatematsu M, Ichinose M, Miki K, Hasegawa R, Kato T, Ito N. Gastric and intestinal phenotypic expression of human stomach cancers as revealed by pepsinogen immunohistochemistry and mucin histochemistry. Acta Pathol Jpn 1990 ; 40 : 494-504.
5. Kushima R, Hattori T. Histogenesis and characteristics of gastric type adenocarcinomas in the stomach. J Cancer Res Clin Oncol 1993 ; 120 : 103-11.
6. Endoh Y, Tamura G, Watanabe H, Ajioka Y, Motoyama T. The common 18-base pair deletion at codons 418-423 of the E-cadherin gene in differentiated-type adenocarcinomas and intramucosal precancerous lesions of the stomach with the features of gastric foveolar epithelium. J Pathol 1999 ; 189 : 201-6.
7. Shimoda T, Matsuoka M, Sugisaka H, Ikegami M, Egashira Y. Pathological study of differentiated adenocarcinoma in fundic gland region of the stomach (in Japanese). Itocho 1994 ; 29 : 997-1007.
8. Egashira Y. Mucin histochemical study of differentiated adenocarcinoma of stomach (in Japanese). Jpn J Gastroenterol 1994 ; 91 : 839-48.
9. Noda M. Characteristics of early gastric cancer accompanied by lymph node metastasis (in Japanese). Jpn J Gastroenterol 1995 ; 92 : 742-50.
10. Yoshino T, Shimoda T, Saitoh A, Nakanishi Y, Tajima Y, Shirasu T, et al. Macroscopic features of differentiated adenocarcinoma with gastric or intestinal phenotype expression in early gastric cancer (in Japanese). Itocho 1999 ; 34 : 513-25.
11. Falck VG, Gullick WJ. c-*erb*B-2 oncogene product staining in gastric adenocarcinoma : an immunohistochemical study. J Pathol 1989 ; 159 : 107-11.
12. Kameda T, Yasui W, Yoshida K, Tsujino T, Nakayama H, Ito M, et al. Expression of ERBB2 in human gastric carcinomas : relationship between p185ERBB2 expression and the gene amplification. Cancer Res 1990 ; 50 : 8002-9.
13. Sato T, Abe K, Kurose A, Uesugi N, Todoroki T, Sasaki K. Amplification of the c-*erb*B-2 gene detected by FISH in gastric cancer. Pathol Int 1997 ; 47 : 179-82.
14. Kushima R, Moritani S, Hattori T. Over-expression of p53 protein in gastric carcinoma : relationship with development, progression and mucin-histochemical differentiation. Cancer J 1994 ; 7 : 192-7.
15. Dowall M, Willis JE, Prescott P. Cell proliferation in type C gastritis affecting the intact stomach. J Clin Pathol 2000 ; 53 : 784-7.
16. Cattoretti G, Becker MH, Key G, Duchrow M, Schluter C, Galle J, et al. Monoclonal antibodies against recombinant parts of the Ki-67 antigen (MIB1 and MIB3) detect proliferating cells in microwave-processed formalin-fixed paraffin sections. J Pathol 1992 ; 168 : 357-63.
17. Japanese Research Society of Gastric Cancer. The general rules for the gastric cancer study. Tokyo : Kanehara ; 1993.
18. Katsuyama T, Ono K, Nakayama J. Gastric mucus and

mucus secreting cells. In : Kawai K, editor. Recent advances in mucosubstance histochemistory. Amsterdam : Excerpta Medica ; 1985. p. 3–18.

19. Spicer SS. Histochemistry of connective tissue mucopolysaccharides. In : Wagner BM, Smith DE, editors. The connective tissue. Baltimore : Williams & Wilkins ; 1987. p. 251–303.
20. Egashira Y, Shimoda T, Ikegami M. Mucin histochemical analysis of minute gastric differentiated adenocarcinoma. Pathol Int 1999 ; 49 : 55–61.
21. Uchino S, Tsuda H, Keiichi M, Kinoshita T, Sasako M, Saito T, et al. Overexpression of c-*erb*B-2 protein in gastric cancer. Cancer 1993 ; 72 : 3179–84.
22. Correa P, Shiao Y. Phenotypic and genotypic events in gastric carcinogenesis. Cancer Res 1994 ; 54 : 1941–43.
23. Filipe MI, Munoz N, Matko I, Kato I, Kirn VP, Jutersek A, et al. Intestinal metaplasia types and the risk of gastric cancer : a cohort study in Slovenia. Int J Cancer 1994 ; 57 : 324–9.