東京慈恵会医科大学 デジタル署名者：東京慈恵会医科大学
日付：2022.08.12 11:55:00 +09'00'

Jikeikai Med J 2022；69：1-6

Case Report

Rapid Progression of a Retroperitoneal Malignant Peripheral Nerve Sheath Tumor

Teruyuki Takishima, Shinji Onda, Masashi Tsunematsu, Yosuke Igarashi, Tomohiko Taniai, Jungo Yasuda, Norimitsu Okui, Kenei Furukawa, Koichiro Haruki, and Toru Ikegami

Division of Hepatobiliary and Pancreas Surgery, Department of Surgery, The Jikei University School of Medicine

ABSTRACT

Background：Malignant peripheral nerve sheath tumors (MPNSTs) are rare, aggressive soft-tissue tumors associated with high rates of local recurrence and metastasis.

Case presentation：A 28-year-old man with neurofibromatosis type 1 in whom a benign retroperitoneal peripheral nerve sheath tumor had been diagnosed 4 years earlier on the basis of fine-needle aspiration presented with increasing abdominal pain. Computed tomographic examination showed tumor enlargement, superior mesenteric artery (SMA) encasement, and intratumoral hemorrhage. Surgical resection with SMA preservation was performed；however, the tumor capsule partially ruptured during SMA dissection. Histopathological and immunohistochemical findings were consistent with MPNST and suggested that malignant transformation had occurred. Two months after surgery, multiple tumors were diagnosed in the abdominal cavity. The tumors were extremely aggressive and incurable, resulting in the patient's death 4 months after resection.

Conclusions：Peripheral nerve sheath tumors associated with neurofibromatosis type 1 can undergo malignant transformation. After incomplete resection, MPNST can be aggressive and spread rapidly.

(Jikeikai Med J 2022；69：1-6)

Key words：neurofibrosarcoma, retroperitoneal neoplasms, neurofibromatosis type 1, neoplasm recurrence, peripheral nervous system neoplasms

Introduction

Malignant peripheral nerve sheath tumors (MPNSTs) are rare and aggressive sarcomas that arise from the peripheral nerve sheath. Approximately 50% of these tumors are associated with neurofibromatosis type 1 (NF1)[1]. An MPNST can occur in any part of the body, and 5.5% are found in the retroperitoneal space[2]. Many MPNSTs result from transformation of a benign peripheral nerve sheath tumor[3]. We report on a patient with NF1 and an MPNST located in the retroperitoneal space. Two months after tumor resection, multiple abdominal tumors were diagnosed；they rapidly progressed and caused the patient's death 2 months later.

Case Presentation

A 28-year-old man in whom NF1 had been diagnosed in childhood presented with increasing abdominal pain. On examination, the abdomen was distended and tender with a

Received：October 27, 2021 / Accepted：April 14, 2022
瀧島　輝幸，恩田　真二，恒松　　雅，五十嵐陽介，谷合　智彦，安田　淳吾，奥井　紀光，古川　賢英，春木孝一郎，池上　　徹
Mailing address：Shinji Onda, Division of Hepatobiliary and Pancreas Surgery, Department of Surgery, The Jikei University School of Medicine, 3-25-8 Nishi-shimbashi, Minato-ku, Tokyo 105-8461, Japan.
E-mail：s-onda@jikei.ac.jp

palpable firm mass in the left upper quadrant. Four years earlier, computed tomography (CT) had revealed a 30-mm diameter retroperitoneal tumor around the superior mesenteric artery (SMA) (Fig. 1A). Endoscopic ultrasound-guided fine-needle aspiration of the tumor revealed it was a benign peripheral nerve sheath tumor (Fig. 1B). The CT examination 6 months after the first CT had shown slight shrinkage of the tumor without treatment and further examinations every 6 months for 4 years had shown no significant change. Because the patient had had an allergic reaction to an iodinated contrast agent, non-contrast-enhanced magnetic resonance imaging had been performed 6 months earlier (Fig. 1C). The CT examination at the time of this admission showed tumor enlargement (60 mm) and intratumoral hemorrhage (Fig. 1D), and abdominal angiography showed mild encasement of the SMA without contrast extravasation (Fig. 1E). Laboratory findings were hemoglobin concentration, 12.4 g/dL ; hematocrit, 36.3% ; albumin concentration, 3.2 g/dL ; and C-reactive protein concentration, 5.62 mg/dL.

Because of the patient's pain, we decided to perform surgery. Although the SMA was completely encased by the tumor, we believed the tumor was benign and planned complete tumor resection with preservation of the SMA. After laparotomy was performed, the retroperitoneal tumor was identified. The tumor was well-encapsulated, elastic, and firm and displaced the pancreas cephalad and ventrally. The retroperitoneum was divided along the inferior margin of the pancreas. The tumor adherent to the pancreas was dissected free, was meticulously dissected from the SMA, and removed (Fig. 2A). However, while the tumor was being dissected from the SMA, its capsule partially ruptured. The operation time was 205 minutes, and intraoperative blood loss was 910 mL.

Histopathological examination of the resected specimens revealed a 6.3 × 5.8 cm tumor mostly confined within a fibrous capsule. The tumor had a grayish white solid component with large areas of hemorrhage, degeneration, and necrosis (Fig. 2B). Hematoxylin and eosin staining showed spindle-shaped cells arranged in sheets and a fascicular pattern with eosinophilic cytoplasm. Nuclei were round to oval and had dense chromatin with visible mitoses (Fig. 2C, 2D). Immunohistochemical staining showed that the tumor cells were only partially positive for S-100 (Fig. 2E). Staining for Ki-67 was positive in more than 70% of the cells (Fig. 2F). On the basis of these findings, MPNST was diagnosed.

After surgery, the patient had a relief of abdominal pain and no complications. He was discharged on postoperative day 12. After the histopathological diagnosis of MPNST, when the tumor starts to grow, we intended to perform re-resection with the SMA resection. Two months after surgery, abdominal distension developed. A CT examination showed multiple tumors in the abdominal cavity (Fig. 3A, 3B). The tumors were extremely aggressive and considered incurable, and the patient died 4 months after surgery. Owing to the patient's family refusal, no autopsy was performed. Because the recurrent tumors surrounded the SMA, they might have been caused by the tumor capsule having ruptured during surgery.

DISCUSSION

Of soft-tissue sarcomas, 4% are MPNSTs, which have a high risk of recurrence and a poor prognosis[4]. The lifetime risk of MPNST developing in a patient with NF1 is 9% to 13%[5]. The median age at the time of tumor diagnosis is 31 years[5]. Because MPNST is the leading cause of death in patients with NF1[4], it must be quickly diagnosed and treated. Risk factors for MPNST include deletion of the entire *NF1* gene, a family history of MPNST, and a mass that is firm, rapidly growing, and painful[6]. Prognostic factors for MPNST include tumor size, depth, location, and malignant grade but not age or sex[7]. Helpful for diagnosing MPNST are magnetic resonance imaging and fluorodeoxyglucose positron emission tomography[8].

A possible curative treatment of MPNST is complete surgical resection with negative surgical margins. However, after surgery, local recurrence or distant metastasis occurs in a majority of patients[9]. The present patient had a peripheral nerve sheath tumor that was initially benign but then transformed into a MPNST that recurred throughout the abdomen within 2 months of surgical resection. Complete resection is difficult if tumors have invaded blood vessels. In our patient, the tumor had not increased in size during the follow-up period of 4 years, and at the time of this admission, the rapid increase in tumor size was thought to be caused by intratumoral hemorrhage. Because we had planned to resect the tumor and did not suspect malignancy, we did not perform combined resection of the tumor and

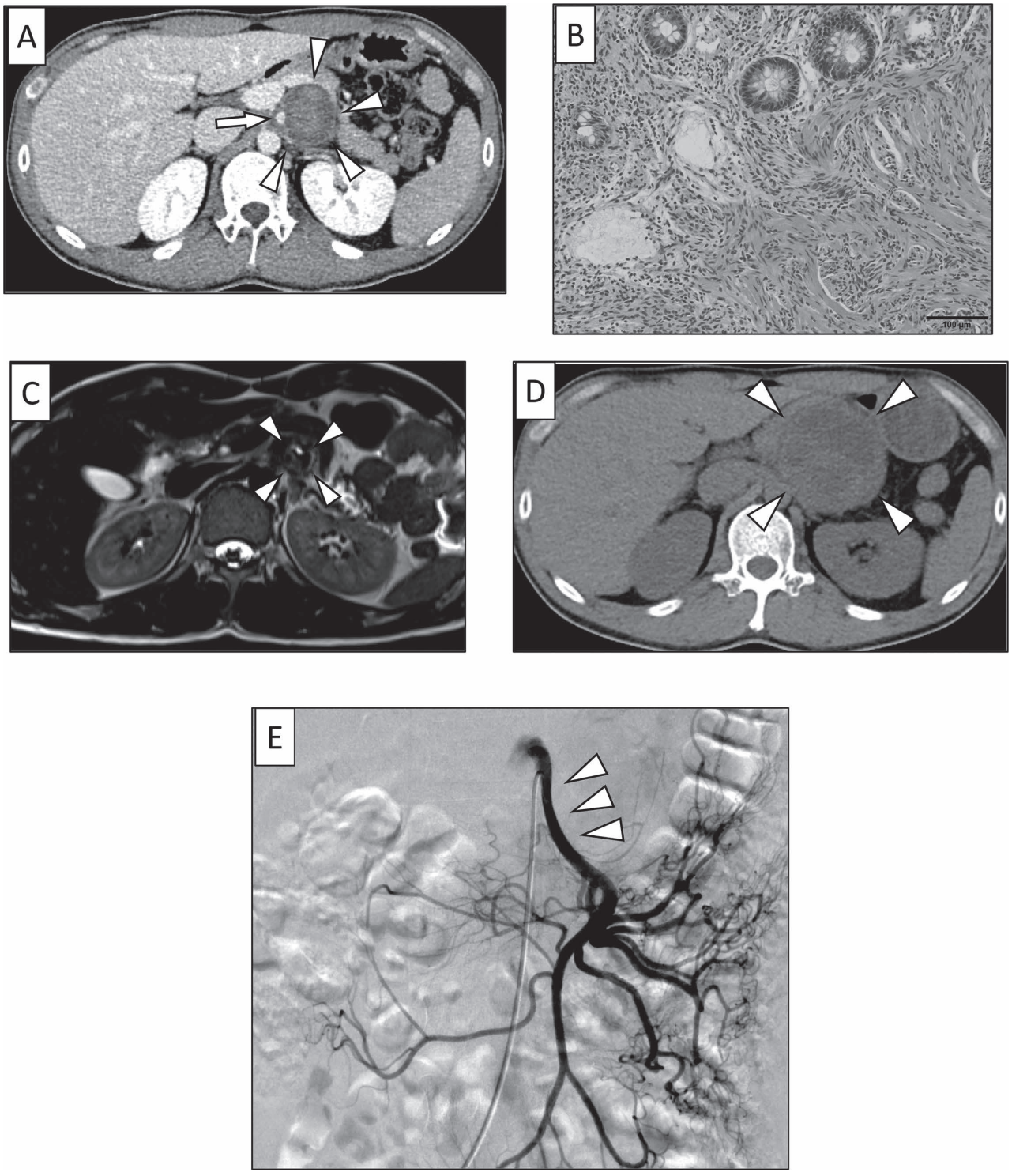

Fig. 1. (A) Computed tomographic examination 4 years earlier revealed a 30-mm diameter retroperitoneal tumor (white arrowheads) around the superior mesenteric artery (white arrow). (B) Endoscopic ultrasound-guided fine-needle aspiration of the tumor revealed it was a benign peripheral nerve sheath tumor. (C) Magnetic resonance imaging 6 months earlier showed a 30 mm retroperitoneal tumor (white arrowheads). (D) Preoperative computed tomography showed tumor enlargement (60 mm) and intratumoral hemorrhage (white arrowheads). (E) Emergent abdominal angiography showed mild encasement of the superior mesenteric artery SMA without contrast extravasation.

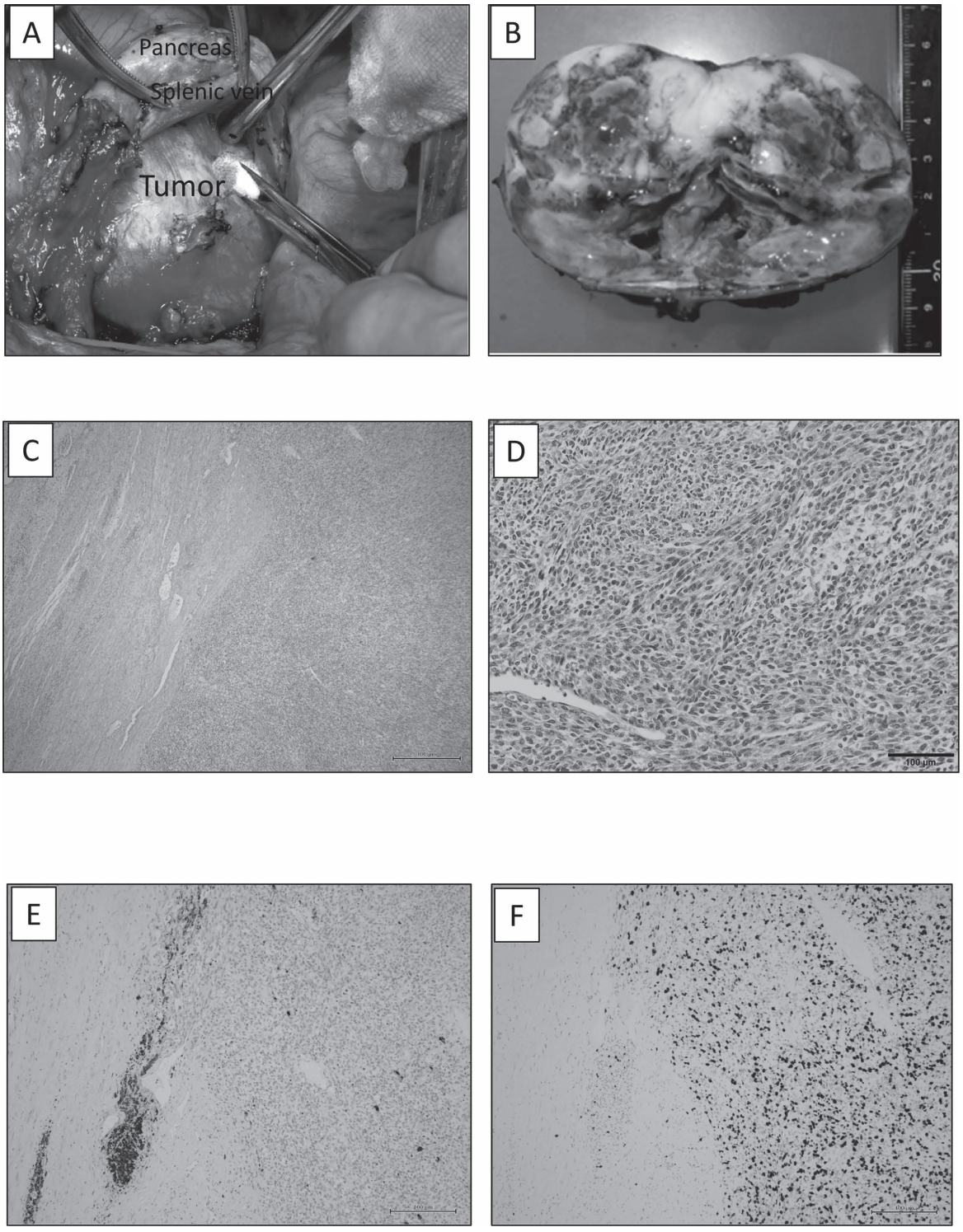

Fig. 2. (A) During surgery, a well-encapsulated retroperitoneal tumor was identified displacing and adhering to the pancreas before dissection. (B) Histopathological examination revealed a 6.3 × 5.8 cm grayish white solid tumor mostly confined within a fibrous capsule, with large areas of hemorrhage, degeneration, and necrosis. (C) Hematoxylin and eosin staining (40× magnification) showed spindle-shaped cells arranged in sheets and a fascicular pattern with eosinophilic cytoplasm. Nuclei were round to oval with dense chromatin and visible mitoses. (D) Hematoxylin and eosin staining (100× magnification). (E) S-100 staining was only partially positive for the tumor cells (100× magnification). (F) Ki-67 staining was positive in more than 70% of the cells (100× magnification).

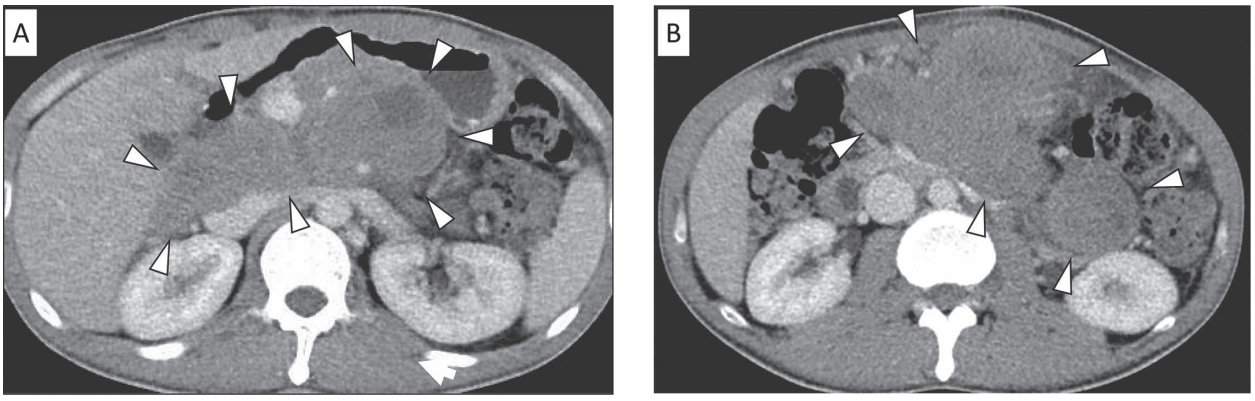

Fig. 3. (A, B) Contrast-enhanced computed tomographic examination 2 months after surgery showed multiple tumors (white arrowheads) in the abdominal cavity.

blood vessels owing to the risk of complications. Although it was considered after the postsurgical recurrence, we elected not to because of the rapid tumor progression.

The immunoreactivity of Ki-67, which is used to evaluate the tumor growth fraction, has been reported by one study to be in 5% to 65% of the tumor cell nuclei in 23/26 patients with MPNSTs[10]. Another study has found that a high Ki-67 labelling index is associated with a poor prognostic indicator for MPNST[11]. In the present patient, the Ki-67 index was extremely high, which might be associated with early recurrence of the MPNST. One case of early recurrence of a nonretroperitoneal MPNST with high Ki-67 has been reported[12]. A nationwide cohort study in the Netherlands has found that localized retroperitoneal MPNSTs have a significantly worse outcome (median survival, 1.1 years) than do MPNSTs in other sites (6.0 years)[2] and has stated that resectability is the most important predictor of survival. Other series have shown that macroscopically positive surgical margins are strongly correlated with poor survival[13,14]. However, regional lymph node involvement is rare[15].

In addition to surgery, optimal preoperative or postoperative adjuvant therapies for MPNST have not been established. Adjuvant radiation therapy is generally recommended for patients with large high-grade lesions or with positive resected tumor margins[16], but one study suggests that radiation therapy does not increase overall survival[17]. In addition, chemotherapy for MPNST is similar to treatment paradigms for other soft-tissue sarcomas ; however, optimal regimens have not been clearly defined because current regimens have provided only a marginal survival benefit[1]. Clinical trials have also shown that outcomes are not improved by targeted therapies blocking several signaling pathways known to drive MPNST pathogenesis[1]. Therefore, our patient did not receive adjuvant therapy.

Due to the risk of malignant transformation, peripheral nerve sheath tumors in patients who have NF1 must be carefully followed up. Development of symptoms or tumor growth indicates the need for further investigation and consideration of surgical resection. For tumors that cannot be completely resected or that develop metastases, multidisciplinary treatment is necessary.

In conclusion, peripheral nerve sheath tumors associated with NF1 can undergo malignant transformation. The resulting MPNST can be aggressive and spread rapidly after incomplete resection.

Authors have no conflict of interest.

Funding : This manuscript was supported by JSPS KAKENHI (Grant Number 21K15515).

References

1. Farid M, Demicco EG, Garcia R, Ahn L, Merola PR, Cioffi A, et al. Malignant peripheral nerve sheath tumors. Oncologist. 2014 ; 19 : 193-201.
2. Martin E, Coert JH, Flucke UE, Slooff WBM, Ho VKY, van der Graaf WT, et al. A nationwide cohort study on treatment and survival in patients with malignant peripheral nerve sheath tumours. Eur J Cancer. 2020 ; 124 : 77-87.
3. Fasih S, Suppiyah S, Barron J, Tapia CB, Avery R, Dickson B, et al. Malignant transformation of plexiform neurofibroma to MPNST while on MEK inhibitor. Neurooncol Adv. 2021 ; 3 : vdab033.
4. Widemann BC, Italiano A. Biology and management of undif-

ferentiated pleomorphic sarcoma, myxofibrosarcoma, and malignant peripheral nerve sheath tumors : state of the art and perspectives. J Clin Oncol. 2018 ; 36 : 160-7.
5. Evans DGR, Huson SM, Birch JM. Malignant peripheral nerve sheath tumours in inherited disease. Clin Sarcoma Res. 2012 ; 2 : 17.
6. Reilly KM, Kim A, Blakely J, Ferner RE, Gutmann DH, Leguis E, et al. Neurofibromatosis type 1-associated MPNST state of the science : outlining a research agenda for the future. J Natl Cancer Inst. 2017 ; 109 : djx124.
7. Cai Z, Tang X, Liang H, Yang R, Yan T, Guo W. Prognosis and risk factors for malignant peripheral nerve sheath tumor : a systematic review and meta-analysis. World J Surg Oncol. 2020 ; 18 : 257.
8. Ferner RE, Golding JF, Smith M, Calonje E, Jan W, Sanjayanathan V, et al. [18F]2-fluoro-2-deoxy-D-glucose positron emission tomography (FDG PET) as a diagnostic tool for neurofibromatosis 1 (NF1) associated malignant peripheral nerve sheath tumours (MPNSTs) : a long-term clinical study. Ann Oncol. 2008 ; 19 : 390-4.
9. Tora MS, Xenos D, Texakalidis P, Boulis NM. Treatment of neurofibromatosis 1-associated malignant peripheral nerve sheath tumors : a systematic review. Neurosurg Rev. 2020 ; 43 : 1039-46.
10. Kindblom LG, Ahldén M, Meis-Kindblom JM, Stenman G. Immunohistochemical and molecular analysis of p53, MDM2, proliferating cell nuclear antigen and Ki67 in benign and malignant peripheral nerve sheath tumors. Virchows Arch. 1995 ; 427 : 19-26.
11. Watanabe T, Oda Y, Tamiya S, Kinukawa N, Masuda K, Tsuneyoshi M. Malignant peripheral nerve sheath tumours : high Ki67 labelling index is the significant prognostic indicator. Histopathology. 2001 ; 39 : 187-97.
12. Edizer DT, Ozdoğan A, Karaman E, Işıldak H. Report of a case of malignant peripheral nerve sheath tumor of the neck with an early local recurrence. Ear Nose Throat J. 2011 ; 90 : E1-3.
13. Valentin T, Le Cesne A, Ray-Coquard I, Italiano A, Decanter G, Bompas E, et al. Management and prognosis of malignant peripheral nerve sheath tumors : the experience of the French Sarcoma Group (GSF-GETO). Eur J Cancer. 2016 ; 56 : 77-84.
14. Watson KL, Al Sannaa GA, Kivlin CM, Ingram DR, Landers SM, Roland CL, et al. Patterns of recurrence and survival in sporadic, neurofibromatosis Type 1-associated, and radiation-associated malignant peripheral nerve sheath tumors. J Neurosurg. 2017 ; 126 : 319-29.
15. Godfrey GJ, Farghaly H. Lymph node metastasis of malignant peripheral nerve sheath tumor in the absence of widespread disease five years after diagnosis : a rare finding. Int J Clin Exp Pathol. 2010 ; 3 : 812-4.
16. Wong WW, Hirose T, Scheithauer BW, Schild SE, Gunderson LL. Malignant peripheral nerve sheath tumor : analysis of treatment outcome. Int J Radiat Oncol Biol Phys. 1998 ; 42 : 351-60.
17. Kahn J, Gillespie A, Tsokos M, Ondos J, Dombi E, Camphausen K, et al. Radiation therapy in management of sporadic and neurofibromatosis type 1-associated malignant peripheral nerve sheath tumors. Front Oncol. 2014 ; 4 : 324.