

Case Report

Metastasis of Colon Cancer to Axillary Lymph Nodes

Toshimasa SUZUKI¹, Hidejiro KAWAHARA¹, Takenori HAYASHI¹, Kazuhisa YOSHIMOTO¹,
Susumu KOBAYASHI¹, Hideyuki KASHIWAGI², Katsuhiko YANAGA²,
and Yutaka YAMAGUCHI³

¹*Department of Surgery, Kashiwa Hospital, The Jikei University School of Medicine*

²*Department of Surgery, The Jikei University School of Medicine*

³*Department of Pathology, The Jikei University School of Medicine*

ABSTRACT

Detecting metastasis of colorectal cancer to axillary lymph nodes is extremely unusual, even in the terminal stage. We report on a patient with colon cancer who presented with the first innidiated recurrence in lymph nodes of the left axilla after surgery. A 72-year-old woman underwent left hemicolectomy in April 2001 for advanced cancer of the descending colon. In December 2001 innidiated recurrence was suspected because the level of carcinoembryonic antigen had increased to 12.9 ng/ml (normal, 5.8 ng/ml or less). However, no recurrent lesion was detected with computed tomography or magnetic resonance. Subsequently, the carcinoembryonic antigen level continued to increase and reached 431.8 ng/dl in June 2002. However, no recurrent lesion was recognized with computed tomography or radioisotope examination. The patient discovered two 1-cm-diameter tumors in the left axilla in late July 2002. We performed lumpectomy under local anesthesia. Poorly differentiated adenocarcinoma was found in the lymph nodes, and the findings of histological examination of the surgical specimen were similar to those from the previous surgery.

(Jikeikai Med J 2006 ; 53 : 167-70)

Key words : colon cancer, axillary lymph nodes, metastasis

INTRODUCTION

Metastasis to the skin or body-surface lymph nodes occurs in cases of malignancy, especially in an extensive metastatic disease. Recurrence of colorectal cancer in the inguinal lymph nodes or at the surgical incision is associated with a dismal prognosis. However, detecting metastasis from colorectal cancer to axillary lymph nodes is extremely unusual, even in the terminal stage. We report on a patient with colon cancer who presented with the first innidiated recurrence in the left axillary lymph node after sur-

gery. To our knowledge, a similar case has not been reported previously.

CASE REPORT

A 72-year-old woman underwent left hemicolectomy in April 2001 for advanced cancer of the descending colon. The tumor was a Dukes' C lesion, with poorly to moderately differentiated adenocarcinoma and vascular invasion, measuring 7 cm in maximal diameter and extending within the wall without serosal invasion. Three regional lymph

Received for publication, July 18, 2006

鈴木 俊雅, 河原秀次郎, 林 武徳, 良元 和久, 小林 進, 柏木 秀幸, 矢永 勝彦, 山口 裕

Mailing address : Hidejiro KAWAHARA, Department of Surgery, Kashiwa Hospital, The Jikei University School of Medicine, Kashiwashita 163-1, Kashiwashi, Chiba 277-8567, Japan.

E-mail : kawahide@jikei.ac.jp

nodes exhibited metastasis. Postoperative treatment consisted of adjuvant chemotherapy with uracil-tegafur, 450 mg/day p.o., since June 2001. In December 2001 the serum level of carcinoembryonic antigen (CEA) increased to 12.9 ng/ml (normal, 5.8 ng/ml or less). However, no recurrent lesion was detected with computed tomography (CT) or magnetic reso-

nance. The CEA level continued to increase and reached 431.8 ng/dl in June 2002. However, no recurrent lesion was recognized with CT or radioisotope examination.

Two 1-cm-diameter tumors were discovered by the patient in left axilla in late July 2002 (Fig. 1). We performed lumpectomy under local anesthesia (Fig. 2).

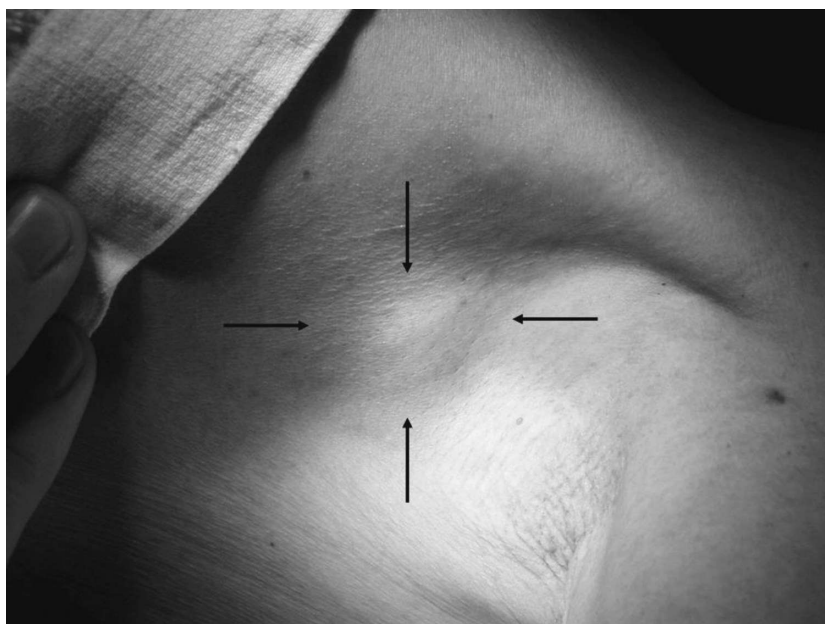


Fig. 1. Preoperative findings: Arrows indicate two 1-cm-diameter tumors in the left axilla. The right side is cephalad.

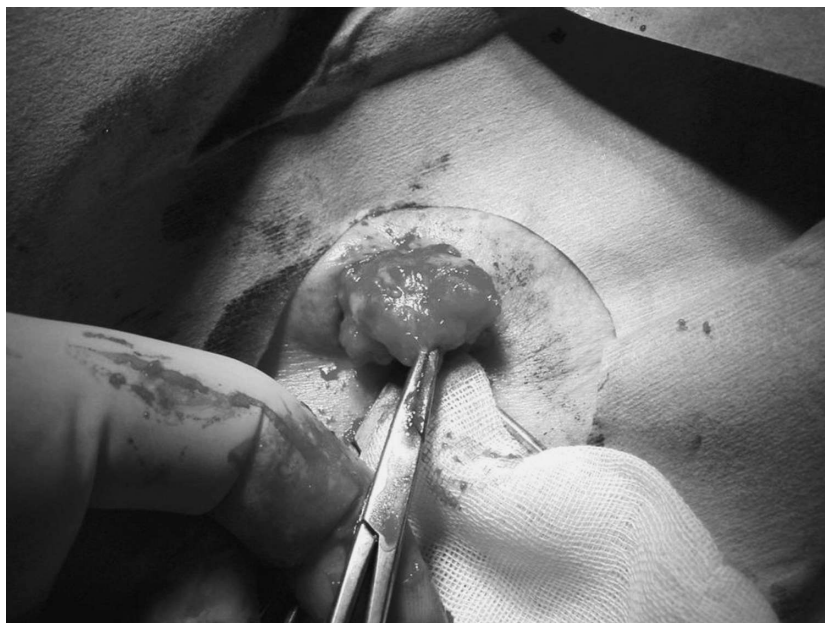

Fig. 2. The tumors were recognized as metastatic lymph nodes by lumpectomy under local anesthesia.

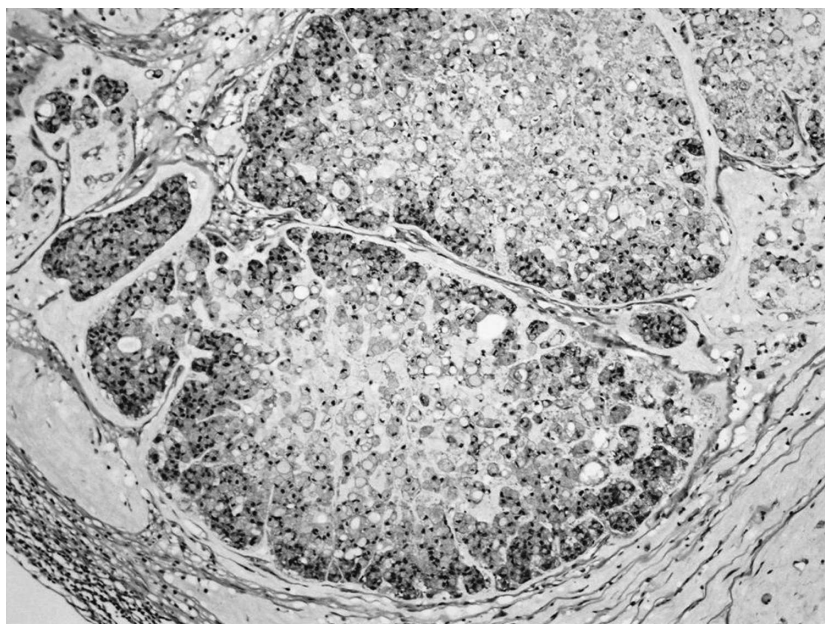


Fig. 3. Examination of the resected lymph nodes (hematoxylin and eosin, 100 \times) showed poorly differentiated adenocarcinoma with pathological features similar to those of tissue obtained at the previous operation.

Poorly differentiated adenocarcinoma, with pathological features similar to those of the primary lesion (Fig. 3), was found in the lymph nodes. Therefore, the possibility of metastasis of colon cancer to the left axillary lymph nodes was considered. The CEA level had decreased to 124.6 ng/dl 2 weeks after resection. We performed radiation therapy to the left axilla, but the cancer metastasized to multiple sites in the lung, and the patient died in April 2003.

DISCUSSION

Generally, metastasis to body-surface lymph nodes, such as Vichow's metastasis from gastric cancer and inguinal lymph node metastasis from rectal cancer, is associated with a dismal prognosis. Cutaneous metastasis from abdominal malignancies is rare, occurring in fewer than 5% of patients¹⁻³. However, metastasis of colorectal cancer to body-surface lymph nodes, other than inguinal lymph nodes, is rare, and, to our knowledge, metastasis to axillary lymph nodes has not been reported previously. We could not detect any recurrent lesions before the patient discovered swelling of the left axillary lymph nodes. Generally speaking, CT or magnetic resonance is extremely useful for detecting recurrent

lesions⁴. However, detecting recurrence in small lymph nodes is difficult, but positron emission tomography⁵ may be helpful. Increased levels of the tumor marker CEA suggest postoperative recurrence. Diagnosis may be delayed for several months unless the metastatic lymph nodes increase rapidly in size or other sites, such as the lung or liver, are also affected by tumor spread⁶.

Metastasis to the axillary lymph nodes may occur via either hematogenous or lymphovascular routes. Because colic venous flow first reaches the liver through the portal vein, there is no direct communication between the colic venous flow and the axillary lymphatic system. On the other hand, most of the colic lymph flow reaches the left venous angle through the thoracic duct and the chyle cistern. Because anatomical anomalies of the terminal portion of thoracic duct have been reported⁷, the thoracic duct might communicate with the infraclavicular lymphatic system in some patients. Therefore, colon cancer might spread to the axillary lymph nodes by lymph flow through the thoracic duct and the infraclavicular lymphatic system.

REFERENCES

1. Regingold IM. Cutaneous metastases from internal carcinoma. *Cancer* 1966; 19: 162-8.
2. Gates O. Cutaneous metastases of malignant disease. *Am J Cancer* 1937; 30: 718-30.
3. Abrams H, Siro R, Goldshtein N. Metastases in carcinoma: analysis of 1000 autopsied cases. *Cancer* 1950; 3: 74-85.
4. Balzer JO, Luboldt W, Vogl TJ. Importance of CT and MRI in the follow-up of patients with rectal cancer. *Radiologe* 2003; 43: 122-7.
5. Mukai M, Sadahiro S, Yasuda S, Ishida H, Tokunaga N, Tajima T, et al. Preoperative evaluation by whole-body 18F-fluorodeoxyglucose positron emission tomography in patients with primary colorectal cancer. *Oncol Rep* 2000; 7: 85-7.
6. Gmitter TL, Dhawan SS, Phillips MG, Wiszniak J. Cutaneous metastases of colonic adenocarcinoma. *Cutis* 1990; 46: 66-8.
7. Adachi B. In: Kihara T, editor. *Der Ductus thoracicus der Japaner*. Kyoto: University of Kyoto; 1953.