

## Usefulness of the Psoriatic Arthritis Magnetic Resonance Imaging Scoring System for Hands in Evaluation of Therapeutic Effect of Biological Agents in Patients with Psoriatic Arthritis

Akari SADAOKA, Shinjiro TOJO, Takenori YONENAGA, and Kunihiro FUKUDA

*Department of Radiology, The Jikei University School of Medicine*

### ABSTRACT

**Purpose :** To determine the usefulness of the Psoriatic Arthritis (PsA) Magnetic Resonance Imaging (MRI) Scoring System for Hands (PsAMRIS-H) when assessing the response of patients with PsA to biological agents.

**Materials and methods :** The subjects were 10 Japanese patients with PsA (8 men and 2 women ; mean age, 52.3 years) treated with biological agents. Two radiologists independently read and scored contrast-enhanced MRI with the PsAMRIS-H before and 1 to 12 months after treatment and compared these scores with changes in indicators of clinical severity (serum C-reactive protein level and Psoriasis Area Sensitivity Index). The interreader and intrareader reliability of each PsAMRIS-H feature was analyzed by calculating  $\kappa$  values.

**Results :** Serum C-reactive protein levels and Psoriasis Area Sensitivity Index scores decreased after treatment in all 10 patients. The PsAMRIS-H total scores decreased in 9 of the 10 patients. Although  $\kappa$  values for both intrareader and interreader reliability were low for the feature of bone erosion, the reliability was rated as moderate-to-substantial for the other components.

**Conclusion :** The PsAMRIS-H is useful for assessing the efficacy of biological agents in the treatment of PsA. (Jikeikai Med J 2017 ; 64 : 37-44)

**Key words :** magnetic resonance imaging, psoriatic arthritis, biological agents, therapeutic effect

### INTRODUCTION

Psoriasis is a chronic inflammatory skin disease characterized by thick scales and well-demarcated infiltrated erythema covering the affected parts of the body. Psoriasis has a prevalence of approximately 2% in Western countries<sup>1</sup> but of only 0.3% in Japan<sup>2</sup>. However, the prevalence of psoriasis has increased in Japan, probably because lifestyles have been westernized and metabolic syndrome has become more common<sup>3</sup>. Inflammatory arthritis might be asso-

ciated with psoriasis and, if so, is known as psoriatic arthritis (PsA). The reported incidence of PsA varies. Although 7% to 15% of Japanese persons with psoriasis have PsA<sup>4</sup>, the current consensus is that of persons with psoriasis, PsA will develop in approximately 30%<sup>5</sup>. Cases of PsA often occur in persons with skin symptoms. Studies by dermatologists have found that skin symptoms precede joint symptoms in 84% of cases, appear with them in 13% of cases, and follow them in 3% of cases<sup>6</sup>; studies by rheumatologists have found rates of such relationships to be 60%, 20%,

---

Received for publication, May 10, 2017

貞岡亜加里, 東條慎次朗, 米永 健徳, 福田 国彦

Mailing address : Akari SADAOKA, Department of Radiology, The Jikei University School of Medicine, 3-25-8 Nishi-Shimbashi, Minato-ku, Tokyo 105-8461, Japan.

E-mail : akaringo0917@jikei.ac.jp

and 20%<sup>7</sup>.

With the development of biological agents, PsA has become a treatable disease. Therefore, to rapidly start treatment and prevent further damage to affected joints, to quickly diagnose symptoms, and to assesses disease activity in joints have become great interests of research. Although magnetic resonance imaging (MRI) can be used to detect both inflammatory changes (synovitis, tenosynovitis, periarticular inflammation, and bone marrow edema) and structural changes (bone erosion and proliferation), accurately quantifying the treatment effects of biological agents has become necessary for assessing PsA. In 2004, the Outcome Measures in Rheumatology Clinical Trials group started to develop the Psoriatic Arthritis Magnetic Resonance Imaging Scoring System for Hands (PsAMRIS-H) based on the rheumatoid arthritis MRI scoring system. The PsAMRIS-H was revised in 2007 and completed in 2009<sup>8</sup>.

Although the PsAMRIS-H has been found to be useful by studies in Western countries, few such studies have been performed in Japan, where the incidence of PsA is lower. Moreover, a literature search found no studies in Japanese patients with PsA comparing changes in clinical indicators of disease severity, i.e., serum C-reactive protein (CRP) level and the Psoriasis Area Severity Index (PASI) score, with changes in the PsAMRIS-H score. Therefore, the purpose of the present study was to assess the clinical usefulness of the PsAMRIS-H by comparing changes in PsAMRIS-H scores with changes in indicators of clinical severity in response to treatment with biological agents in Japanese patients with PsA.

## MATERIALS and METHODS

### *Study design and patient subjects*

Japanese patients with PsA who had visited the outpatient clinic of the Department of Dermatology, The Jikei University Hospital, from 2011 through 2015 were reviewed. Patients became subjects of the study if they fulfilled the Classification Criteria for Psoriatic Arthritis<sup>9</sup>, had been treated with biological agents (adalimumab or infliximab or both), had undergone contrast-enhanced MRI before and 1 to 12 months after treatment with the biological agents, and had undergone clinical assessment of serum CRP levels and PASI scores 1 month before and after contrast-enhanced MRI. The inclusion criteria were met by 10 patients (8 men and 2 women ; mean age, 52.3 years old). The biological agents administered were adalimumab alone in 3 patients, infliximab alone in 2 patients, and a change between the 2 agents in 5 patients. Three patients (patients 1, 6, and 7) had been included in our earlier study<sup>10</sup>. The protocol of the present study was approved by the ethics committee of our institution.

### *MRI examinations*

The MRI examinations were performed with a 1.5-T MR units (Avanto ; Siemens Healthcare, Erlangen, Germany). To obtain MRI images (Table 1) of the affected hand, a flexible coil (CP Flex Coil, Siemens Healthcare) was used. As the contrast medium, gadopentetate dimeglumine (Omniscan ; GE Healthcare, Little Chalfont, UK) was administered at a dose of 0.1 mmol/kg body weight.

### *Image evaluation*

Two musculoskeletal radiologists independently exam-

Table 1. Magnetic resonance images sequences and variables

MRI parameters	TR (msec)	TE (msec)	TI (msec)	FA (deg)	FOV (mm)	Matrix size	Slice (mm)	TA (sec)
T1WI coro	400	10	—	150	140 × 140	256 × 320	3	1 : 5
FS T1WI coro	555	10	—	150	140 × 140	256 × 320	3	2 : 26
STIR tra	3,000	36	180	160	130 × 130	205 × 256	4	2 : 17
STIR coro	3,000	36	180	160	140 × 140	205 × 256	3	2 : 17
STIR sag	3,000	36	180	160	140 × 140	205 × 256	4	2 : 17
GdFS T1WI tra	570	11	—	150	130 × 130	272 × 320	4	2 : 08
GdFS T1WI coro	555	10	—	150	140 × 140	256 × 320	3	2 : 26
GdFS T1WI sag	570	11	—	150	112 × 140	218 × 320	4	1 : 44

TR : repetition time ; TE : echo time ; TI : inversion time ; FA : flip angle ; FOV : field of view ; TA : acquisition time ; Coro : coronal ; tra : trans ; sag : sagittal ; FS : fat suppression ; STIR : short inversion recovery ; Gd : gadolinium ; WI : weighted image

ined the anonymized images twice within a 3-month interval and scored using the PsAMRIS-H. Reader 1 was author S.T., with 10 years' experience in musculoskeletal radiology, and reader 2 was author A.S., with 3 years' experience. Twelve joints — the distal interphalangeal (DIP), proximal interphalangeal (PIP), and metacarpophalangeal (MCP) joints of the second to fifth fingers — of the imaged hand were assessed and given scores for the following PsAMRIS-H features : synovitis (0-3), flexor tenosynovitis (0-3), periarticular inflammation (0 or 1), bone marrow edema (0-3), bone erosion (0-10), and bone proliferation (0 or 1).

#### Statistical analysis

Interreader and intrareader reliability was calculated with Cohen's weighted  $\kappa$  value. The calculations were performed with the statistical analysis software program Stata

14 (StataCorp, College Station, TX, USA). The prerecorded weight is  $W_2$  in this program, where the weights are given by  $1 - \{(i - j)/(k - 1)\}^2$ . Reliability was assessed with the following scale : almost perfect ( $\kappa$ 0.81-1.00), substantial (0.6-0.80), moderate (0.41-0.60), fair (0.21-0.40), slight (0-0.20), and poor ( $< 0$ ).

## RESULTS

#### Clinical assessment

Ten patients satisfied the inclusion criteria. They were 8 men and 2 women with a median age of 52.3 years old (range, 34 to 80 years old). The mean duration of psoriasis was 9.43 years (range, 6 months to 30 years), and that of PsA was 3.0 years (range, 1 month to 12 years). After being treated with biological agents, all patients showed de-

Table 2. Clinical assessments and psoriatic arthritis magnetic resonance imaging scoring system scores for hands in patients with psoriatic arthritis

Patient	Biological agent	Weeks of treatment	PASI	C-reactive protein (mg/dl)	Scores of Psoriatic arthritis magnetic resonance imaging scoring system for hands features					
					Total	Synovitis	Flexor tenosynovitis	Bone edema	Periarticular inflammation	Bone erosion
1	ADA	0	0.3	2.5	10.5	3.5	3.5	0	2	1.5
		8	0	1.2	11	4.5	3	0	2	1.5
		32	0	0	6.5	4	1.5	0	1	0
2	IFX-ADA	0	2.2	0.74	8.5	2	2	2.5	2	0
		30	1.4	0.31	0.5	0	0.5	0	0	0
3	IFX	0	3.5	2.04	9.5	3	2	2	2.5	0
		24	0.4	0.04	1	1	0	0	0	0
4	IFX-ADA	0	11.2	2.19	6	2.5	1	0	2	0.5
		28	1.2	0.11	1	0	0.5	0	0	0.5
		48	1	0.18	0.5	0	0	0	0	0.5
5	IFX-ADA	0	22.7	1.44	32.5	12	10	4	6	0.5
		8	1.5	0.44	20.5	6	8	1.5	4.5	0.5
		32	1.2	0.06	1.5	0	0.5	0.5	0	0.5
6	ADA	0	11	2.5	2.5	1	1	0	0.5	0
		8	4	0.9	2	0.5	1	0	0.5	0
		24	1.6	0.1	2	0.5	1	0	0.5	0
7	ADA-IFX-ADA	0	10	2.06	24	11	13	0	0	0
		40	0	1.88	8	4	4	0	0	0
8	IFX	0	0.2	0.66	8	2	4.5	0.5	0.5	0.5
		48	0	0.14	0.5	0	0.5	0	0	0
9	ADA	0	3	0.21	1.5	0	1	0	0.5	0
		20	1.2	0.19	0	0	0	0	0	0
10	IFX-ADA	0	0.5	0.21	24.5	4.5	13	3	4	0
		32	0	0.04	1.5	0.5	1	0	0	0

Psoriatic arthritis magnetic resonance imaging scoring system for hands scores are the averages of 2 readers. 0 week is before treatment.

PASI, Psoriasis Area Severity Index ; ADA, adalimumab ; IFX, infliximab

creased serum CRP levels and PASI scores (Table 2).

#### Interreader and intrareader reliability

The interreader reliability (Table 3) was poor for bone erosion, with a low  $\kappa$  value, but was generally good (moderate to substantial) for the other features. The intrareader reliability was also generally good for all features, except bone erosion (Table 4), and was rated as perfect for synovitis. The  $\kappa$  value for bone erosion was low for reader 1.

The interreader reliability (Table 5) was good (substantial to almost perfect) for synovitis in all 3 joints assessed, and the highest  $\kappa$  value was for the DIP joint (0.8196). Although the reliability for flexor tenosynovitis was rated favorably (substantial) in all 3 joints, the  $\kappa$  values were higher in the PIP and DIP joints than in the MCP joint. The reliability for bone marrow edema was poor in the MCP joint but was rated favorably (substantial) in the PIP and DIP joints. However, the reliability for bone erosion was low (slight to poor). Although the reliability for periarticular inflammation was rated as fair to moderate, the  $\kappa$  values in the PIP and DIP joints were higher than in the MCP joint.

#### PsAMRIS-H scores

After being treated with a biological agent, all patients showed decreased PsAMRIS-H total scores, serum CRP levels, and PASI scores (Table 1, Fig. 2). When these variables were plotted on line graphs, their fluctuations followed a similar pattern, whereby numeric values had decreased steeply by the first posttreatment assessment, with a lesser decrease seen at the second assessment (Fig. 1). However, in patient 1, a decrease to 0 was not observed for the PsAMRIS-H total score but was observed for both the PASI score and the serum CRP level. In patient 6, the PsAMRIS-H total score decreased more slowly than did the PASI score and the serum CRP level, revealing that MRI findings improved more slowly than did clinical findings.

When the PsAMRIS-H scores were analyzed in detail according to each variable, they were decreased in all patients with synovitis (except for patient 1). The scores for flexor tenosynovitis and bone marrow edema decreased after treatment in all patients. The score for periarticular inflammation decreased after treatment in all patients, except for a patient (patient 6) in whom it remained unchanged.

Table 3. Interreader reliability of the Psoriatic Arthritis Magnetic Resonance Imaging Scoring System for Hands

Features	Weighted kappa	
	Reader 1	Reader 2
Synovitis	0.7446	0.777
Flexor tenosynovitis	0.7027	0.6979
Bone marrow edema	0.4895	0.7935
Bone erosion	-0.0141	-0.0108
Periarticular inflammation (volar)	0.6692	0.3933
Periarticular inflammation (dorsal)	0.5524	0.4562

Weighted kappa was calculated from the scores of 2 readers. Kappa in interpreted as follows : almost perfect : 0.81-1.00 ; substantial : 0.61-0.80 ; moderate : 0.41-0.60 ; fair : 0.21-0.40 ; slight : 0-0.20 ; poor : < 0

Table 4. Intrareader reliability of the Psoriatic Arthritis Magnetic Resonance Imaging Scoring System for Hands

Features	Weighted kappa	
	Reader 1	Reader 2
Synovitis	0.8008	0.8086
Flexor tenosynovitis	0.659	0.7957
Bone marrow edema	0.5947	0.7411
Bone erosion	0.3898	1
Periarticular inflammation (volar)	0.4781	0.5977
Periarticular inflammation (dorsal)	0.5853	0.4828

Weighted kappa was calculated from the scores of 2 readers. Kappa in interpreted as follows : almost perfect : 0.81-1.00 ; substantial : 0.61-0.80 ; moderate : 0.41-0.60 ; fair : 0.21-0.40 ; slight : 0-0.20 ; poor : < 0

Table 5. Interobserver reliability for each joint

Joint	Synovitis	Tenosynovitis	Bone edema	Bone erosion	Periarticular inflammation (volar)	Periarticular inflammation (dorsal)
Metacarpophalangeal	0.7427	0.64145	-0.01065	0	0.51585	0.31955
Proximal interphalangeal	0.74165	0.7358	0.6921	-0.00975	0.51505	0.61655
Distal interphalangeal	0.8196	0.734	0.6201	NA	0.5381	0.6076

Weighted kappa was calculated from the scores of 2 readers. Kappa in interpreted as follows : almost perfect : 0.81-1.00 ; substantial : 0.61-0.80 ; moderate : 0.41-0.60 ; fair : 0.21-0.40 ; slight : 0-0.20 ; poor : < 0

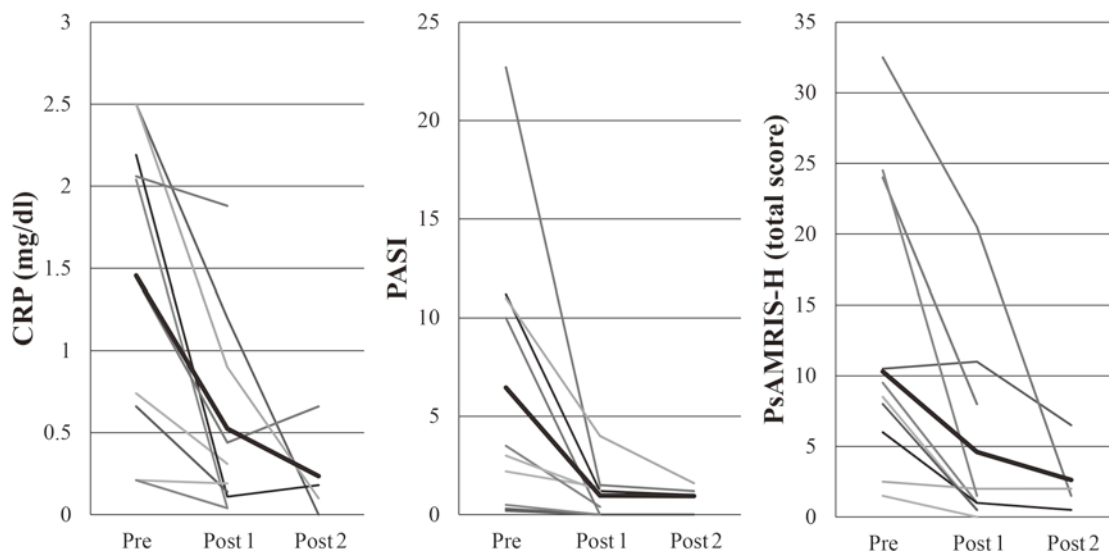


Fig. 1. Serum C-reactive protein (CRP) levels, Psoriasis Area Sensitivity Index (PASI) scores, and Psoriatic Arthritis Magnetic Resonance Imaging Scoring System for Hands (PsAMRIS-H) total scores both before treatment (Pre) and after 1 month of treatment (Post 1) and 12 months of treatment (Post 2) were plotted on line graphs. For each variable, the 10 gray lines represent individual patients, and the black line is the average score of the 10 patients.

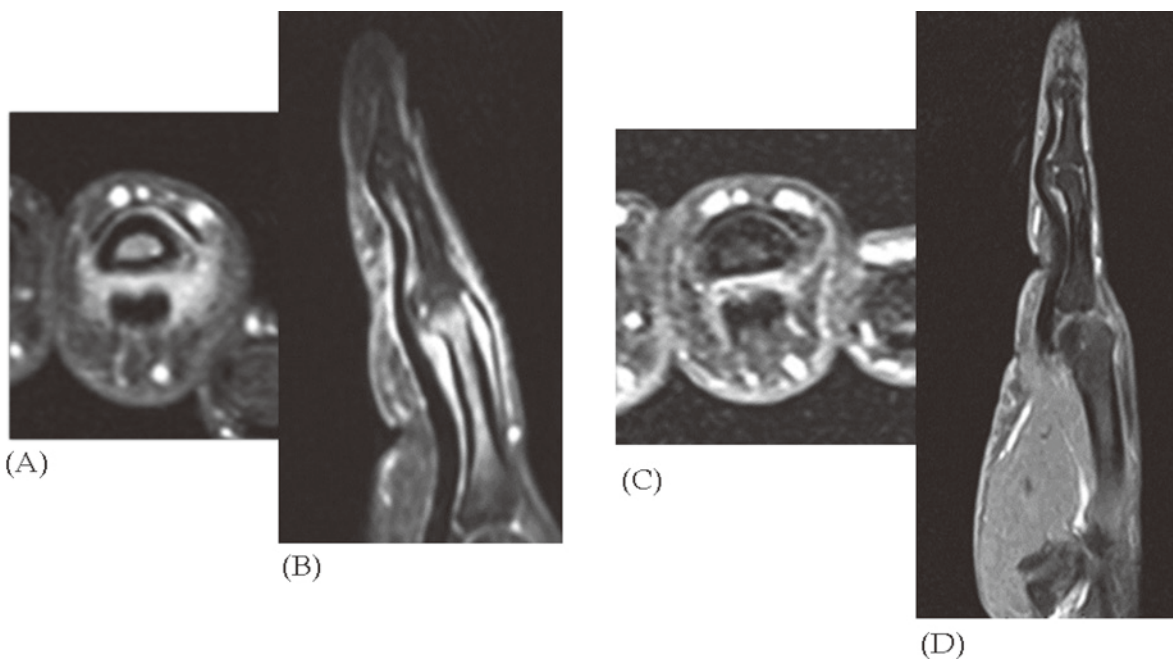


Fig. 2. A 37-year-old Japanese man (patient 2) with pain and swelling of the right fourth finger. The biological agent was first infliximab and was then changed to adalimumab. Contrast-enhanced T1-weighted images with fat suppression left, axial right, and sagittal. (A) (B) Before treatment. There is moderate enhancement around the proximal interphalangeal (PIP) joint (synovitis ; score = 2). There is a slight enhancement along the tendon sheath at the PIP joint (tenosynovitis ; score = 1). There is a high signal in the proximal phalanx (bone marrow edema ; score = 3). (C)(D) Six months after treatment. There was little enhancement around the PIP joint (synovitis ; score = 1). The slight enhancement along the tendon sheath at the PIP joint had disappeared (tenosynovitis : score = 0). The high signal in the proximal phalanx is disappeared (bone marrow edema ; score = 0).

Bone erosion was detected in 4 patients, 2 of whom showed no change in scores after treatment (the posttreatment image could not be assessed in patient 1 because of distortion). Bone proliferation was not observed in any patient.

## DISCUSSION

In the present study, Japanese patients with PsA who had been treated with biological agents showed improved PsAMRIS-H scores that corresponded with improved PASI scores and serum CRP levels, which reflect clinical severity. However, PsAMRIS-H scores did not decrease to 0 in a patient (patient 1) in whom the PASI score and serum CRP level did decrease to 0. The PsAMRIS-H scores did not reach 0 for synovitis, flexor tenosynovitis, or periarticular inflammation. Our recent study evaluated, by means of the PsAMRIS-H, the effects of adalimumab in 5 Japanese patients with PsA and found that MRI findings for synovitis and flexor tenosynovitis improved more slowly than did those for bone marrow edema<sup>10</sup>. A study that had used MRI to assess the effects of adalimumab in 15 patients with PsA suggested that the findings for bone marrow edema were a suitable biomarker of treatment because improvement in MRI findings for bone marrow edema was earlier than that for synovitis. However, residual inflammatory activity might be present even in patients with clinical remission of PsA<sup>11</sup>. An additional study indicated that inflammatory changes of synovitis, flexor tenosynovitis, and periarticular inflammation were improved by treatment with biological agents but persisted on MRI images<sup>12</sup>.

A similar discrepancy between clinical findings and MRI findings in response to treatment has been reported in patients with rheumatoid arthritis. One study has found that MRI performed 1 year after clinical remission showed synovitis in 94.6% of patients, bone marrow edema in 58.6%, and flexor tenosynovitis in 58.9% and suggest that evidence of active inflammation persists on MRI images in such patients<sup>13</sup>. In a study of 14 patients with rheumatoid arthritis in clinical remission who had undergone surgical synovectomy, histopathologic examination of the specimens of resected synovial membrane revealed severe inflammation in 4 patients, moderate inflammation in 6 patients, mild inflammation in 3 patients, and minimal inflammation in 2 patients. However, MRI revealed synovitis and bone marrow edema in 86% of these patients. This study suggested that

both histopathologic and imaging findings indicate residual active inflammation even after clinical remission<sup>14</sup>. A similar study of asymptomatic patients with rheumatoid arthritis in clinical remission found that MRI revealed synovitis in 96% and bone marrow edema in 46%<sup>15</sup>. In resected synovial membrane specimens obtained from patients in clinical remission, MRI and ultrasonography revealed hyperplasia accompanied by invasion of inflammatory cells, proliferation of interstitial cells, and angiogenesis associated with abnormal signals. Persistent active synovitis is believed to cause joint destruction<sup>14,15</sup>. Thus, treatment with biological agents should be continued even after clinical remission is achieved<sup>16</sup>. In the present study, inflammatory findings of synovitis, flexor tenosynovitis, and periarticular inflammation persisted in 2 patients (patients 1 and 6). Because persistent inflammation might result in joint destruction, we believe that treatment and regular imaging assessment, including scoring, should be continued.

The area targeted by the PsAMRIS-H is limited to the DIP, PIP, and MCP joints of the second through fifth fingers of the hand; therefore, the PsAMRIS-H scores might be dissociated from other variables, such as PASI scores and serum CRP levels, used to assess clinical severity. How joints outside the target area should be evaluated for the PsAMRIS-H is unclear. The usefulness of the PsAMRIS-H is attributed to its ability to evaluate joints other than those of the hands and feet, and research is underway to adjust the scoring system for use at other joints<sup>17</sup>.

Previous studies indicate that the interreader and intrareader reliability of the PsAMRIS-H is good<sup>18</sup> and suggest that the scoring system is useful for quantifying the effects of treatment for PsA. However, low reliability has been reported for periarticular inflammation in the PIP joint and, particularly, in the DIP joint<sup>18-21</sup>. In the present study, the interreader reliability for periarticular (volar) inflammation was also poor at the second assessment ( $\kappa$  value of 0.3933). Low reliability for bone changes (bone erosion, bone proliferation), as found in the present study, has also been found in earlier studies<sup>18,19</sup>. These studies have indicated that typical findings of periarticular inflammation and bone proliferation in PsA are not sufficiently recognized<sup>18,19</sup> and that the small size of the PIP joint and, particularly, the DIP joint makes their cross-sectional images difficult to read and score<sup>20</sup>. A cross-sectional study of the PsAMRIS-H performed at 2 institutions found that reliability for peri-

articular inflammation after a second trial exercise was as low as that after a first trial exercise<sup>22</sup>; however, reliability was markedly improved after a third trial exercise<sup>17</sup>. This improvement has been attributed to the images being read to assess the PsAMRIS-H features in the same sequence and the readers being trained to improve their reading skills<sup>20</sup>. Thus, to improve interreader reliability, readers should be trained to perform scoring and to share a common knowledge of PsAMRIS-H features.

Furthermore, MRI of the DIP and PIP joints, which are common sites for PsA, is susceptible to artifacts because of the large areas exposed to air, and the low spatial resolution of MRI makes peripheral small joints difficult to assess. A study assessing PsAMRIS-H scores in 40 patients with PsA before treatment and after 6 months of treatment attributed their low posttreatment responses at the DIP joint to the difficulty in scoring because of the low image quality for small joints, indicating that higher resolution is necessary to improve the accuracy of scoring for the small joints of the hands and feet<sup>19</sup>. At our hospital, we perform 3-mm-slice imaging with a 1.5-T MR unit. However, imaging with a 3-T MR unit is suitable because as the static magnetic field strength increases, the signal-to-noise ratio increases by approximately 50%, while the longitudinal relaxation time (T1) is prolonged. Because of the prolonged T1 time, contrast enhancement is improved when a contrast medium that shortens the T1 time (such as gadolinium) is used.

Moreover, use of 3-dimensional volumetric interpolated breath-hold examination (3D VIBE) improves resolution, and 3D imaging provides genuine 3D cross sections, which can be expected to further improve the reliability of scoring. When we reviewed the literature, a study using 3D VIBE with a 1.5-T MR unit to assess bone changes in 28 patients with PsA showed that the reliability of scoring for bone erosion and bone marrow edema was high, with intraclass correlation coefficients of 0.80 and 0.77, respectively<sup>23</sup>. In a study performing coronal 3D VIBE with a 1.5-T or 3-T MR unit to investigate the morbidity of interosseous tendon tenosynovitis of the hand in 24 patients with rheumatoid arthritis, interreader agreement was good, with a  $\kappa$  value of 0.91 for interosseous tendon tenosynovitis, 0.84 for synovitis of the MCP joint, and 0.84 for flexor tendon tenosynovitis<sup>24</sup>. In a study of 3D VIBE with a 1.5-T whole-body MRI unit performed in 30 patients with PsA to determine whether whole-body MRI is useful and can provide additional in-

formation for determining of treatment strategies, 2 experienced radiologists rated the quality of images of the peripheral joints in the hands and feet as good in 16 patients (53%)<sup>25</sup>.

The present study had several limitations. First, because this study was retrospective, the collection of patients might have been selectively biased. However, we believe that we were able to avoid any substantial bias by setting the inclusion criteria before starting this retrospective study. A second limitation was that the statistical reliability of this study was low because few patients were included. The incidence of psoriasis is so low in Japan that few eligible patients were included as subjects. A multicenter study would be needed to resolve this problem. A third limitation of the present study was that the interval between treatment and MRI examination was relatively long. Three patients (patients 1, 5, and 6) were assessed 8 weeks after being treated, and both PASI scores and serum CRP levels were markedly improved at that time in all patients. Biological agents are expected to quickly exert their effects. Therefore, if the patients had been examined immediately or less than 8 weeks after being treated, early changes might have been more accurately assessed. However, our study confirmed that the PsAMRIS-H is useful for examining Japanese patients with PsA treated with biological agents.

## CONCLUSIONS

The present study found that Japanese patients with PsA treated with biological agents showed corresponding decreases in PsAMRIS-H total scores and indicators of clinical severity. Therefore, PsAMRIS-H is useful for assessing the efficacy of these agents for the treatment of PsA.

## REFERENCES

1. Schön MP, Boehncke WH. Psoriasis. *N Engl J Med*. 2005; 352: 1899-912.
2. Kubota K, Kamijima Y, Sato T, Ooba N, Koide D, Iizuka H, et al. Epidemiology of psoriasis and palmoplantar pustulosis: a nationwide study using the Japanese national claims database. *BMJ Open*. 2015; 5: e006450.
3. Kobayashi S. Psoriatic arthritis (in Japanese). *Shin Ryoikibetsu Shokogun Shirizu (New Series on symptomatic syndrome by area)*. 2015; 34: 683-93.
4. Ueno M. Rheumatoid Arthritis and seronegative spondyloar-

- thropathy (in Japanese). *Riumachibyō Shinryo bijuaru tekisuto* (Visual textbook of rheumatic disease). 2nd ed. Tokyo: Igakushoin; 2008. p. 121-68.
5. Gladman DD. Psoriatic arthritis. *Dermatol Ther.* 2009; 22 : 40-55.
  6. Gottlieb AB, Mease PJ, Jackson JM, Eisen D, Amy Xia H, Asare C, et al. Clinical characteristics of psoriatic arthritis and psoriasis in dermatologists' offices. *J Dermatol Treat.* 2006; 17 : 279-87.
  7. Veale DJ, Rogers S, Fitzgerald O. Classification of clinical subsets in psoriatic arthritis. *Br J Rheumatol.* 1994; 33 : 133-8.
  8. Østergaard M, McQueen F, Wiell C, Bird P, Bøyesen P, Ejbjerg B, et al. The OMERACT psoriatic arthritis magnetic resonance imaging scoring system (PsAMRIS): definitions of key pathologies, suggested MRI sequences, and preliminary scoring system for PsA Hands. *J Rheumatol.* 2009; 36 : 1816-24.
  9. Taylor W, Gladman D, Helliwell P, Marchesoni A, Mease P, Mielants H, et al. Classification criteria for psoriatic arthritis: Development of new criteria from a large international study. *Arthritis Rheum.* 2006; 54 : 2665-73.
  10. Yanaba K, Sadaoka A, Yonenaga T, Saeki H, Umezawa Y, Tojo S, et al. Adalimumab markedly improves enthesitis in patients with psoriatic arthritis: Evaluation with a magnetic resonance imaging scoring system. *J Dermatol.* 2015; 42 : 1153-9.
  11. Anandarajah AP, Ory P, Salonen D, Feng C, Wong RL, Ritchlin CT. Effect of adalimumab on joint disease: features of patients with psoriatic arthritis detected by magnetic resonance imaging. *Ann Rheum Dis.* 2010; 69 : 206-9.
  12. Poggenborg RP, Wiell C, Bøyesen P, Boonen A, Bird P, Pedersen SJ, et al. No overall damage progression despite persistent inflammation in adalimumab-treated psoriatic arthritis patients: results from an investigator-initiated 48-week comparative magnetic resonance imaging, computed tomography and radiography trial. *Rheumatology (Oxford).* 2014; 53 : 746-56.
  13. Lisbona MP, Pàmies A, Ares J, Almirall M, Navallas M, Solano A, et al. Association of bone edema with the progression of bone erosive quantified by hand magnetic resonance imaging in patients with rheumatoid arthritis in remission. *J Rheumatol.* 2014; 41 : 1623-9.
  14. Anandarajah A, Thiele R, Giampoli E, Monu J, Seo GS, Feng C, et al. Patients with rheumatoid arthritis in clinical remission manifest persistent joint inflammation on histology and imaging studies. *J Rheumatol.* 2014; 41 : 2153-60.
  15. Brown AK, Quinn MA, Karim Z, Conaghan PG, Peterfy CG, Hensor E, et al. Presence of significant synovitis in rheumatoid arthritis patients with disease-modifying antirheumatic drug-induced clinical remission. *Arthritis Rheum.* 2006; 54 : 3761-73.
  16. Wakefield RJ, Freeston JE, Hensor EMA, Bryer D, Quinn MA, Emery P. Delay in imaging versus clinical response: a rationale for prolonged treatment with anti-tumor necrosis factor medication in early rheumatoid arthritis. *Arthritis Rheum.* 2007; 57 : 1564-7.
  17. Østergaard M, Glinatsi D, Pedersen SJ, Sørensen IJ. Utility in clinical trials of magnetic resonance imaging for psoriatic arthritis: a report from the GRAPPA 2014 Annual Meeting. *J Rheumatol.* 2015; 42 : 1044-7.
  18. Bøyesen P, McQueen FM, Gandjbakhch F, Lillegraven S, Coates L, Wiell C, et al. The OMERACT Psoriatic Arthritis Magnetic Resonance Imaging Score (PsAMRIS) is reliable and sensitive to change: results from an OMERACT Workshop. *J Rheumatol.* 2011; 38 : 2034-8.
  19. Glinatsi D, Bird P, Gandjbakhch F, Mease PJ, Bøyesen P, Peterfy CG, et al. Validation of the OMERACT Psoriatic Arthritis Magnetic Resonance Imaging Score (PsAMRIS) for the Hand and Foot in a Randomized Placebo-controlled Trial. *J Rheumatol.* 2015; 42 : 2473-9.
  20. McQueen F, Lassere M, Duer-Jensen A, Wiell C, Conaghan PG, Gandjbakhch F, et al. Testing an OMERACT MRI scoring system for peripheral psoriatic arthritis in cross-sectional and longitudinal settings. *J Rheumatol.* 2009; 36 : 1811-5.
  21. Strube H, Becker-Gaab C, Saam T, Reiser M, Schewe S, Schulze-Koops H, et al. Feasibility and reproducibility of the PsAMRIS-H score for psoriatic arthritis in low-field-strength dedicated extremity magnetic resonance imaging. *Scand J Rheumatol.* 2013; 42 : 379-82.
  22. McQueen F, Lassere M, Bird P, Haavardsholm EA, Peterfy C, Conaghan PG, et al. Developing a magnetic resonance imaging scoring system for peripheral psoriatic arthritis. *J Rheumatol.* 2007; 34 : 859-61.
  23. Tan YM, Østergaard M, Doyle A, Dalbeth N, Lobo M, Reeves Q, et al. MRI bone oedema scores are higher in the arthritis mutilans form of psoriatic arthritis and correlate with high radiographic scores for joint damage. *Arthritis Res Ther.* 2009; 11 : R2.
  24. Rowbotham EL, Freeston JE, Emery P, Grainger AJ, et al. The prevalence of tenosynovitis of the interosseous tendons of the hand in patients with rheumatoid arthritis. *Eur Radiol.* 2016; 26 : 444-50.
  25. Weckbach S, Schewe S, Michaely HJ, Steffinger D, Reiser MF, Glaser C. Whole-body MR imaging in psoriatic arthritis: Additional value for therapeutic decision making. *Eur J Radiol.* 2011; 77 : 149-55.