

# Hemodynamic and Cardiac Motion Analyses in an Experimental Model of Off-pump Coronary Bypass Surgery

— Effects of Stabilizer and Heart Positioner —

Shinichi ISHII, Ryuichi NAGAHORI, Motohiro OSHIUMI, Hiroshi OKUYAMA,  
Yoshimasa SAKAMOTO, Kiyozo MORITA, and Kazuhiro HASHIMOTO

*Department of Cardiovascular Surgery, The Jikei University School of Medicine*

## ABSTRACT

**Objective:** During off-pump bypass surgery, it is most important to prevent hemodynamic deterioration. However, the precise mechanism underlying hemodynamic changes has not been clarified and information regarding regional cardiac wall motion is lacking.

**Methods:** Twelve Landrace pigs were used to study the effect of volume loading (Study 1,  $n=6$ ) and infusion of norepinephrine (Study 2,  $n=6$ ). We evaluated various hemodynamic parameters and regional cardiac wall motion, while using a heart stabilizer and exposing each target vessel with or without a heart positioner. A digital two-dimensional sonomicrometer was used to evaluate regional cardiac motion.

**Results:** Study 1 (under volume loading): 1) For the left anterior descending artery (LAD) anastomosis: No significant changes were noted in any of the parameters. 2) For the left circumflex artery (Cx) anastomosis: Arterial pressure (AP) and right ventricular end-diastolic volume (RVEDV) decreased compared with the baseline level ( $P<0.001\sim 0.05$ ). 3) For the posterior descending artery (PD) anastomosis: AP decreased compared with the baseline value ( $P<0.01$ ), but no significant change of RVEDV was recognized. Use of a positioner ameliorated the decrease of AP at the Cx ( $P<0.05$ ), but reduced segmental shortening (%) in the LAD territory when the heart was made vertical for exposure of the Cx ( $P<0.05$ ) and the PD ( $P=0.06$ ). Study 2 (under volume loading with norepinephrine infusion). After the administration of norepinephrine, there were no significant changes of any parameters or regional wall motion in any territory.

**Conclusion:** 1) Various hemodynamic parameters were useful for monitoring, but RVEDV seems to be an excellent parameter for monitoring volume loading. 2) Adequate volume loading in combination with norepinephrine should be considered at appropriate times, before exposure of the Cx or PD. 3) A heart positioner reduced the decrease of AP, but its effect on regional wall motion was unsatisfactory. (Jikeikai Med J 2005; 52: 93-101)

**Key words:** coronary artery bypass surgery, off-pump coronary bypass surgery, hemodynamics

## INTRODUCTION

Coronary bypass surgery under cardiopulmonary bypass (CPB) is a safe procedure for the treatment of

ischemic heart disease. However, use of CPB is known to induce activation of the proteolytic and inflammatory systems, as well as consumption of clotting factors and platelets<sup>1</sup>. Procedures that do

---

Received for publication, June 10, 2005

石井 信一, 長堀 隆一, 鴛海 元博, 奥山 浩, 坂本 吉正, 森田紀代造, 橋本 和弘

Mailing address: Kazuhiro HASHIMOTO, Department of Cardiovascular Surgery, The Jikei University School of Medicine, 3-25-8, Nishi-shimbashi, Minato-ku, Tokyo 105-8461, Japan.

E-mail: kaz-hashii@jikei.ac.jp

not use CPB are likely to avoid these unwanted effects. Several off-pump coronary bypass surgery (OPCAB) series, in which CPB was not used during coronary bypass surgery, have been reported since early 1980s<sup>2-5</sup>. Application of OPCAB resulted in reduced cardiac enzyme release, reduced use of blood products, and a slightly shorter hospital stay<sup>6,7</sup>. However, to achieve the full benefit of OPCAB,

hemodynamic stability is mandatory, particularly when vertical displacement of the heart is required to achieve optimal exposure of the circumflex artery (Cx) and posterior descending artery (PD). To facilitate access to the target vessels, numerous positioning techniques<sup>8</sup> and devices have been developed, which include deep pericardial sutures (Lima sutures; Fig. 1)<sup>9</sup>, surgical pads, cardiac positioning devices (Fig. 2),

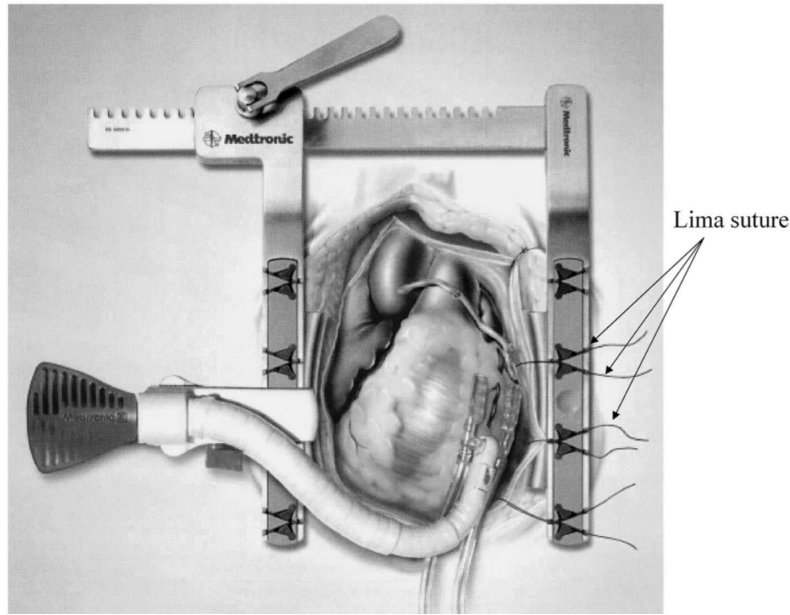


Fig. 1

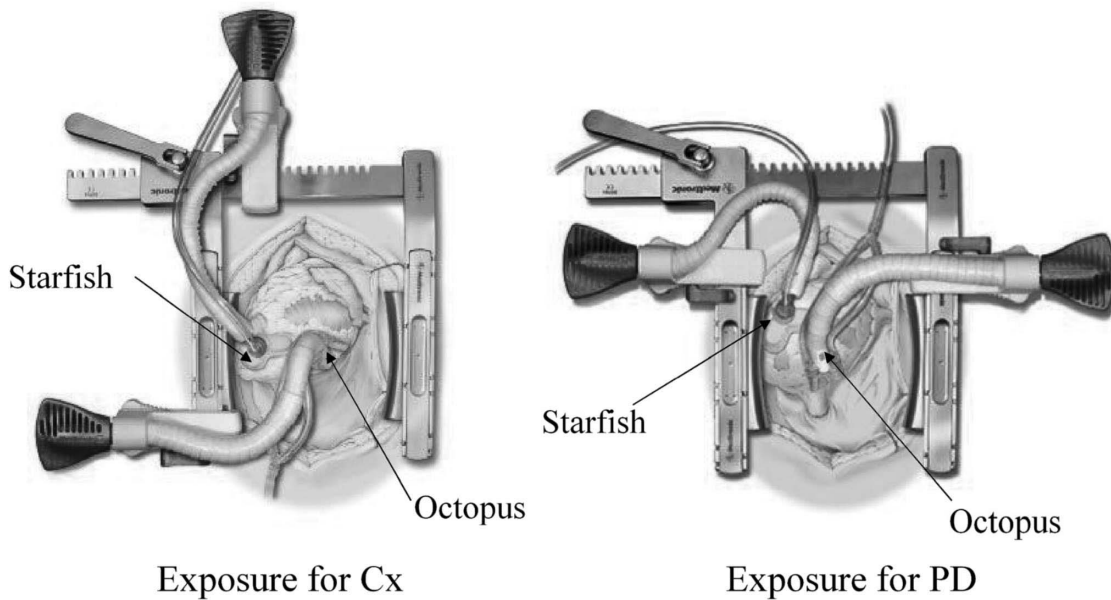


Fig. 2

and various types of cardiac stabilizers (Fig. 2). These devices have expanded the performance of OPCAB<sup>10,11</sup>, with excellent results. However, a detailed hemodynamic study has not been performed during OPCAB and uncertainties about the hemodynamic changes still exist.

Vertical displacement causes significant hemodynamic instability, which manifests as a reduction of stroke volume and arterial blood pressure. In order to prevent these deteriorations, several investigations have been performed<sup>12-14</sup>. However, it has not been well established how to prevent hemodynamic deterioration. Furthermore, little information is available regarding the change of regional cardiac wall motion.

In the experimental setting, we evaluated hemodynamic changes during OPCAB by monitoring various parameters, including continuous right ventricular end-diastolic volume, while using an Octopus stabilizer (Medtronic, Fig. 2) and exposing each target vessel with or without the Starfish heart positioner (Medtronic, Fig. 2). In addition, a digital two-dimensional sonomicrometer (Sono Metrics) was used to evaluate regional cardiac wall motion.

### SUBJECT AND METHODS

Twelve Landrace pigs (weight: 45-55 kg) were used in this study. The animals were divided into two experimental groups.

#### *Operative procedure and experimental setup*

After fasting for 24 hours, general anesthesia was induced with 10 mg/kg of ketamine intramuscularly. Volume-controlled ventilation was started with a 1 : 1 mixture of oxygen and room air, as well as inhalation of 3% sevoflurane after endotracheal intubation. The external electrocardiogram was recorded continuously to monitor the heart rate (HR) and rhythm. Under general anesthesia, each pig was placed in the supine position. A Swan-Ganz catheter (continuous end-diastolic volume thermodilution catheter 774HF75; Edwards Life Sciences) was introduced via the right internal jugular vein for measurement of the mean central venous pressure (CVP), mean pulmonary

artery pressure (PAP), cardiac output (CO), right ventricular end-diastolic volume (RVEDV), stroke volume (SV), right ventricular ejection fraction (EF), and mixed venous blood oxygen saturation (SVO<sub>2</sub>). Principle of measuring of RVEDV, SV and EF was introduced in the previous literature<sup>15</sup>. For measurement of mean arterial blood pressure (AP), an 8 Fr sheath was inserted into the right femoral artery.

After median sternotomy, the pericardium was opened and the heart was suspended. To prevent the onset of ventricular arrhythmia, 1 mg/kg of lidocaine hydrochloride was injected intravenously on opening of the pericardial sac, and continuous infusion was performed at the rate of 1 mg/kg/hour. To evaluate regional cardiac motion with a digital two-dimensional sonomicrometer, four ultrasonic crystals were fixed on the surface of the heart (one pair of crystals in the right and left side of the left anterior descending artery (LAD) and another pair of crystals near the Cx). This system allowed us to calculate segmental shortening (SS%) to assess regional cardiac wall motion. For calculation of SS%, we used the following equation:  $SS\% = (SL(ED) - SL(ES)) / SL(ED)$ , where SL is segment length, ED is end-diastolic length, and ES is end-systolic length. After hemodynamic stability was attained, baseline data were collected, including HR, AP, CVP, PAP, CO, RVEDV, SV, EF, SVO<sub>2</sub>, and SS%.

Then the heart was positioned to expose each target vessel with or without using the Starfish (Fig. 2). The LAD was exposed by placing a sponge under the left side of the heart. When the Starfish was not used to position the heart vertically, deep pericardial sutures (Lima sutures, Fig. 1) were used for exposure of both Cx and PD. One suture was placed just below the left lower pulmonary vein, and two other sutures were placed on the diaphragmatic surface of the pericardium near the inferior vena cava and halfway between the previous two sutures. After hemodynamics became stable, data were collected. Then the Octopus stabilizer (Fig. 2) was positioned around a target vessel corresponding to #7, #4 or #12 (or 14) to obtain the optimum setting for sham coronary anastomosis and the same measurements were repeated. In both Study 1 and Study 2, the

target vessels were not occluded during measurement and anastomosis was not actually carried out. An adequate interval (at least 10 minutes) was allowed between measurements in various settings to minimize the effect of the previous setting.

Study 1: Effect of simple volume loading: After adequate volume loading with one liter of saline following induction of anesthesia, infusion of normal saline at 10 ml/kg/hour was continued intravenously from the start of the operation. In study 1, inotropic agents were not used for the treatment of a decrease in arterial pressure or other hemodynamic changes. Based on the assumption that adequate volume loading had been performed, no additional volume loading was done, even when hemodynamic deterioration was observed.

Study 2: Effect of norepinephrine under volume loading: Norepinephrine (0.05  $\mu\text{g}/\text{kg}/\text{min}$ ) was infused during exposure of the Cx or the PD under volume loading by the same protocol as in study 1. This experiment was designed to evaluate the preventive effect of norepinephrine on hemodynamic deterioration in the presence of adequate volume loading.

All animals received humane care in compliance with the "Guide for the Care Use of Laboratory Animals" published by the National Institutes of Health (NIH publication 85-25, revised in 1985).

#### Statistical analysis

Continuous variables are expressed as the mean  $\pm$  standard deviation. The paired *t*-test (LAD territory) and repeated measures ANOVA with Fisher's post-hoc test (Cx and PD territories) were used to assess the statistical significance of differences between baseline values and data obtained during vertical displacement and stabilization of the heart. In addition, the unpaired *t*-test was used for comparison between two groups at baseline. In all analyses,  $P < 0.05$  was considered significant.

## RESULTS

### Study 1 (Effect of simple volume loading) ( $N = 6$ )

Hemodynamics changes are summarized in Table 1.

1) For LAD anastomosis. (stabilization with the Octopus in placing a sponge under the left side of the heart)

No significant changes were noted in any of the parameters (HR, AP, PAP, CVP, CO, RVEDV, SV, EF, and  $\text{SVO}_2$ ).

2) For Cx anastomosis

(I) Positioning with the Starfish and stabilization with the Octopus

a) Positioning: AP decreased from  $87 \pm 9$  mmHg (baseline) to  $64 \pm 6$  mmHg (positioning) ( $P < 0.001$ ) and PAP decreased from  $25 \pm 3$  mmHg (baseline) to  $21 \pm 2$  mmHg (positioning) ( $P < 0.05$ ). However, the other parameters did not show any significant changes.

b) Addition of stabilization: When the Octopus was set, there were no significant changes of the parameters, except that RVEDV showed a significant decrease ( $P < 0.05$ ) from  $163 \pm 15$  ml (baseline) to  $140 \pm 15$  ml after stabilization. The deterioration of AP and PAP ( $P < 0.05-0.001$ ) was consistently observed compared with the baseline values.

(II) Positioning with deep pericardial stitches (without the Starfish) and stabilization with the Octopus

a) Positioning: AP decreased from  $80 \pm 5$  (baseline) mmHg to  $60 \pm 5$  mmHg (positioning) ( $P < 0.001$ ) and CO decreased from  $4.3 \pm 0.7$  l/min (baseline) to  $3.5 \pm 0.7$  l/min (positioning) ( $P < 0.05$ ), but the other parameters did not show significant changes.

b) Addition of stabilization: Only AP decreased further from  $60 \pm 5$  mmHg (positioning) to  $52 \pm 6$  mmHg (stabilization) ( $P < 0.05$ ) after the addition of stabilization. Compared with the data obtained at baseline, deterioration of CO, SV, and  $\text{SVO}_2$  became obvious ( $P < 0.05-0.001$ ), and there was a decrease of RVEDV from  $166 \pm 35$  ml (baseline) to  $136 \pm 16$  ml (stabilization) ( $P < 0.05$ ).

3) For PD anastomosis

(I) Positioning with the Starfish and stabilization with the Octopus

a) Positioning: After positioning, only AP decreased from  $87 \pm 7$  mmHg (baseline) to  $73 \pm 9$  mmHg (positioning) ( $P < 0.01$ ), while the other parameters showed no significant changes.

b) Addition of stabilization: Although significant changes of AP were still detected compared with

Table 1. Analysis of hemodynamic changes (under volume loading : study 1)

Target vessel	Time of measurements	HR (beats/min)	AP (mmHg)	PAP (mmHg)	CVP (mmHg)	CO (l/min)	RVEDV (ml)	SV (ml)	EF (%)	SVO <sub>2</sub> (%)
LAD ( <i>n</i> =6)	baseline	82±11	89±9	25±4	6±3	4.3±0.9	169±25	53±10	34±6	86±5
	stabilization OP (+)	85±14	77±10	24±2	6±3	4.1±0.4	161±23	48±6	32±5	83±7
Cx ( <i>n</i> =6)	baseline	82±11	87±9	25±3	6±3	4.2±0.6	163±15	52±8	32±5	86±5
	positioning SF (+)	82±14	64±6***	21±2*	8±2	3.4±1.1	143±19	42±11	31±6	80±5
	stabilization OP (+)	82±15	60±6***	21±2*	8±2	3.3±0.9	140±15*	41±10	32±6	78±7
	baseline	77±8	80±5	24±3	6±3	4.3±0.7	166±35	57±13	31±3	86±5
PD ( <i>n</i> =6)	positioning SF (-)	76±10	60±5***	21±4	7±2	3.5±0.7*	153±17	46±9	31±4	80±5
	stabilization OP (+)	76±13	52±6***#	19±3	8±2	2.8±0.4***	136±16*	38±5**	30±3	76±6**
	baseline	80±11	87±7	23±3	6±3	4.4±1.1	168±38	56±15	33±5	87±5
	positioning SF (+)	84±12	73±9**	23±2	6±3	4.1±0.9	171±45	49±13	32±5	84±4
PD ( <i>n</i> =6)	stabilization OP (+)	85±13	65±4***	23±3	7±3	3.9±0.8	172±47	47±11	30±5	81±6
	baseline	81±17	82±8	23±5	6±3	4.1±0.8	177±29	53±14	31±5	87±4
	positioning SF (-)	84±15	63±7***	22±3	7±2	3.3±0.5*	157±30	40±7*	28±3	83±6
	stabilization OP (+)	84±17	60±7***	21±2	7±2	3.0±0.5**	155±29	36±4**	26±2	80±4

\**P*<0.05 \*\**P*<0.01 \*\*\**P*<0.001 vs. baseline #*P*<0.05 vs. positioning

LAD; left anterior descending, Cx; circumflex, PD; posterior descending, OP; Octopus, SF; Starfish  
 HR; heart rate, AP; mean arterial pressure, PAP; mean pulmonary artery pressure,  
 CVP; central venous pressure (mean), CO; cardiac output, RVEDV; right ventricular end-diastolic volume,  
 SV; stroke volume, EF; ejection fraction, SVO<sub>2</sub>; mixed venous oxygen saturation

Time of measurements; Hemodynamic parameters at LAD anastomosis were first measured before displacement of the heart (baseline), then during stabilization with the Octopus. Measurements for the Cx or PD anastomosis were firstly performed before displacement of the heart (baseline), then during positioning with the Starfish, and finally during stabilization with the Octopus.

baseline, no significant further changes were observed after setting of the Octopus stabilizer.

(II) Positioning with deep pericardial stitches (without the Starfish) and stabilization with the Octopus

a) Positioning: Compared with baseline data, the changes of AP (from 82±8 to 63±7 mmHg), CO (4.1±0.8 to 3.3±0.5 l/min), and SV (from 53±14 to 40±7 ml) after positioning were significant (*P*<0.05-0.01).

b) Addition of stabilization: Although significant changes of AP, CO, and SV were still detected compared with baseline, no significant further changes were observed after setting of the Octopus stabilizer.

Regional wall motion and segmental shortening

The results of regional wall motion analysis are shown in Table 2.

When stabilization was done following exposure for LAD anastomosis, there were no significant changes of regional wall motion in the LAD and Cx territories. However, when the heart was positioned vertically for Cx anastomosis using the Starfish, SS% decreased in

Table 2. Regional cardiac motion (under volume loading : study 1)

Target vessel	Time of measurements	LAD-SS%	Cx-SS%
LAD ( <i>n</i> =6)	baseline	20.7±7.9	11.8±3.5
	stabilization OP (+)	17.4±7.3	9.9±4.2
Cx ( <i>n</i> =6)	baseline	21.8±7.3	8.5±3.8
	positioning SF (+)	14.4±4.8*	6.6±4.8
	stabilization OP (+)	13.7±4.1*	4.0±2.6
	baseline	19.6±4.3	8.7±2.9
PD ( <i>n</i> =6)	positioning SF (-)	17.6±6.5	8.5±3.9
	stabilization OP (+)	16.6±7.1	4.4±1.9
	baseline	18.0±2.6	7.3±3.2
	positioning SF (+)	15.6±3.3	7.3±2.1
PD ( <i>n</i> =6)	stabilization	13.3±3.3	4.8±1.6
	baseline	20.7±4.7	9.4±2.7
	positioning SF (-)	16.8±6.6	6.7±3.7
	stabilization OP (+)	17.5±7.8	7.8±3.7

\**P*<0.05 vs. baseline

LAD; left anterior descending, Cx; circumflex, PD; posterior descending, OP; Octopus, SF; Starfish, SS; segment shortning

Time of measurements; same as Table 1

Table 3. Analysis of hemodynamic changes (under volume loading with norepinephrine infusion : study 2)

Target vessel	Time of measurements	HR	AP	PAP	CVP	CO	RVEDV	SV	EF	SVO <sub>2</sub>
		(beats/min)	(mmHg)	(mmHg)	(mmHg)	(l/min)	(ml)	(ml)	(%)	(%)
Cx ( <i>n</i> =6)	baseline	101±17	114±10	32±6	7±2	5.9±1.3	194±18	71±15	34±5	88±3
	positioning SF (+)	104±14	103±18	30±5	8±2	5.6±1.5	173±24	70±14	33±5	86±4
	stabilization OP (+)	104±13	101±17	32±7	8±2	5.0±1.4	161±27	63±13	32±5	86±3
	baseline	100±10	104±12	33±7	7±2	5.7±1.4	183±20	66±15	31±6	87±3
	positioning SF (-)	101±11	96±12	31±6	8±2	4.9±1.5	159±36	57±15	32±7	85±4
	stabilization OP (+)	101±11	92±15	31±5	8±2	4.5±1.1	150±20	55±15	32±6	84±5
PD ( <i>n</i> =6)	baseline	101±13	117±17	31±5	7±2	6.3±1.5	200±27	76±20	31±6	88±4
	positioning SF (+)	104±11	100±13	33±8	7±2	5.3±1.2	172±22	62±15	31±5	86±3
	stabilization OP (+)	104±12	97±14	32±6	7±2	5.0±1.0	167±24	61±15	30±5	85±4
	baseline	99±11	102±10	32±7	7±3	5.4±1.1	174±18	66±15	32±6	86±3
	positioning SF (-)	101±11	95±11	33±8	7±2	5.1±1.3	168±27	63±23	31±5	85±3
	stabilization OP (+)	102±9	92±10	30±7	8±2	4.8±1.2	160±34	60±21	31±4	84±4

Cx ; circumflex, PD ; posterior descending, OP ; Octopus, SF ; Starfish

HR ; heart rate, AP ; mean arterial pressure, PAP ; mean pulmonary artery pressure,

CVP ; central venous pressure (mean), CO ; cardiac output, RVEDV ; right ventricular end-diastolic volume,

SV ; stroke volume, EF ; ejection fraction, SVO<sub>2</sub> ; mixed venous oxygen saturation

Time of measurements ; Hemodynamic parameters at LAD anastomosis were first measured before displacement of the heart (baseline), then during stabilization with the Octopus. Measurements for the Cx or PD anastomosis were firstly performed before displacement of the heart (baseline), then during positioning with the Starfish, and finally during stabilization with the Octopus.

the LAD territory ( $P < 0.05$ ). Stabilization caused a further decrease (not significant relative to the data obtained after positioning) and a significant reduction relative to baseline was persistent. However, exposure with Lima sutures did not reduce SS% in the LAD territory after positioning or even after stabilization.

During exposure for PD anastomosis with or without the Starfish, there were no significant changes in SS%, although a decrease was observed ( $p = 0.06$ ) with the Starfish. Addition of stabilization in both settings did not cause additional deterioration of regional wall motion.

*Study 2 (Effect of norepinephrine under volume loading) (N = 6)*

Hemodynamic changes are summarized in Table 3. Comparison of baseline data between Studies 1 and 2 showed that HR, AP, PAP, CO, RVEDV, and SV were significantly higher or larger in Study 2 ( $P < 0.05-0.01$ ).

1) For LAD anastomosis

This setting was not tested because it was the same

as in study 1.

2) For Cx anastomosis

(I) Positioning with the Starfish and stabilization with the Octopus during infusion of norepinephrine

a) Positioning : No significant changes were noted in any of the parameters (HR, AP, PAP, CVP, CO, RVEDV, SV, EF, and SVO<sub>2</sub>).

b) Addition of stabilization : No significant deterioration was observed after stabilization with the Octopus, although RVEDV decreased from  $194 \pm 18$  ml (baseline) to  $161 \pm 27$  ml (stabilization) ( $P = 0.07$ ). Although a fall of RVEDV was seen, the actual value at the stabilization was similar to the baseline data from study 1.

(II) Positioning with deep pericardial stitches (without the Starfish) and stabilization with the Octopus during infusion of norepinephrine

a) Positioning : There were no significant changes of any parameters.

b) Addition of stabilization : No significant deterioration was observed following stabilization with the Octopus.

3) For PD anastomosis

(I) Positioning with the Starfish and stabilization with the Octopus during infusion of norepinephrine

a) Positioning: No significant changes were noted in any of the parameters (HR, AP, PAP, CVP, CO, RVEDV, SV, EF, and SVO<sub>2</sub>).

b) Addition of stabilization: No significant deterioration was observed after stabilization with the Octopus.

(II) Positioning with deep pericardial stitches (without the Starfish) and stabilization with the Octopus during infusion of norepinephrine

a) Positioning: There were no significant changes of any parameters.

b) Addition of stabilization: No significant deterioration was observed following stabilization with the Octopus.

#### Regional wall motion

Data on regional wall motion during the procedures are listed in Table 4.

During exposure and stabilization for any of the vessels (LAD, Cx, or PD anastomosis), there were no significant changes of regional wall motion in the LAD and Cx territories. In study 1, when the heart was positioned vertically for Cx anastomosis, use of the Starfish caused deterioration of SS% in the LAD territory, but this decline of SS% in the LAD territory

was not observed during infusion of norepinephrine.

## DISCUSSION

In this study, we evaluated hemodynamic changes with continuous RVEDV monitoring while using the Octopus stabilizer and also exposing each target vessel with or without the Starfish positioner. We also evaluated regional cardiac wall motion with a digital two-dimensional sonomicrometer. We found that stabilization with the Octopus for LAD anastomosis caused no significant changes of any parameter, including regional wall motion. This supports the satisfactory clinical experience with LAD anastomosis. On the other hand, positioning and stabilization for Cx and PD anastomosis caused significant hemodynamic deterioration. In our experiment, the RVEDV showed a decline in the Cx territory. This was true irrespective of the use of the Starfish. This hemodynamic deterioration seemed to originate from a decrease of RVEDV because of interference with blood inflow into the right ventricle. Therefore, continuous monitoring of RVEDV may be helpful to detect early hemodynamic changes in this situation.

Vertical displacement of the heart by inserting pericardial sutures could possibly cause biventricular heart failure, particularly in the setting of right ventricular dysfunction resulting from mechanical interference with diastolic expansion. Interestingly, the hemodynamic alternations were worse after positioning using Lima sutures and stabilization with Octopus as compared to positioning with Starfish in this study. These changes may be expected with proven superiority of Starfish. Use of the Starfish was very helpful for maintaining hemodynamic stability, since it protects against compression of the vena cava and right ventricle. However, it was found that the Starfish led to unexpected restriction of regional motion. In other words, vertical displacement with the Starfish may restrict ventricular motion to some extent by holding the apex. Thus, it is questionable whether the Starfish should be used in the clinical setting. Since the stable arterial pressure obtained by preventing obstruction of blood inflow with Starfish is more important than minor depression of

Table 4. Regional cardiac motion (under volume loading with norepinephrine infusion: study 2)

Target vessel	Time of measurements	LAD-SS%	Cx-SS%
Cx ( <i>n</i> =6)	baseline	20.0±5.0	7.5±4.0
	positioning SF (+)	15.1±5.4	8.0±4.3
	stabilization OP (+)	15.9±6.5	8.9±4.3
	baseline	21.5±6.8	8.2±3.0
	positioning SF (-)	18.7±7.4	7.9±3.6
	stabilization OP (+)	18.8±7.6	7.0±3.7
PD ( <i>n</i> =6)	baseline	20.7±6.1	8.1±3.2
	positioning SF (+)	20.0±3.3	9.7±4.2
	stabilization OP (+)	20.2±4.6	9.8±2.4
	baseline	20.8±7.4	6.8±3.9
	positioning SF (-)	19.5±7.6	6.5±3.3
	stabilization OP (+)	19.4±7.4	7.7±3.1

LAD; left anterior descending, Cx; circumflex, PD; posterior descending, OP; Octopus, SF; Starfish, SS; segment shortning

Time of measurements; same as Table 3

regional wall motion, we believe that its use is appropriate. The hemodynamic deterioration seen in study 1, including impaired regional wall motion, was improved by concomitant infusion of norepinephrine. The  $\alpha$  adrenergic action of norepinephrine induced constriction of the peripheral arteries resulting in the elevation of systemic and coronary perfusion pressures, while the  $\beta$  adrenergic action improved myocardial contraction. Both of these effects are beneficial. Accordingly, it is suggested that infusion of norepinephrine during OPCAB is effective for the prevention of hemodynamic instability, particularly after appropriate volume loading. Since there is concern about elevation of the double products ( $AP \times HR$ ) after infusion of norepinephrine, however we always need to take into consideration the risk of ischemic deterioration.

There is a report regarding management of OPCAB by the anesthesiologist<sup>16</sup>. The crucial points for a successful outcome are both hemodynamic stability and prevention of ischemia. Hemodynamic stability is usually achieved by volume loading, and mannitol is selected for the treatment of overload. The LV volume change estimated from transesophageal echocardiography is used as the index of volume loading, and norepinephrine is used to treat hemodynamic deterioration despite a sufficient load. His report was based on the phenomenon of RVEDV reduction during exposure of the Cx, which was pointed out by Grüdeman et al.<sup>10</sup> and Mathison et al.<sup>12</sup> However, transesophageal echocardiography might not be informative when the heart is vertical because echo beam cannot reach the surface of heart in this position. In this study, catheter was useful for monitoring of RVEDV and suggested a reduction of RVEDV led to hemodynamic deterioration. Since reduction of RVEDV is not always associated with pressure decrease in the PD territory, however, caution may be necessary with respect to volume loading. We should remember that volume loading is not always beneficial, because excessive loading may cause further deterioration of hemodynamics. In this case, addition of norepinephrine is more important. Since suppression of regional wall motion in the LAD territory was prevented during infusion of norepine-

phrine (in Study 2), norepinephrine is a recommended option for this occasion.

#### *Limitation of this study*

This study was performed on normal hearts and the effect of ischemia was not tested because of the poor tolerance of porcine hearts to ischemia produced by temporary occlusion of major coronary arteries. However, we believe that similar effects might be applicable to the ischemic hearts.

#### CONCLUSION

During OPCAB, various parameters monitored in this study were useful for hemodynamic changes, but RVEDV seems to be an excellent parameter for monitoring of volume loading and for prediction of hemodynamic deterioration. 2) Adequate volume loading in combination with norepinephrine should be considered at appropriate times, particularly when the Cx or PD was exposed as the target vessels. 3) A heart positioner reduced the decrease of AP and was useful for stabilization of hemodynamics. But in combined use of a cardiac stabilizer, it was still unsatisfactory with respect to its influence on regional wall motion.

#### REFERENCES

1. Kirklin JW, Barratt-Boyes BG. Cardiac surgery. 2nd ed. New York: Churchill Livingstone; 1993. p. 83-97, 210-7.
2. Pfister AJ, Zaki MS, Garcia JM, Mispireta LA, Corso PJ, Qazi AG, et al. Coronary artery bypass without cardiopulmonary bypass. *Ann Thorac Surg* 1992; 54: 1085-92.
3. Moshkovitz Y, Lusky A, Mohr R. Coronary artery bypass without cardiopulmonary bypass: analysis of short-term and mid-term outcome in 220 patients. *J Thorac Cardiovasc Surg* 1995; 110: 979-87.
4. Calafiore AM, De Giammarco G, Teodori G, Bosco G, D'Annunzio E, Barsotti A, et al. Left anterior descending coronary artery grafting via left anterior small thoracotomy without cardiopulmonary bypass. *Ann Thorac Surg* 1996; 61: 1658-65.
5. Subramanian VA, McCabe JC, Geller CM. Minimally invasive direct coronary artery bypass grafting: two-year clinical experience. *Ann Thorac Surg* 1997; 64:



- 1648-55.
6. Jansen EWL, Borst C, Lahpor JR, Grüdeman PF, Eefting FD, Nierich A, et al. Coronary artery bypass grafting without cardiopulmonary bypass using the Octopus method: results in the first one hundred patients. *J Thorac Cardiovasc Surg* 1998; 116: 60-7.
  7. Hart JC, Spooner TH, Pym J, Flavin TF, Edgerton JR, Mack MJ, et al. A review of 1,582 consecutive Octopus off-pump coronary bypass patients. *Ann Thorac Surg* 2000; 70: 1017-20.
  8. Niinami H, Koyanagi H, Brady PW, Ross DE. The heart string: A simple, inexpensive exposure of the heart during coronary artery operations. *Ann Thorac Surg* 2000; 69: 1280-1.
  9. Lima RC, Escobar M, Neto JW, Torres LD, Elias DO, Mendonca JT, et al. Revascularizacaodo miocardio semcircula extracorporeal: resultados imediatos. *Rev Bras Cirug Cardiovasc* 1993; 8: 171-4.
  10. Niinami H, Takeuchi Y, Ichikawa S, Ban T, Yigashida R, Suda Y, et al. Multivessel off-pump coronary aortic bypass grafting with an impaired and severely dilated left ventricle using the Starfish heart positioner. *Kyobu Geka* 2002; 55: 773-7.
  11. Kasahara K, Kamata S. Experience of off-pump coronary artery bypass grafting with Starfish heart positioner. *Kyobu Geka* 2002; 56: 385-8.
  12. Grüdeman PF, Borst C, Verlaan CWJ, Meijburg H, Moues CM, Jansen EW. Exposure of circumflex branches in the titled, beating porcine heart: echocardiographic evidence of right ventricular deformation and the effect of right or left heart bypass. *J Thorac Cardiovasc Surg* 1999; 118: 316-23.
  13. Porat E, Sharony R, Ivry S, Ozaki S, Meyns BP, Flameng WJ, et al. Hemodynamic changes and right heart support during vertical displacement of the beating heart. *Ann Thorac Surg* 2000; 69: 1188-91.
  14. Mathison M, Edgerton JR, Horswell JL, Akin J, Mack MJ. Analysis of hemodynamic changes during beating heart surgical procedures. *Ann Thorac Surg* 2000; 70: 1350-4.
  15. Reuse C, Vincent JL, Pinsky MR. Measurements of right ventricular volumes during fluid challenge. *Chest* 1990; 98: 1450-4.
  16. Chassot PG, Linden P, Zaugg M, Mueller XM, Spahn DR. Off-pump coronary artery bypass surgery: physiology and anaesthetic management. *Br J Anaesthes* 2004; 92: 400-13.