

Case Report

## Single Coronary Artery Diagnosed Incidentally on Coronary Angiography in a Child with Kawasaki Disease

Takashi URASHIMA, Ken TAKAGI, Kazuhiro TERANO, Masako FUJIWARA, and Yoshikatsu ETO

*Department of Pediatrics, The Jikei University School of Medicine*

### ABSTRACT

Single coronary artery is a rare anomaly. Most cases are asymptomatic, but sudden death may occur. We report on a patient with single coronary artery and Kawasaki disease. In this patient, expansion of the left coronary artery remained after treatment of Kawasaki disease and was attributed to coronary blood flow being dependent on the left coronary artery. Echocardiography is necessary during the acute phase of Kawasaki disease to evaluate possible coronary lesions and is an opportunity to screen for single coronary artery. If single coronary artery is suspected, coronary angiography should be performed to confirm the diagnosis.

(Jikeikai Med J 2003; 50 : 195-8)

Key words : Kawasaki disease, single coronary artery, angiography, children

### PATIENT REPORT

A 4-year-old boy was referred to our hospital for evaluation of coronary artery disease associated with Kawasaki disease. Kawasaki disease had been diagnosed at the age of 3 years on the basis of strawberry tongue, bilateral cervical lymphadenopathy, bulbar conjunctival hyperemia, labia oris rhagades, erythema and swelling of the hands and feet, and fever of 5 days' duration. The pyrexia and other symptoms improved after 5 days of treatment with high-dose intravenous gammaglobulin (400 mg/kg), but an aneurysm of the left coronary artery remained. Chest X-ray films and electrocardiography showed no other abnormalities, but echocardiography revealed a 5-mm-diameter aneurysm in the main trunk of the left coronary artery but showed no orifice of the right coronary artery. We speculated that the orifice could not be visualized because of technical limita-

tions. After discharge the patient was treated with oral aspirin and ticlopidine hydrochloride. Coronary

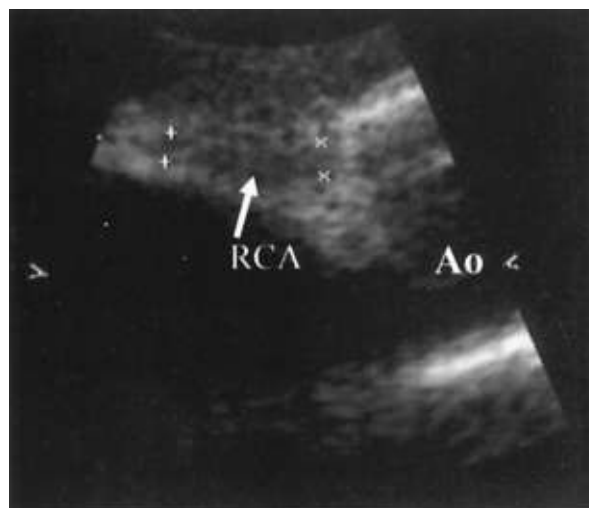


Fig. 1. Right coronary artery on echocardiography. The orifice of the right coronary artery could not be identified.

Received for publication, August 28, 2003

浦島 崇, 高木 健, 寺野 和宏, 藤原 優子, 衛藤 義勝

Mailing address : Takashi URASHIMA, Department of Pediatrics, The Jikei University School of Medicine, 3-25-8, Nishi-Shimbashi, Minato-ku, Tokyo 105-8461, Japan.

E-mail : urashima-t@jikei.ac.jp

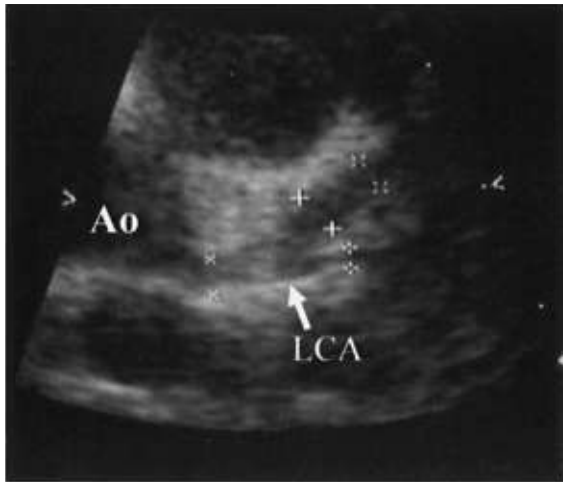

Fig. 2. Left coronary artery on echocardiography. The left coronary artery had expanded to a diameter of 3.5 mm.

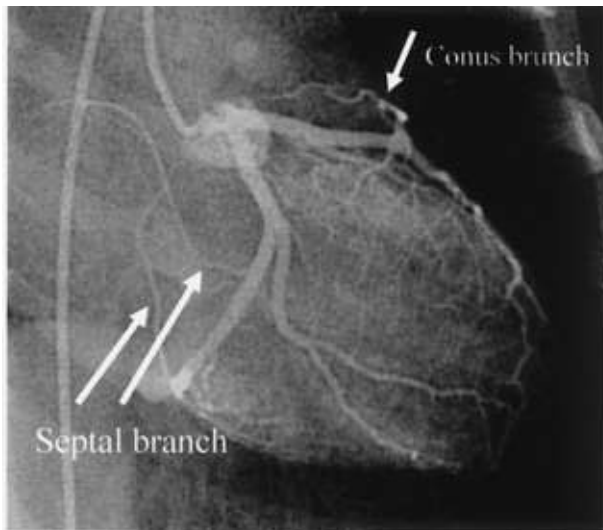


Fig. 3. Left coronary angiography. A conus rami branch arose from the left anterior descending artery, and a septum rami branch arose from the circumflex artery.

artery expansion after Kawasaki disease disappears in most patients within several months. In this patient, cardiac catheterization was necessary because the left coronary artery had expanded to a diameter of 3.5 mm and the orifice of the right coronary artery could not be identified on echocardiography (Fig. 1, 2). Angiography showed a single coronary artery. A conus rami branch arose from the left anterior descending artery and a septum rami branch arose from the circumflex artery (Fig. 3). The vessel that had appeared on echocardiography to be the

right coronary artery was the conus rami branch. These findings indicated a Shirani classification of type 1 B (Fig. 4). Neither stenosis nor expansion of the coronary artery was recognized. Myocardial scintigraphy revealed no ischemic changes.

## DISCUSSION

The reported prevalence of single coronary artery ranges from 0.04% to 0.2%. Most single coronary arteries are found incidentally at coronary angiography. In addition, 40% of patients with a single coronary artery also have transposition of the great vessels or tetralogy of Fallot<sup>1</sup>; in contrast, single coronary artery is rarely found in children without other congenital cardiac defects<sup>2</sup>. Early diagnosis is important, because sudden death occurs in 9% of patients with a single left coronary artery and in 18% of patients with a single right coronary artery<sup>3</sup>. Of particular concern is a single coronary artery that lies between the aorta and the pulmonary artery. Pressure is placed upon the coronary artery, and coronary blood flow may be inhibited by great vessels whose elasticity has been decreased by arterial sclerosis.

Other than cases discovered at autopsy, single coronary artery is usually diagnosed with coronary angiography. Recently, diagnosis with magnetic resonance has also become possible<sup>4</sup> but is complicated in infants by incomplete heart rate synchronization. The heart rate of more than 100 beats per minute in most normal infants inhibits heart rate synchronization. Echocardiography, an easily performed, noninvasive examination, is also useful for diagnosis, but in our patient the origin of the right coronary artery from the left coronary artery could not be visualized with echocardiography.

The expansion of the left coronary artery seen with echocardiography in our patient was not a late effect of Kawasaki disease because coronary angiography did not show local expansion and the vascular wall was smooth. Instead, the expansion was a result of the dependence of coronary blood flow on the left coronary artery. Such hemodynamic changes may cause giant aneurysms in patients with Kawasaki disease. To our knowledge, only one case of single

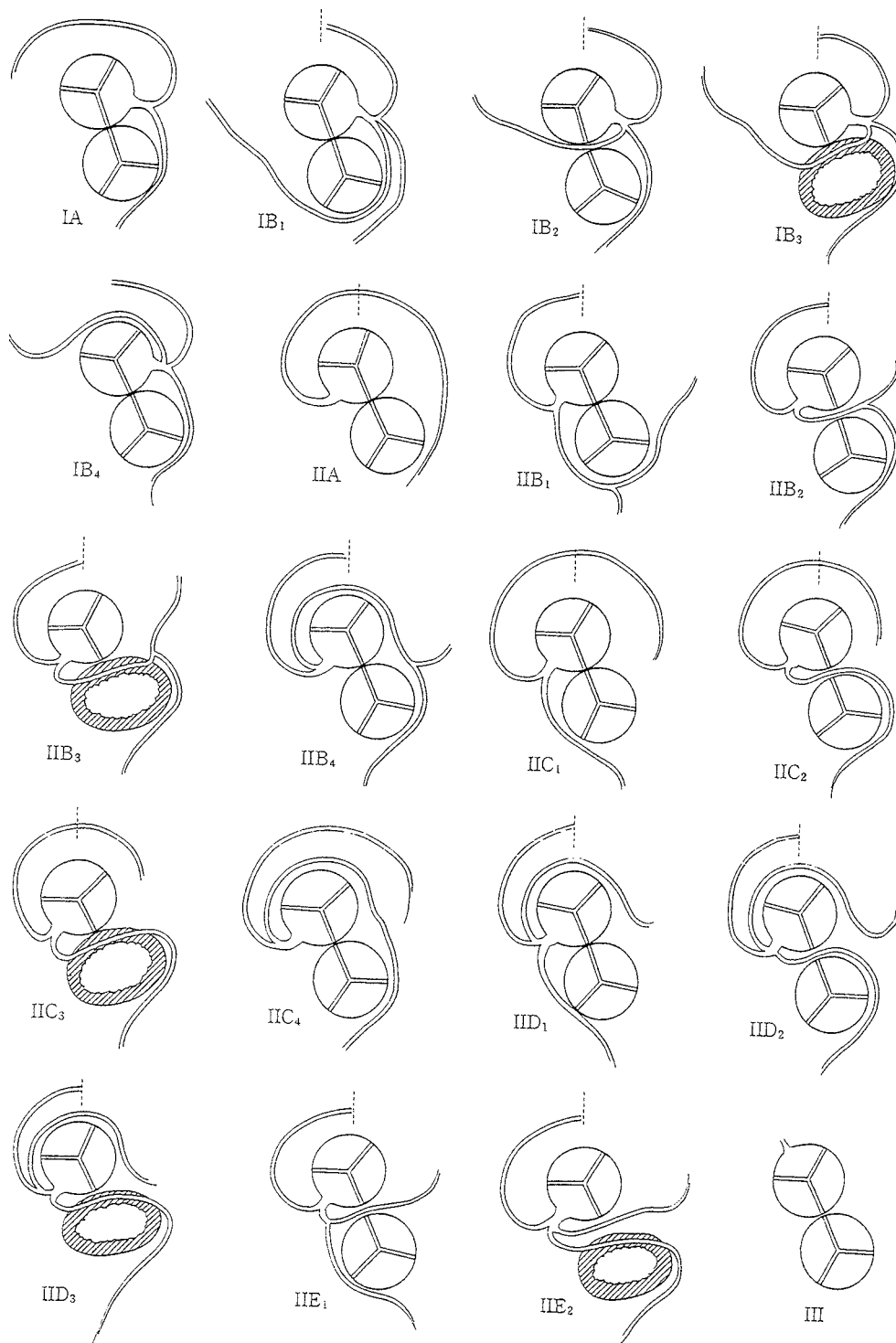


Fig. 4. Shirani classification for single coronary artery.

coronary artery in Kawasaki disease has previously been reported. In Japan, Kawasaki disease develops in 7,000 patients per year. However, if the prevalence of single coronary artery is 0.04% to 0.2%, the condi-

tions may be diagnosed together in as many as 14 patients each year.

Some studies have shown that early arterial sclerosis develops in patients with Kawasaki disease

because of vascular endothelium dysfunction due to arteritis<sup>5</sup>. If a stenotic lesion appears in the left main trunk of such a patient, ischemia may be extensive. Early diagnosis of single coronary artery is important, because the patient's physical activity should be limited to decrease the risk of sudden death, and diet therapy and treatment with oral administration may be needed to prevent arteriosclerosis. Echocardiography in children with Kawasaki disease is an opportunity to screen for single coronary artery. If echocardiography suggests a single coronary artery, coronary angiography should be performed to confirm the diagnosis.

## REFERENCES

1. Pasquali SK, Hasselblad V, Li JS. Coronary artery pattern and outcome of arterial switch operation for transposition of the great arteries: a meta-analysis. *Circulation* 2002; 106: 2575-80.
2. Muta H, Ishii M, Matsuishi T. Coronary artery aneurysms after Kawasaki disease in a patient with a single coronary artery. *Pediatr Cardiol* 2002; 23: 568-9.
3. Taylor AJ. Sudden cardiac death associated with isolated congenital coronary artery anomalies. *J Am Coll Cardiol* 1992; 20: 640.
4. Wicky S, Lyon X, Kappenberger L. Silent single coronary artery anomaly depicted by magnetic resonance angiography. *J Invasive Cardiol* 2002; 14: 328-30.
5. Noto N, Okada T, Yamasuge M. Noninvasive assessment of the early progression of atherosclerosis in adolescents with Kawasaki disease. *Pediatrics* 2001; 107: 1095-9.