

Case Report

Successful Laparoscopic Repair in a Young Adult Who had Undergone Open Surgery for Esophageal Hiatal Hernia during Early Childhood : A Case Report

Kazuto Tsuboi, Nobuo Omura, Hideyuki Kashiwagi, and Katsuhiko Yanaga

Department of Surgery, The Jikei University School of Medicine

ABSTRACT

The patient was a 22-year-old man who had undergone open fundoplication for esophageal hiatal hernia when aged 1 year 5 months. Twenty years later, the patient complained of regurgitation. Thorough investigations revealed displacement of the upper stomach and the wrap into the mediastinum. For reflux esophagitis due to recurrent esophageal hiatal hernia and wrap dislocation, laparoscopic Toupet fundoplication was successfully performed. The postoperative course was uneventful, and the patient remains free of symptoms. Laparoscopic repair is possible for recurrent esophageal hiatal hernia in patients who have undergone fundoplication in early childhood. (Jikeikai Med J 2007 ; 54 : 153-7)

Key words : gastroesophageal reflux disease, fundoplication, laparoscopic surgery, redo, Japanese

INTRODUCTION

Fundoplication is widely performed to treat gastroesophageal reflux disease (GERD). The long-term efficacy of fundoplication for GERD is approximately 90%, and favorable results have been obtained¹. However, studies that have followed up patients for 10 years after surgery have shown that approximately 10% had complications and 4% to 9% underwent reoperation²⁻⁸. Reoperation can be performed by means of laparotomy or laparoscopy. However, for technical reasons, there have been few reports of laparoscopic reoperations in patients who had initially undergone laparotomy.

The present patient had undergone open fundoplication during early childhood and underwent laparoscopic fundoplication 21 years later. To our knowl-

edge, laparoscopic reoperation long after fundoplication has not previously been reported.

CASE REPORT

The patient was a 22-year-old man with a 2-year history of heartburn and regurgitation. At the age of 1 year 5 months he had undergone open fundoplication for esophageal hiatal hernia. Because endoscopy confirmed reflux esophagitis, a proton pump inhibitor was prescribed. However, because the patient did not desire long-term treatment with medication, he was referred to our department for surgery in July 2005. Upper gastrointestinal endoscopy confirmed Los Angeles Grade B reflux esophagitis (Fig. 1), and an upper gastrointestinal barium study revealed wrap displacement of the stomach into the mediastinum and

Received for publication, February 14, 2007

坪井 一人, 小村 伸朗, 柏木 秀幸, 矢永 勝彦

Mailing address : Kazuto Tsuboi, Department of Surgery, The Jikei University School of Medicine, 3-25-8, Nishi-Shimbashi, Minato-ku, Tokyo 105-8461, Japan.

E-mail : kazuto@jikei.ac.jp

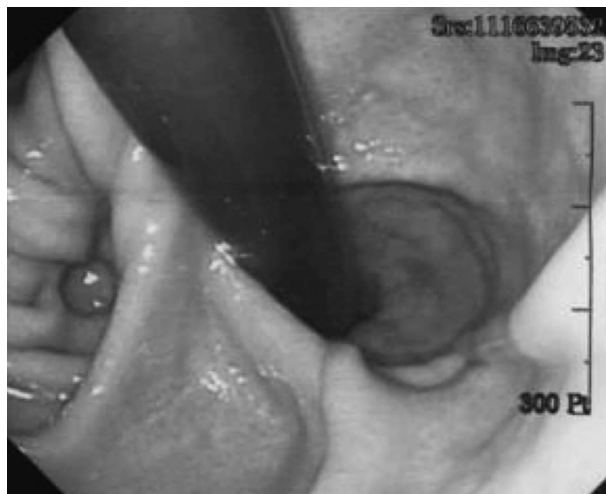

Fig. 1. Upper gastrointestinal endoscopy confirmed esophageal hiatal hernia.

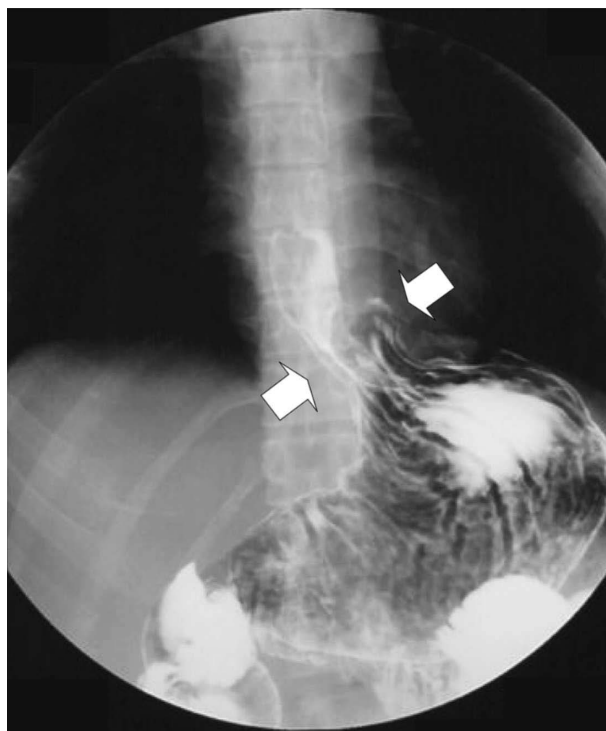


Fig. 2. Upper gastrointestinal series confirmed transdiaphragmatic herniation of the wrap and esophageal hiatal hernia.

esophageal hiatal hernia (Fig. 2). Results of 24-hour pH monitoring were as follows: pH < 4 holding time, 22.8%; number of reflux episodes, 361 per day; number of reflux episodes lasting ≥ 5 minutes, 16 per day; longest reflux time, 14 minutes; and DeMeester

score, 78.2. Hence, the patient was judged to have severe acid reflux.

On the basis of these findings, the patient underwent reoperation in July 2005. Under general anesthesia, a 12-mm trocar was inserted above the navel with the open method. Pneumoperitoneum was established at 12 mm H₂O using CO₂ gas. A laparoscope was then inserted, and under laparoscopic guidance a 5-mm trocar was inserted under the costal arch in the right midclavicular line and under the xiphoid process, a 12-mm trocar was inserted under the costal arch in the left midclavicular line, and a 5-mm trocar was inserted at the lateral region in the left anterior axillary line.

Examination of the abdominal cavity showed that adhesion of the surgical wound was mild and could be controlled by sharp dissection. Next, adhesion between the left hepatic lobe and the stomach was dissected sharply. Then, the left hepatic lobe was raised with a flexible retractor (Endoflex, Surgical Innovations, Leeds, UK) to expose the esophageal hiatus, which was widely patent, and the entire wrap and the upper stomach were displaced through the hiatus.

By dividing the branches of the short gastric artery and vein, the esophagus was approached from the greater curvature side of the upper stomach. After the wrap was reduced and the underlying esophagus was returned to the abdominal cavity, the widened hiatus was closed by placing 6 sutures behind the esophagus (crural repair). Toupet fundoplication was then performed (Fig. 3). At this stage, to prevent wrap displacement into the thoracic cavity, the wrap was fixed to the crus of the diaphragm on the right and left sides. Finally, from the anterior surface of the esophagus, 2 sutures were placed for crural repair. The operation took 145 minutes to complete, and intraoperative bleeding was minimal.

Postoperative course

Intraoperative damage to the left parietal pleura caused pneumothorax, for which a drainage tube was inserted postoperatively. The patient began drinking water 1 day after surgery and resumed eating the next day. The drainage tube was removed on the same

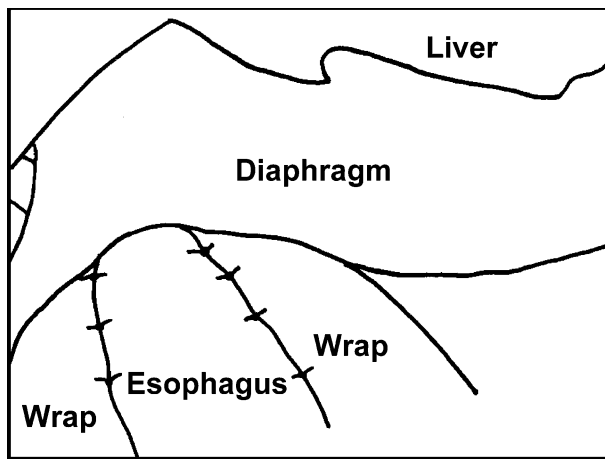
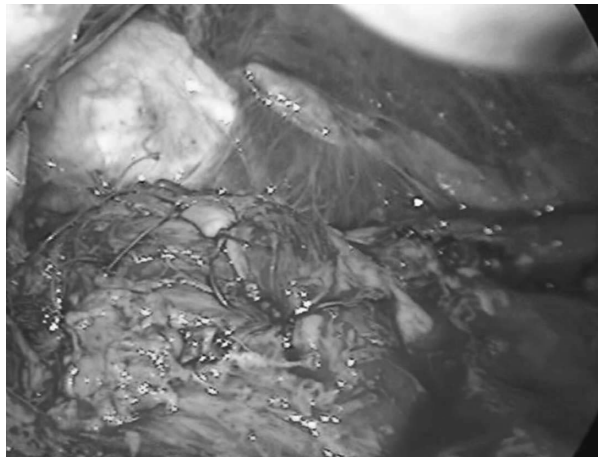
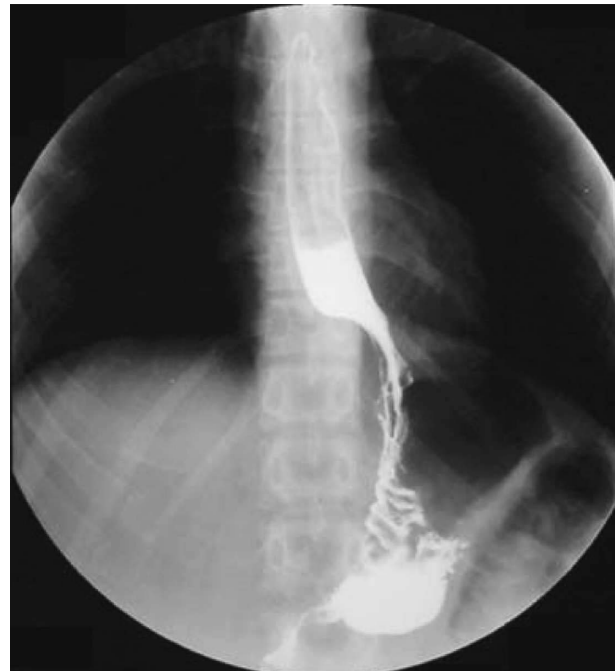

Fig. 3. Toupet fundoplication was performed.

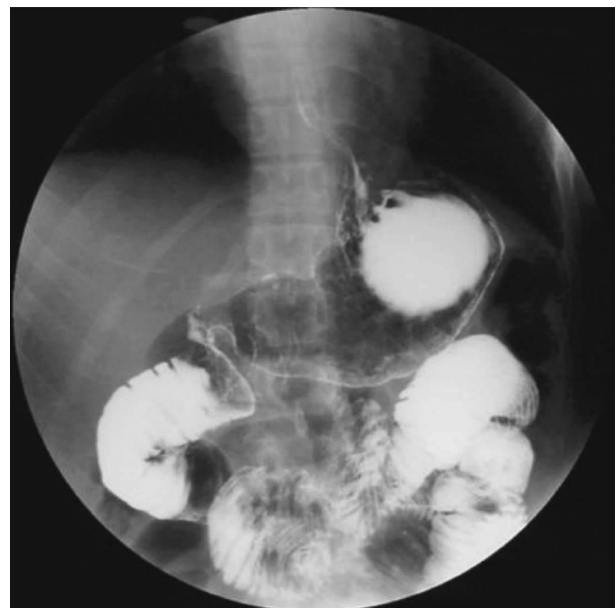day. The patient was discharged 9 days after surgery and remains well and without symptoms. An upper gastrointestinal series obtained 6 months after surgery demonstrated the orthotopic position of the wrap and no evidence of esophageal regurgitation (Fig. 4a, b).

DISCUSSION

After fundoplication for reflux esophagitis, approximately 10% of patients have complications, and 4% to 9% undergo laparoscopic reoperation²⁻⁹. In many cases, reoperation is performed for transdiaphragmatic wrap herniation within 2 years after the initial surgery¹⁶. The clinical course in our patient was good, but the simultaneous appearance of symptoms and the patient's finding of employment suggests



a



b

Fig. 4. An upper gastrointestinal series obtained 6 months after surgery demonstrated no wrap dislocation (a) or esophageal regurgitation (b).

physical and mental stresses as possible reasons for the sudden worsening of the patient's condition.

Studies examining recurrent reflux esophagitis following fundoplication for GERD suggest that anatomical factors in the cardiac region are responsible

in 69% to 87% of cases¹⁰⁻¹². Such anatomical factors included transdiaphragmatic migration, slipped/misplaced fundoplication, and twisted fundoplication³. The results of reoperation are generally good, and symptoms, such as heartburn, regurgitation, and dysphagia, improve in more than 90% of cases. In many cases, the use of acid reducers, such as proton pump inhibitors, can be reduced or terminated¹⁰⁻¹⁶.

In the present patient, the upper stomach was displaced into the thoracic cavity with the wrap, and this transdiaphragmatic herniation was believed to be the main factor in the onset of reflux esophagitis. Factors promoting reflux esophagitis due to transdiaphragmatic herniation are that the intrapleural pressure is lower than the intraabdominal pressure and that wrap dysfunction disrupts reflux prevention. The rate of reoperation due to transdiaphragmatic herniation has been reported to be 13%¹⁰.

Reoperation can be performed with an open method or with laparoscopy. In the past, open surgery was most often performed because of technical issues: the incidence of complications following laparoscopic reoperation was high (30% to 45%)¹⁷, and 20% of patients required conversion to open surgery¹⁴. The literature, therefore, contains few reports of laparoscopic reoperation in patients who had initially undergone open surgery¹³. Moreover, the number of patients undergoing fundoplication for GERD in Japan is much lower than in Western countries, and there have been few reports of laparoscopic reoperation in Japan¹⁸. Therefore, the present case is extremely unusual because open fundoplication was performed during early childhood, and reoperation was performed laparoscopically 21 years later.

Because open fundoplication was performed in early childhood, the wrap was tightly adherent to the parietal pleura, and left pneumothorax developed during surgery. However, by lowering the intra-abdominal pressure, reoperation was completed laparoscopically without requiring open surgery. If open surgery is performed first, laparoscopic reoperation following open surgery is not necessarily easy because of adhesion, but it is possible with careful procedures.

Herein, we have reported on a patient in whom recurrent reflux esophagitis after open fundoplication

in early childhood was successfully treated with laparoscopic reoperation 21 years later.

REFERENCES

1. DeMeester TR, Bonavina L, Albertucci M. Nissen fundoplication for gastroesophageal reflux disease: evaluation of primary repair in 100 consecutive patients. *Ann Surg* 1986; 204: 9-20.
2. Lafullarde T, Watson DI, Jamieson GG, Myers JC, Game PA, Devitt PG. Laparoscopic Nissen fundoplication: five-year results and beyond. *Arch Surg* 2001; 136: 180-4.
3. Hunter JG, Smith CD, Branum GD, Waring JP, Trus TL, Cornwell M, et al. Laparoscopic fundoplication failures: patterns of failure and response to fundoplication revision. *Ann Surg* 1999; 230: 595-606.
4. Anvari M, Allen C. Five-year comprehensive outcomes evaluation in 181 patients after laparoscopic Nissen fundoplication. *J Am Coll Surg* 2003; 196: 51-9.
5. Hinder RA, Filipi CJ, Wetscher G, Neary P, DeMeester TR, Perdakis G, et al. Laparoscopic Nissen fundoplication is an effective treatment for gastroesophageal reflux disease. *Ann Surg* 1994; 220: 472-83.
6. Hunter JG, Trus TL, Branum GD, Waring JP, Wood WC. A physiologic approach to laparoscopic fundoplication for gastroesophageal reflux disease. *Ann Surg* 1996; 223: 673-87.
7. Soper NJ, Dunnegan D. Anatomic fundoplication failure after laparoscopic antireflux surgery. *Ann Surg* 1999; 229: 669-77.
8. DePaula AL, Hashiba K, Bafutto M, Machado CA. Laparoscopic reoperations after failed and complicated antireflux operations. *Surg Endosc* 1995; 9: 681-6.
9. Graziano K, Teitelbaum DH, McLean K, Hirschl RB, Coran AG, Geiger JD. Recurrence after laparoscopic and open Nissen fundoplication: a comparison of the mechanisms of failure. *Surg Endosc* 2003; 17: 704-7.
10. Papasavas PK, Yeane WW, Landreneau RJ, Hayetian FD, Gagne DJ, Caushaj PF, et al. Reoperative laparoscopic fundoplication for the treatment of failed fundoplication. *J Thorac Cardiovasc Surg* 2004; 128: 509-16.
11. Rosemurgy AS, Arnaoutakis DJ, Thometz DP, Binitie O, Giarelli NB, Bloomston M, et al. Reoperative fundoplications are effective treatment for dysphagia and recurrent gastroesophageal reflux. *Am Surg* 2004; 70: 1061-7.
12. Byrne JP, Smithers BM, Nathanson LK, Martin I, Ong HS, Gotley DC. Symptomatic and functional outcome after laparoscopic reoperation for failed antireflux surgery. *Br J Surg* 2005; 92: 996-1001.
13. Granderath FA, Kamolz T, Schweiger UM, Pasiut M, Haas CF, Wykypiel H, et al. Is laparoscopic refundoplication feasible in patients with failed primary open

- antireflux surgery? *Surg Endosc* 2002 ; 16 : 381-5.
14. Coelho JCU, Goncalves CG, Claus CMP, Andrigueto PC, Ribeiro MN. Late laparoscopic reoperation of failed antireflux procedures. *Surg Laparosc Endosc Percutan Tech* 2004 ; 14 : 113-7.
 15. Pointner R, Bammer T, Then P, Kamolz T. Laparoscopic refunduplications after failed antireflux surgery. *Am J Surg* 1999 ; 178 : 541-4.
 16. Smith CD, McClusky DA, Rajad MA, Lederma AB, Hunter JG. When fundoplication failes redo? *Ann Surg* 2005 ; 241 : 861-71.
 17. Awad ZT, Anderson PI, Sato K, Roth TA, Gerhardt J, Filipi CJ. Laparoscopic reoperative antireflux surgery. *Surg Endosc* 2001 ; 15 : 1401-7.
 18. Takeyama S, Numata A, Nenohi M, Shibata Y, Okushiba S, Katoh H. Laparoscopic Nissen fundoplication for gastroesophageal reflux disease in Japan. *Surg Today* 2004 ; 34 : 506-9.