

## Repetitive Low-Frequency Transcranial Magnetic Stimulation Plus Speech Therapy over a Six-Month Period Improved Naming and Writing

Wataru KAKUDA<sup>1</sup>, Masahiro ABO<sup>1</sup>, Nobuyoshi KAITO<sup>2</sup>, Atsushi SENOO<sup>3</sup>,  
and Motoi WATANABE<sup>1</sup>

<sup>1</sup>*Department of Rehabilitation Medicine, The Jikei University School of Medicine*

<sup>2</sup>*Department of Neurosurgery, The Jikei University School of Medicine*

<sup>3</sup>*Division of Radiological Sciences, Faculty of Health Sciences, Tokyo Metropolitan University*

### ABSTRACT

*Objective* : To examine the safety and efficacy of long-term application of repetitive low-frequency transcranial magnetic stimulation (rTMS) and speech therapy for post-stroke aphasic patients. *Subjects and Methods* : Two post-stroke patients with motor-dominant aphasia were studied. Prior to the rTMS treatment, functional MRI (fMRI) was performed with a word repetition task. The selected site for rTMS application was the area homologous to the most activated area on fMRI. Twenty-minute low-frequency rTMS of 1 Hz was applied once per week in the outpatient clinic for 6 months after a 6-day in-hospital application, combined with speech therapy. Language function was evaluated at the beginning and ends of in-patient and outpatient treatment courses. *Results* : The rTMS was applied to the right inferior frontal gyrus, since the left inferior frontal gyrus was most activated area in both patients. Both patients successfully completed the therapeutic rTMS protocol without any adverse effects. In-patient and outpatient treatments improved language function such as naming and writing in both patients. *Conclusion* : Our protocol of weekly long-term rTMS treatment is a feasible therapeutic approach for aphasic patients.

(Jikeikai Med J 2009 ; 56 : 31-6)

Key words : repetitive transcranial magnetic stimulation, speech therapy, rehabilitation, stroke, aphasia

### INTRODUCTION

Naeser et al. have shown that repetitive low-frequency transcranial magnetic stimulation (rTMS) as treatment for post-stroke patients with aphasia improves language functional recovery especially when it is applied consecutively over a 2-week period<sup>1,2</sup>. However, to our knowledge, there are no reports that document the long-term use of rTMS (i.e., over several months) in aphasic patients and its clinical efficacy. We report two post-stroke patients

with aphasia who were treated with low-frequency rTMS once per week at the outpatient clinic over a period of 6 months after an initial consecutive 6-day in-patient rTMS treatment.

### SUBJECTS AND METHODS

Two patients with the history of stroke and motor-dominant aphasia were studied. The clinical characteristics of the patients are summarized in Table 1. At the time of study entry, both patients

---

Received for publication, May 12, 2009

角田 亘, 安保 雅博, 海渡 信義, 妹尾 淳史, 渡辺 基

Mailing address : Masahiro ABO, Department of Rehabilitation Medicine, The Jikei University School of Medicine, 3-25-8, Nishi-Shimbashi, Minato-Ku, Tokyo 105-8461, Japan.

E-mail : abo@jikei.ac.jp

Table 1. Clinical features of the two patients

	Patient 1	Patient 2
Age at beginning of treatment (years)	66	57
Gender	Male	Male
Time between onset of stroke and beginning of treatment	6 months	16 months
Type of stroke	Cerebral infarction (cardiogenic embolism)	Cerebral infarction (cardiogenic embolism)
Location of lesion on T1-weighted images	Left MCA territory	Left MCA territory
Type and severity of aphasia	Moderate motor-dominant aphasia	Moderate motor-dominant aphasia

# MCA : middle cerebral artery

were able to walk unaided and considered capable of visiting the outpatient clinic without marked efforts. They were assessed as to have reached a plateau state in the process of recovery from aphasia with conventional speech therapy, which commenced soon after the onset of stroke. The conclusion was based on the finding of no changes in tests of language evaluation during the latest three months prior to the study entry. Both patients were free of pathological conditions that were considered contraindications for repetitive rTMS according to the guidelines suggested by Wasserman<sup>3</sup>, and both had no epileptic discharges on pretreatment electroencephalography. Prior to the rTMS treatment, functional MRI (fMRI) with a word repetition task was performed on both patients. We applied low-frequency rTMS of 1 Hz to the homologous areas of the most activated areas on pretreatment fMRI as both 6-day daily sessions during hospitalization and weekly sessions in the outpatient clinic for 6 months. Speech therapy was also provided throughout the period of rTMS therapy. The therapeutic low-frequency rTMS protocol was approved by the local ethics review committee and informed consent was obtained from both patients before study entry. Using established tests, language function was evaluated at the beginning and end of the in-patient rTMS course, and also at the end of the 6-month weekly sessions of rTMS treatment. In addition, informal interviews about the changes in language function and the patient impression on the treatment were also conducted at the end of the 6-month weekly treatment.

*Determination of site of rTMS application:* Prior to

the rTMS application, fMRI with a word repetition task was performed using an echo planar imaging gradient echo sequence for both patients. A single session of fMRI consisted of two different conditions; repetition and rest. In the repetition task, patients were asked to repeat aloud a series of single words that were delivered every 3 seconds through earphones. An image analysis was performed using Statistical Parametric Mapping (SPM) 2 implemented in MATLAB. The activated areas were noted on the axial images of fMRI and labeled in the Talairach coordinate space. In addition, lateral reconstructed 3D images were created. Based on our therapeutic concept, first, we identified the areas homologous to the most activated sites (sites with the highest T value) on the axial images of fMRI, based on the labeled location in the Talairach coordinate space. Next, T1-weighted images were obtained after marking the tentative stimulation site on the skull with a small liquid-filled capsule, based on the fMRI findings. Finally, we determined the site of rTMS application on the skull taking into consideration of the discrepancy between the tentative stimulation site shown on T1-weighted images and the homologous areas of the most activated areas on the axial images of fMRI.

*Six-day in-patient treatment with low-frequency rTMS:* Over 6 consecutive days of hospitalization, each patient underwent 10 sessions of low-frequency rTMS. rTMS was performed with a 70-mm figure-8 coil and a Magstim Rapid stimulator (Dyfed, UK). The intensity of rTMS was set at 90% of the motor threshold (the lowest intensity that elicited a visible

twitch in the ipsilesional thenar muscles) for the right hemisphere. Each rTMS session consisted of 1,200 pulses of 1 Hz, lasting 20 minutes. Each patient received two sessions of rTMS with in-between rest period of 7 hours, on admission days 2, 3, 4 and 5 (usually at 9 am and at 4 pm), and a single session at 4 pm on the day of admission and at 9 am on the day of discharge. During the period of hospitalization, 60-minute one-on-one speech therapy was provided daily (usually at 1 pm). The speech therapy consisted of stimulation techniques to improve spoken and written language, and symptom-specific techniques such as self-cueing using linguistic cues.

*Weekly outpatient treatment with low-frequency rTMS:* After the completion of 6-day rTMS treatment in the hospital, the patients were subsequently scheduled to visit the outpatient clinic once per week for rTMS and speech therapies, over a period of 6 months. On each visit, the patient received 20-minute low-frequency 1 Hz rTMS prior to speech therapy. The application site and intensity of low-frequency rTMS were similar to those used the in-patient rTMS sessions. Immediately after rTMS application, 60-minute speech therapy of the same content as in-patient treatment was provided. The patients were monitored carefully from the beginning of rTMS application until the end of the following speech therapy. When the patient could not visit the clinic as scheduled, the treatment schedule was promptly rearranged so that the interval between two rTMS sessions did not exceed more than 2 weeks.

*Evaluation of language function:* Language function was evaluated using the Japanese version of Western Aphasia Battery (WAB), the Standard Language Test of Aphasia (SLTA) and the supplementary test of SLTA (SLTA-ST). In the Japanese version of WAB, spontaneous speech category, naming category of 60 objects and repetition category for 100 words were used in the evaluation. The SLTA is the standard language test for individuals who speak Japanese and originally provided in Japanese. Naming category of 20 words, repetition category of 10 words and 5 sentences, writing category were evaluated in SLTA.

SLTA-ST was also used to evaluate naming ability for Japanese words. In all three tests, the correct answer rates for each category were calculated.

## RESULTS

As shown in Fig. 1, on pretreatment fMRI of both patients, the activated areas were spread more widely in the left hemisphere than in the right hemisphere. In both patients, the most activated area was in the left inferior frontal gyrus (Patient 1: Brodmann area 47 labeled as  $x: -48, y: 21, z: -12$  in the Talairach coordinate space; Patient 2: Brodmann area 9 labeled as  $x: -60, y: 9, z: 27$  in the Talairach coordinate space). Accordingly, rTMS was applied to the right inferior frontal gyrus (areas homologous to the most activated areas) in both patients (Patient 1:  $x: 48, y: 21, z: -12$  in the Talairach coordinate space; Patient 2:  $x: 60, y: 9, z: 27$  in the Talairach coordinate space). Following the 6-day in-patient rTMS treatment, both patients successfully completed the 6-month outpatient rTMS treatment, which included 26 rTMS sessions in total. Although the schedule for outpatient rTMS treatment was modified several times (3 times in Patient 1, 6 times in Patient 2), the interval between two outpatient rTMS sessions was consistently less than 2 weeks. Both patients showed significant recovery of language function during in-patient rTMS treatment, and even further improvement was noted at the end of the outpatient treatment (Table 2). With regard to the ability of naming, improvement was found in 3 naming categories in both patients. In Patient 2, the score almost doubled at the end of the outpatient treatment especially the score in the category of naming in WAB and SLTA-ST. For both patients, the score of writing category of SLTA increased more significantly during the outpatient treatment than during in-patient treatment. No adverse effects were seen throughout the in-patient and outpatient rTMS treatment courses. In the informal interview conducted at the end of the outpatient rTMS treatment, both patients commented that it was not problematic to visit the clinic to receive the outpatient rTMS treatment at a frequency of once per week for 6 months and that they perceived

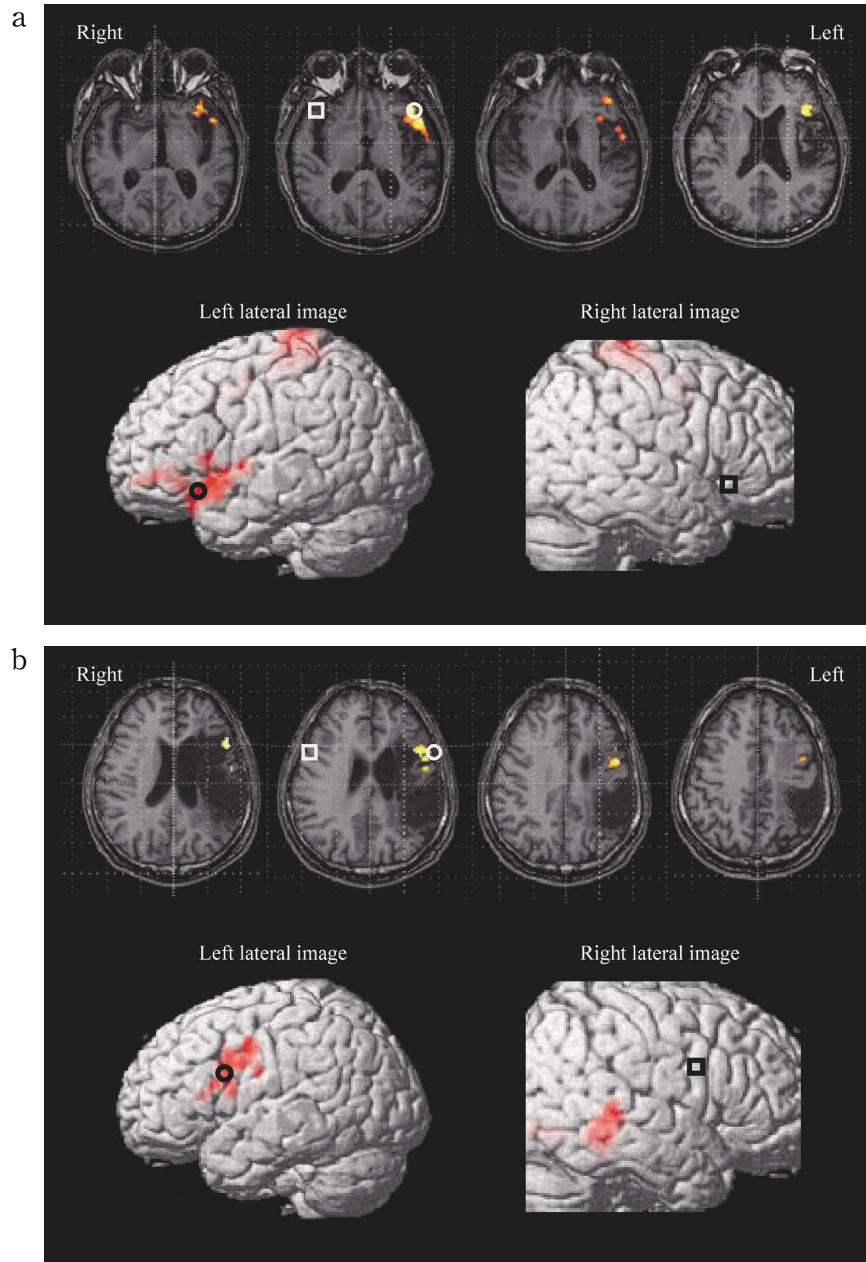


Fig. 1a and 1b. Axial image (overlaid on the anatomical T1-weighted image showing the infarct lesion) and lateral reconstructed 3D image of fMRI with a language task for each patient (a: Patient 1, b: Patient 2). Both patients had cortical ischemic lesion in the territory of the left middle cerebral artery that extended into Broca's area and was compatible with the type and severity of aphasia in each individual patient. In both patients, the most activated area (the area with the highest T-value, white circle on the axial image and black circle on the left lateral image) on fMRI was located in the inferior frontal gyrus of the left hemisphere (Patient 1: Brodmann area 47,  $x: -48$ ,  $y: 21$ ,  $z: -12$  in the Talairach coordinate space, Patient 2: Brodmann area 9,  $x: -60$ ,  $y: 9$ ,  $z: 27$  in the Talairach coordinate space). Based on the fMRI findings, we applied 1 Hz rTMS to the areas homologous to the activated areas in the right inferior frontal gyrus (white square on the axial image and black square on the right lateral image).

Table 2. Changes in language function after in-patient and outpatient rTMS treatments

		Patient 1			Patient 2		
		At beginning of in-patient treatment	At end of in-patient treatment	At end of 6-month outpatient treatment	At beginning of in-patient treatment	At end of in-patient treatment	At end of 6-month outpatient treatment
WAB	Spontaneous speech (maximum score: 20)	16 ( 80)	18 ( 90)	18 ( 90)	13 (65)	14 (70)	14 ( 70)
	Naming (maximum score: 60)	52 ( 87)	54 ( 90)	57 ( 95)	18 (30)	24 (40)	39 ( 65)
	Repetition (maximum score: 100)	92 ( 92)	98 ( 98)	98 ( 98)	27 (27)	44 (44)	44 ( 44)
SLTA	Naming (maximum score: 20)	14 ( 70)	14 ( 70)	16 ( 80)	11 (55)	11 (55)	13 ( 65)
	Repetition of words (maximum score: 10)	10 (100)	10 (100)	10 (100)	7 (70)	8 (80)	10 (100)
	Repetition of sentences (maximum score: 5)	3 ( 60)	3 ( 60)	4 ( 80)	2 (40)	2 (40)	2 ( 40)
	Writing (maximum point: 40)	26 ( 65)	28 ( 70)	34 ( 85)	10 (25)	12 (30)	23 ( 58)
SLTA-ST	Naming (maximum point: 80)	63 ( 79)	67 ( 84)	74 ( 93)	33 (41)	38 (48)	59 ( 74)

The Japanese version of WAB was used in both patients. The SLTA and SLTA-ST were conducted in Japanese.

WAB: Western Aphasia Battery, SLTA: Standard Language Test of Aphasia, SLTA-ST: Supplementary Test of SLTA

Numbers in parentheses represent the rate of correct answers.

a gradual improvement in language function during the 6-month outpatient rTMS treatment.

## DISCUSSION

Naeser et al. reported that consecutive application of low-frequency rTMS to the right pars triangularis for 2 weeks improved language function, especially picture naming, and the beneficial effects persisted for at least 2 months after cessation of the rTMS treatment in four nonfluent aphasia patients, and 8 months post-rTMS, in three of the four patients<sup>1,2</sup>. However, they did not apply rTMS after the 2-week treatment. The aim of this study was to determine the safety and clinical efficacy of rTMS treatment applied over 6 months in post-stroke aphasic patients. We speculated that the most activated areas on fMRI are more significant than Broca's area in the left hemisphere in the process of language function recovery. Our therapeutic strategy was to apply low-frequency rTMS to the homologous areas of the most activated areas, based on the hypothesis that interhemispheric inhibitory projections towards the most activated areas originate mainly from the homologous areas of the opposite hemisphere. Our proposed protocol of outpatient rTMS treatment after in-patient rTMS treatment

proved feasible and was completed without any adverse effects or complaints by the patients. To note, further improvement of language function was achieved during the 6-month outpatient rTMS treatment after a similar improvement following the in-patient rTMS treatment. The correct answer rates in some categories of language evaluation tests were higher at the end of the outpatient rTMS treatment than at the end of the in-patient rTMS treatment.

With regard to the underlying mechanism of the recovery of language function in these two patients, the left perilesional areas may play an important role, as reported previously by Heiss et al.<sup>4</sup> and Warburton et al.<sup>5</sup>. Low-frequency rTMS applied to suppress the homologous areas of the most activated regions during a word repetition fMRI task, could hypothetically increase the neural activity in the left perilesional areas in the two patients, thus reducing the interhemispheric inhibition from the right hemisphere and facilitating functional reorganization in the left frontal lobe, resulting in improvement of impaired language function.

According to the results of the Copenhagen Stroke Study reported by Pedersen et al.<sup>6</sup>, the majority of post-stroke patients with aphasia achieve the best level of recovery by 10 weeks after onset of stroke. It seems that therapeutic intervention for

aphasia introduced during the plateau state rarely achieves beneficial effects on language functional recovery. However, our results suggest that long-term application of rTMS may improve language function in aphasic patients even when introduced after the patient have reached a plateau state of recovery. While the improvement seen in our patients could be viewed as natural recovery rather than the effect of rTMS, future studies of larger number of patients are required to confirm the efficacy of long-term rTMS. At this stage, we recommend the application of low-frequency rTMS treatment for more than several weeks, especially for patients with mild-moderate motor-dominant aphasia who are capable of visiting the clinic without any marked efforts. Whether our therapeutic rTMS application is clinically beneficial or not for patients with severe motor-dominant aphasia or sensory-dominant aphasia remains to be confirmed. The limitation of our study includes the lack of repeating fMRI with the same task at the end of the therapeutic protocol to determine the underlying mechanisms of improvement. The improved language function needs to be followed up after the cessation of outpatient treatment with rTMS to clarify the long-term effects of the treatment.

In conclusion, our proposed protocol of weekly rTMS application for 6 months after the in-patient rTMS course for aphasic post-stroke patients was successfully completed without any adverse effects, and resulted in improvement of naming and writing in both patients. Application of this therapeutic

approach in a larger number of patients is needed to confirm its beneficial effects on language functional recovery.

*Acknowledgements and Funding:* The funding for this study was provided by Grants-in-Aid for Scientific Research from the Japan Society for the Promotion of Science and The Uehara Memorial Foundation.

#### REFERENCES

1. Naeser MA, Martin PI, Nicholas M, Baker EH, Seekins H, Helm-Estabrooks N, et al. Improved naming after TMS treatments in a chronic, global aphasia patient-case report. *Neurocase* 2005; 11: 182-93.
2. Naeser MA, Martin PI, Nicholas M, Baker EH, Seekins H, Kobayashi M, et al. Improved picture naming in chronic aphasia after TMS to part of right Broca's area: An open-protocol study. *Brain Lang* 2005; 93: 95-105.
3. Wassermann EM. Risk and safety of repetitive transcranial magnetic stimulation: Report and suggested guidelines from the international workshop on the safety of repetitive transcranial magnetic stimulation, June 5-7, 1996. *Electroencephalogr Clin Neurophysiol* 1998; 108: 1-16.
4. Heiss WD, Kessler J, Thiel A, Ghaemi M, Karbe H. Differential capacity of left and right hemispheric areas for compensation of poststroke aphasia. *Ann Neurol* 1999; 45: 430-8.
5. Warburton E, Price CJ, Swinburn K, Wise RJ. Mechanisms of recovery from aphasia: evidence from positron emission tomography studies. *J Neurol Neurosurg Psychiatry* 1999; 66: 155-61.
6. Pedersen P, Jorgensen H, Nakayama H, Raaschou HO, Olsen TS. Aphasia in acute stroke: Incidence, determinants, and recovery. *Ann Neurol* 1995; 38: 659-66.